Library
National Institutes of Health
Bethesda 14, Maryland

TUMORS OF BONE AND CARTILAGE

Lauren V. Ackerman, M.D.
and
Harlan J. Spjut, M.D.

ARMED FORCES INSTITUTE OF PATHOLOGY

TUMORS OF BONE AND CARTILAGE

Lauren V. Ackerman, M.D.
and
Harlan J. Spjut, M.D.

ARMED FORCES INSTITUTE OF PATHOLOGY

ATLAS OF TUMOR PATHOLOGY

Section II—Fascicle 4

TUMORS OF BONE AND CARTILAGE

by

Lauren V. Ackerman, M.D.
Professor of Surgical Pathology and Pathology
Washington University School of Medicine, St. Louis, Mo.
Surgical Pathologist, Barnes Hospital and Affiliated Hospitals, St. Louis, Mo.
Consultant to the Armed Forces Institute of Pathology, Washington, D.C.

and

Harlan J. Spjut, M.D.
Associate Professor of Surgical Pathology
Washington University School of Medicine, St. Louis, Mo.
Associate Surgical Pathologist, Barnes Hospital and Affiliated Hospitals, St. Louis, Mo.

Published by the

ARMED FORCES INSTITUTE OF PATHOLOGY

Under the Auspices of the

SUBCOMMITTEE ON ONCOLOGY

of the

COMMITTEE ON PATHOLOGY

of the

DIVISION OF MEDICAL SCIENCES

of the

NATIONAL ACADEMY OF SCIENCES—NATIONAL RESEARCH COUNCIL

Washington, D. C.

1962

Accepted for Publication March 1961

For sale by the American Registry of Pathology
Armed Forces Institute of Pathology
Washington 25, D. C. - Price - $3.00

ATLAS OF TUMOR PATHOLOGY

Sponsored and Supported

by

AMERICAN CANCER SOCIETY

ANNA FULLER FUND

ARMED FORCES INSTITUTE OF PATHOLOGY

JANE COFFIN CHILDS MEMORIAL FUND FOR MEDICAL RESEARCH

NATIONAL CANCER INSTITUTE, U.S. PUBLIC HEALTH SERVICE

UNITED STATES VETERANS ADMINISTRATION

DEDICATION

This fascicle is dedicated to the memory of Milton Charles Winternitz. He was one of the originators of the concept of the Atlas of Tumor Pathology and a guiding spirit during its early formative years through his association with the Subcommittee on Oncology of the Committee on Pathology, Division of Medical Sciences, National Academy of Sciences—National Research Council.

ACKNOWLEDGMENTS

The authors would like to thank Professor E. Uehlinger, Director of the Pathologic Institute, University of Zurich, Switzerland, and Dr. Louis Lichtenstein, Senior Pathologist of the Veterans Administration Center, Los Angeles, California, for thoughtful and thorough criticisms of this fascicle. We would like to thank members of the Subcommittee on Oncology of the Committee on Pathology, National Academy of Sciences—National Research Council for reviewing the material.

We would like particularly to thank Dr. Catherine W. Blumberg for patient revision of the long manuscript. Dr. Lent C. Johnson has been extremely cooperative in helping us locate material at the Armed Forces Institute of Pathology. We would also like to thank Mr. Herman Van Cott, Chief, Medical Illustration Service, Armed Forces Institute of Pathology, Washington, D.C., and Mr. K. Cramer Lewis, Chief, Department of Illustration, Washington University School of Medicine, St. Louis, Missouri, for the excellent technical quality of the illustrations.

Illustrations for the fascicle have been difficult to obtain, and we wish to thank the many individuals in the United States and other countries who have contributed photographic materials and specimens:

Dr. R. C. Ahlvin, Dr. J. M. Burnett, and Dr. D. O. Burst, St. Louis, Mo.; Dr. R. W. Byrne, Milwaukee, Wis.; Dr. V. M. Carnes, Columbia, Mo.; Dr. J. H. Carter, Albany, N.Y.; Dr. M. B. Conrad, St. Louis, Mo.; Dr. D. C. Dahlin, Rochester, Minn.; Dr. E. K. Dawson, Edinburgh, Scotland; Dr. J. M. Dell, Gainesville, Fla.; Eastman Kodak Co., Rochester, N.Y.; Ellis Fischel State Cancer Hospital, Columbia, Mo.; Dr. Maurice Ernest, Moose Jaw, Saskatchewan, Canada; Dr. Robert Fienberg, Beverly, Mass.; Dr. L. J. Fox, St. Louis, Mo.; Dr. L. W. Gardner, Detroit, Mich.; Dr. I. F. Goidanich, Bologna, Italy; Dr. H. N. Hadders, Groningen, Holland; Dr. O. P. Hampton, Jr., St. Louis, Mo.; Dr. C. H. Hatcher, Palo Alto, Calif.; Dr. N. L. Higinbotham, Dr. H. L. Jaffe, and Dr. Marvin Kuschner, New York, N.Y.; Dr. J. F. Kuzma, Milwaukee, Wis.; Dr. Louis Lichtenstein, Los Angeles, Calif.; Dr. Å. Lindbom, Stockholm, Sweden; Dr. Leo Lowbeer, Tulsa, Okla.; Dr. A. E. Lubchenco, Denver, Colo.; Dr. R. A. Marcial, San Juan, Puerto Rico; Dr. I. H. Nelson, Tulsa, Okla.; Dr. R. W. Ogilvie, St. Louis, Mo.; Dr. E. E. Palik, Tulsa, Okla.; Dr. H. D. Palmer, Denver, Colo.; Dr. C. R. Phelps, Ottumwa, Iowa; Dr. J. L. Posch, Detroit, Mich.; Dr. A. J. Ramos, Manila, Philippine Islands; Dr. M. W. Rudicel, Kokomo, Ind.; Dr. R. F. Schaefer, St. Louis, Mo.; Dr. R. P. Shanewise, Spokane, Wash.; Dr. G. Söderberg, Stockholm, Sweden; Dr. F. W. Stewart, New York, N.Y.; Dr. R. P. Tamayo, Mexico, D.F.; Dr. R. S. Totten, Pittsburgh, Pa.; Dr. E. Uehlinger, Zurich, Switzerland; Dr. Earl Vandegrift, Pittsburgh, Pa.; and Dr. M. W. Wilson, Detroit, Mich.

Permission to use copyrighted illustrations and other material has been granted by:

American Cancer Society, Inc.:

Cancer:

10:72–88, 1957. For fascicle figures 157–160

10:1151–1152, 1957. For fascicle figure 193

Butterworth & Co., Ltd.:

Cancer, 1958. For fascicle figures 224 and 225

Charles C Thomas:

Bone Tumors, 1957. For fascicle figure 260

C. V. Mosby Co.:

Surgical Pathology, 1953. For fascicle figure 327

Franklin H. Martin Memorial Foundation:

Surg., Gynec. & Obst.:

50:216–233, 1930. For fascicle figures 4 and 5

86:465–472, 1948. For fascicle figure 42

Hospital for Joint Diseases:

Bull. Hosp. Joint Dis., 17:141–151, 1956. For fascicle figure 95

J. B. Lippincott Co.:

Ann. Surg.:

133:77–89, 1951. For fascicle figures 96 and 97

133:374–385, 1951. For fascicle figure 360

Journal of Bone & Joint Surgery, Inc.:

J. Bone & Joint Surg.:

36–A:732–744, 1954. For fascicle figures 124 and 125

38–A:797–808, 1956. For fascicle figures 316–318

40–A:465–468, 1958. For fascicle figure 256

L. Cappelli:

Chir. org. movim., 43:427–460, 1956. For fascicle figure 86

Oliver & Boyd, Ltd.:

J. Path. & Bact., 71:193–200, 1956. For fascicle figures 244 and 297

Radiological Society of North America, Inc.:

Radiology, 64:56–65, 1955. For fascicle figure 304

The Lancet, Ltd.:

Lancet, 2:51–57, 1956. For fascicle figures 137 and 138

Urban & Schwarzenberg:

Beitr. klin. Chir., 188:8–15, 1954. For fascicle figures 52–54

All illustrations are the authors unless otherwise acknowledged. The A.F.I.P. accession numbers are for the identification of negatives at the Armed Forces Institute of Pathology.

Lauren V. Ackerman
Harlan J. Spjut

TUMORS OF BONE AND CARTILAGE

TABLE OF CONTENTS

Page No.

INTRODUCTION 9
Classification of Tumors 10
Biopsy of Tumors 10
References 14
Figs. 1–3

TUMORS OF CARTILAGINOUS ORIGIN—PRIMARY BENIGN AND MALIGNANT 15
Chondroblastoma 15
Chondromyxoid Fibroma 17
Osteochondroma 19
Multiple Cartilaginous Exostoses 20
Enchondroma 20
Ollier's Disease 22
Chondrosarcoma 22
References 81
Figs. 4–80; Plates I and II–A, B

TUMORS OF OSTEOBLASTIC ORIGIN—PRIMARY BENIGN AND MALIGNANT 84
Osteoid Osteoma 84
Osteoblastoma 87
Osteosarcoma 89
Parosteal Sarcoma 91
Sarcoma Arising in Paget's Disease of Bone 92
Sarcoma Arising in Irradiated Bones 94
References 110
Figs. 81–160; Plate II–C, D

TUMORS OF MARROW ORIGIN—PRIMARY BENIGN AND MALIGNANT 152
Tumors Arising from Hematopoietic Elements 152
Plasma Cell Myeloma 152
Table I 153
"Pseudo-plasma Cell Myeloma" 155
Ewing's Sarcoma 156
Reticulum Cell Sarcoma 160

Page No.

TUMORS OF MARROW ORIGIN—PRIMARY BENIGN AND MALIGNANT—Continued
Tumors Arising from Fat Cells 163
Lipoma 163
Liposarcoma 164
References 164
Figs. 161–202; Plate II–E

TUMORS OF FIBROUS TISSUE ORIGIN—PRIMARY BENIGN AND MALIGNANT 198
Desmoplastic Fibroma 198
Fibrosarcoma 198
Tumors Arising from Fibrous Tissue (Uncertain) 201
Giant Cell Tumor 201
Table II 202
References 205
Figs. 203–241; Plates III, IV, and V–A, B

TUMORS OF VASCULAR ORIGIN—PRIMARY BENIGN AND MALIGNANT 233
Hemangioma 233
Glomus Tumors 234
Hemangiomas of Joints 234
Maffucci's Syndrome 235
Massive Osteolysis 235
Lymphangioma 235
Angiosarcoma 236
References 237
Figs. 242–255

TUMORS OF NEUROGENOUS ORIGIN—PRIMARY BENIGN AND MALIGNANT 247
Neurilemoma 247
Neurofibromatosis (von Recklinghausen) 247
Table III 248
Ganglioneuroma 248
References 249
Figs. 256–259

TUMORS OF ADAMANTINE ORIGIN (UNCERTAIN)—PROBABLY PRIMARY MALIGNANT 252
Adamantinoma 252
References 253
Figs. 260–270; Plate V–D

Page No.

TUMORS AND TUMOR-LIKE LESIONS SIMULATING PRIMARY TUMORS OF BONE 261
Invasive Tumors 261
Metastatic Tumors 261
Metastatic Carcinoma 262
Malignant Lymphomas and Leukemias 264
References 264
Cysts—Benign 265
Solitary Unicameral Bone Cyst 265
Aneurysmal Bone Cyst 267
References 270
Tumor-like Lesions of Fibrous Tissue Origin—Benign 270
Fibrous Dysplasia 270
Metaphysial Fibrous Defect 273
Table IV 273
Periosteal Desmoid 274
References 275
Miscellaneous Lesions—Benign 275
Pigmented Villonodular Synovitis 275
Pigmented Villous Synovitis 277
Synovial Osteochondromatosis 277
Myositis Ossificans 279
Eosinophilic Granuloma 281
Giant Cell Reaction 282
Giant Cell Tumor—Tendon Sheath Origin 282
References 283
Figs. 271–362

TUMORS OF BONE AND CARTILAGE

INTRODUCTION

The diagnosis of certain neoplasms of bone is difficult for the pathologist. The difficulty may stem from several sources: since neoplasms of bone are rare, opportunities for diagnoses may be limited to a few cases unless the pathologist is an authority in the field or is associated with a specialized institution; many biopsies of bone tumors submitted for study are inadequate; and histologic preparation of bone is difficult.

At present it is not well recognized that accuracy of diagnosis of a bone tumor will be achieved only by close cooperation of the pathologist with a clinician and a radiologist; the pathologist consults the clinician to appraise the clinical data concerning the case and the radiologist to review the corresponding roentgenograms. The pathologist also must determine that tissue to be studied is representative of the pathologic process involved and has been well prepared technically. Incorrect diagnosis could result from failure to observe these simple rules. For instance, due to poor selection of tissue blocks, poor preparation of material, and inadequate knowledge of bone pathology, some of the material referred to us has had accompanying erroneous diagnoses of malignant neoplasms. This material was from cases of metaphysial fibrous defect, healing fracture, fibrous dysplasia, osteoid osteoma, chondroblastoma, and chondromyxoid fibroma.

Decision often must be made whether to amputate an extremity or do a hemipelvectomy because of a bone tumor. Since this decision is particularly serious in a young patient, careful preoperative review of the gross and microscopic pathology of the tumor is of paramount importance. It is imperative that a benign lesion not be misinterpreted to result in amputation of a limb, particularly when the cure rate for certain malignant tumors is low.

The usual benign and malignant neoplasms of bone have been included in this fascicle. Well documented rare bone tumors also have been included, but poorly documented rare neoplasms and those defying efforts of classification have deliberately been excluded. We have included short discussions on those non-neoplastic lesions in and around bones which must be considered in differential diagnoses of bone neoplasms. Roentgenograms have been included as integral parts of diagnoses to show patterns of tumors, locations of tumors in bones (such as epiphysis, metaphysis, and diaphysis), and the specific bones involved.

CLASSIFICATION OF TUMORS

Classification of bone tumors can be complicated or simple. Although a simple classification is presented here, we grant that bone is dynamic rather than static; obviously, therefore, one entity might merge with another (Johnson). Sissons states (p. 324), "On a practical level, however, histological identification based on tissue differentiation is adopted because it allows a useful degree of prediction of the properties and behaviour of the tumours concerned." In agreement, we believe that for purposes of diagnosis and treatment most bone neoplasms fall into a predicable and classifiable group.

BIOPSY OF TUMORS

Biopsy is considered by us as an essential component of diagnostic clarification of lesions suspected of being bone tumors. Even though vigorous discussions regarding dangers of the procedure and possible spread of the tumor still prevail, we feel that biopsy should be done on most lesions to determine whether they are benign or malignant before definitive therapy is decided (fig. 1). In fact, it can even become definitive therapy in lesions such as osteoid osteoma. Except for local implantation of tumor, we know of no objective evidence that biopsy increases incidence or probability of metastases from malignant tumors of bone. Although radiation therapy of tumors of bone prior to biopsy has been suggested as a means of reducing the possibility of metastases, we have had no experience with its use.

Definitive incisional biopsy should be performed by an experienced orthopedic surgeon, in our opinion, for we have seen innumerable instances in which bone lesions have been biopsied inadequately. This procedure has invariably complicated future treatment of patients, because a second biopsy is understandably more difficult to obtain and interpret. Therefore after the clinician and radiologist have identified the bone lesion, the case should be referred to the orthopedic surgeon and pathologist for diagnosis. Since Ewing's tumor and eosinophilic granuloma often have similar radiographic findings, cases such as these can be offered as good examples of the necessity for establishing an unquestionable differential diagnosis through joint efforts of the clinician and pathologist. Only when definitive diagnosis has been made can corrective therapy, including amputation if necessary, be administered.

Cases involving large cartilaginous tumors in and around the pelvis are the only ones on which we would not necessarily advise incisional biopsy, since incision of the peripheral portion of some of these tumors may involve contamination of the entire operative field and thereby increase the magnitude of a contemplated operative procedure (see section on Chondrosarcoma).

Sections of bone can be obtained from drill biopsy, and needle biopsy can be done on soft tissue extensions of bone tumors. The latter has been our method of diagnosis on several occasions, but not to as great an extent as that

CLASSIFICATION OF PRIMARY BENIGN AND MALIGNANT NEOPLASMS

ORIGIN	BENIGN NEOPLASM	MALIGNANT COUNTERPART
CARTILAGE	Chondroblastoma Chondromyxoid Fibroma Osteochondroma Enchondroma	Chondrosarcoma Primary Secondary
BONE	Osteoid Osteoma Osteoblastoma	Osteosarcoma Parosteal Sarcoma Sarcoma arising in: Paget's Disease Irradiated Bones
MARROW ELEMENTS Hematopoietic Elements		Plasma Cell Myeloma "Pseudo-plasma Cell Myeloma" Ewing's Sarcoma Reticulum Cell Sarcoma
Fat Cells	Lipoma	Liposarcoma
FIBROUS CONNECTIVE TISSUE	Desmoplastic Fibroma	Fibrosarcoma
(Uncertain)	Giant Cell Tumor	Giant Cell Tumor
VASCULAR Blood Vessels	Hemangioma Glomus Tumor Hemangioma of Joints	Angiosarcoma
Lymph Vessels	Lymphangioma	
NEUROGENOUS	Neurilemoma Neurofibromatosis Ganglioneuroma	
ADAMANTINE (Uncertain)		Adamantinoma

BIOPSY

Figure 1. Roentgenogram of a forearm of a 15-year-old boy. Injury had been sustained to this site two months previously. Because of periosteal bone proliferation and soft tissue mass, the lesion had been considered malignant. However, biopsy proved it benign, with subperiosteal hemorrhage and bone formation. It regressed after two years without benefit of therapy. W.U.* 52–3415; A.F.I.P. Acc. No. 218757–340.

Figure 2. Photomicrograph of a section from a needle biopsy of a giant cell tumor. The tumor had occurred in the distal epiphysial portion of the femur of a 25-year-old woman who had had pain in the knee for nine months. Hematoxylin and eosin stain. X 600. W.U. 58–5019; A.F.I.P. Acc. No. 218757–341.

Figure 3. Histologic section of a field from a needle biopsy of a lytic lesion of the right ilium. It shows a poorly differentiated epidermoid carcinoma metastatic from the uterine cervix of a 46-year-old woman. Hematoxylin and eosin stain. X 310. W.U. 58–6382; A.F.I.P. Acc. No. 218757–342.

*In this and following legends, W.U. stands for Washington University, St. Louis, Mo.

Fig. 1

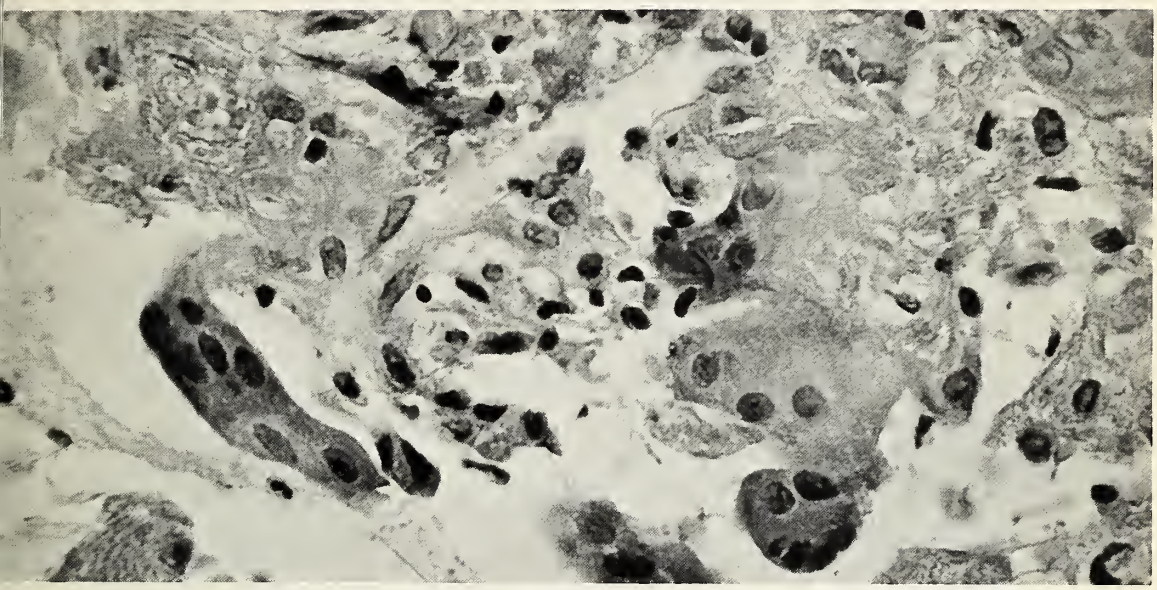

Fig. 2

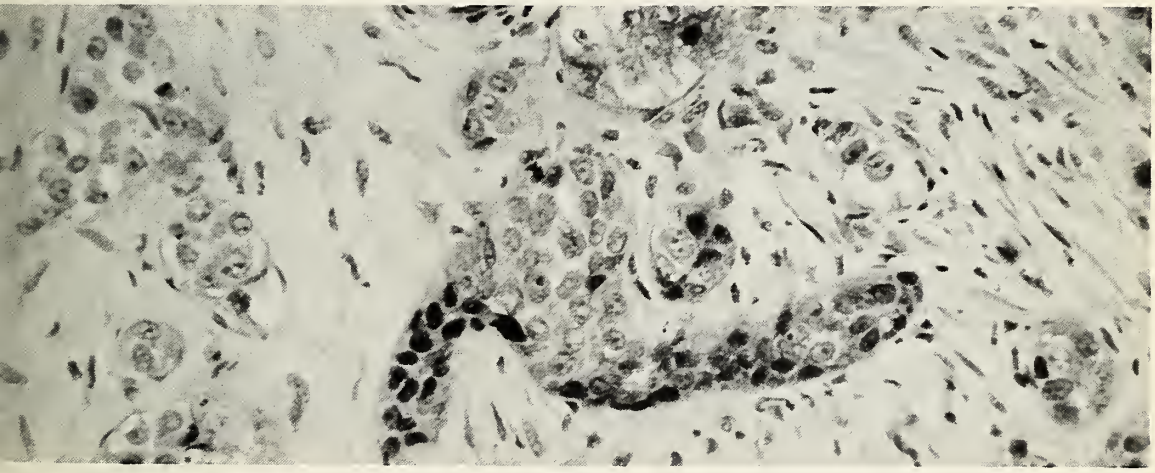

Fig. 3

reported by Ottolenghi and by Schajowicz. While some lesions can be diagnosed readily by this method, diagnosis of others may be difficult (figs. 2, 3).

Needle biopsy of joints, particularly the knee, also offers a means for studying joint lesions. Its greatest importance is assumed in delineation of non-neoplastic joint diseases (Polley and Bickel; Zevely et al.).

Any biopsy may result in local implantation of tumor in soft tissues (Thompson and Steggall). If the biopsied area can be re-excised at the time of definitive surgery, however, this risk is no longer of clinical importance. Even if tumor has extended into soft tissues, there should be no hesitancy in doing frozen sections. When definitive diagnosis can be made through this medium, we are in agreement with Coventry and Dahlin that treatment should be done without delay, even amputation. In those instances in which definitive diagnosis may not be possible, frozen section at least can insure adequate material for diagnosis.

References

Coventry, M. B., and Dahlin, D. C. Osteogenic sarcoma. A critical analysis of 430 cases. J. Bone & Joint Surg., 39–A:74–758, 1957.

Johnson, L. C. A general theory of bone tumors. Bull. New York Acad. Med., 29:164–171, 1953.

Liebegott, G. Die Morphologie der primären Knochengeschwülste. Verh. Deut. Orthopäd. Ges., 47:101–132, 1960.

Ottolenghi, C. E. Diagnosis of orthopaedic lesions by aspiration biopsy. Results of 1,061 punctures. J. Bone & Joint Surg., 37–A:443–464, 1955.

Polley, H. F., and Bickel, W. H. Experiences with an instrument for punch biopsy of synovial membrane. Proc. Staff. Meet., Mayo Clin., 26:273–281, 1951.

Schajowicz, F. Aspiration biopsy in bone lesions. Cytological and histological techniques. J. Bone & Joint Surg., 37–A:465–471, 1955.

Sissons, H. A. Malignant Tumours of Bone and Cartilage. In: Raven, R. W. (ed.). Cancer, pp. 324–349. Vol. II. London: Butterworth & Co., Ltd., 1958.

Thompson, V. P., and Steggall, C. T. Chondrosarcoma of the proximal portion of the femur treated by resection and bone replacement. A six-year result. J. Bone & Joint Surg., 38–A:357–367, 1956.

Uehlinger, E. Die pathologische Anatomie der Knochengeschwülste. Helvet. chir. acta, 26:597–620, 1956.

Zevely, H. A., French, A. J., Mikkelsen, W. M., and Duff, I. F. Synovial specimens obtained by knee joint punch biopsy. Histologic study in joint diseases. Am. J. Med., 20:510–519, 1956.

TUMORS OF CARTILAGINOUS ORIGIN—PRIMARY BENIGN AND MALIGNANT

Chondroblastoma

SYNONYMS AND RELATED TERMS: Calcified giant cell tumor; chondromatous osteoclastoma; Codman's tumor; epiphysial chondroblastoma; epiphysial chondromatous giant cell tumor.

DEFINITION. A neoplasm of bone of cartilaginous origin, the basic cell of which is capable of producing a chondroid matrix.

NATURAL HISTORY. Chondroblastoma is a descriptive term introduced in 1942 by Jaffe and Lichtenstein. Clinical and histologic features of this neoplasm probably were interpreted as variants of giant cell tumor (Ewing; Codman) prior to that date, chiefly because multinucleated giant cells were often abundant.

INCIDENCE. Chondroblastoma is a rare tumor. It comprised less than 1 percent of 2,000 or more tumors of bone studied at Mayo Clinic (Dahlin, 1957). In 1956 Kunkel and associates tabulated 59 cases; 16 of these were their own, but the 9 cases of Codman were not included. We reviewed an additional 20 cases of chondroblastoma at the Armed Forces Institute of Pathology and Barnes Hospital; these, with the 7 cases reported by Hadders and associates, the single cases noted by Denko and Krauel and by Oppenheim and Boal, and the one sent to us by Uehlinger, total approximately 100 cases of chondroblastomas.

This tumor is more common in men than in women. The majority of tumors are seen in patients in the second decade, but a few are seen in the first or after the sixth decades.

CLINICAL DATA. Symptoms and physical findings are not diagnostic, although the former may have been endured for months or years. Swelling and pain are usually present at the site of the lesion, but frequently complaints of stiffness and limitation of motion are directed to the adjacent joint. The presence of three pathologic fractures was reported by Copeland and Geschickter; however, it was not stated whether these occurred in association with benign or "malignant" tumors.

Although the roentgenogram may suggest chondroblastoma (Plum and Pugh), biopsy is the definitive means for making the diagnosis.

PATHOGENESIS. The pathogenesis is not known. Conjecturally it has been suggested that chondroblastoma has its origin in a focus of misplaced or abnormally proliferating epiphysial cartilage cells which, for reasons unknown, transform into a chondroblastoma. This suggestion is based on resemblance of the basic cell of the tumor to a chondroblast and chondroid tissue. Another theory has been proposed by Valls and associates. Through their use of silver

stains on sections of chondroblastoma, reticulin fibers surrounding individual cells and groups of cells were demonstrated. From this it was surmised that the tumor has its origin in reticulohistiocytes or related cells. A morphologic relationship to chondromyxoid fibroma has been described by Dahlin (1956).

SITES OF TUMOR. Chondroblastomas almost invariably arise in epiphysial regions of bones. However, Dahlin (1957) stated that rare examples also have been seen in metaphyses, with only minor epiphysial components. While confinement to epiphysial areas is usual, the tumor may invade the metaphysis, erode articular cartilage, or actually perforate joint spaces (Dahlin, 1957; Lichtenstein).

Reports of numbers of bones involved by the tumors have increased since the initial reports of Codman and of Jaffe and Lichtenstein (1942). From 100 cases, these sites of distribution can be summarized as follows: femur 35 (proximal portion 11, distal portion 21, not localized 3), humerus 29 (proximal portion 27, not localized 2), tibia 15 (proximal portion 13, distal portion 2), innominate bone 4, talus and scapula each 3, fibula and calcaneus each 2, and temporal, radius, metacarpal, rib, thoracic vertebra, sacroiliac and metatarsal, each 1.

GROSS. From specimens studied intact, chondroblastomas were usually seen as sharply demarcated, ovoid to round, lobulated, firm, sometimes resilient lesions (figs. 4–7). They varied in size from 1.5 cm. to 6 cm. or more in diameter, and in color from blue-gray to gray-yellow to gray-brown. Cut surfaces were gritty because of cartilage and scattered deposits of calcium, but bone was an uncommon component. Hemorrhagic areas and small cysts were seen. These cysts were usually less than 1 cm. in diameter and tended to be peripherally located in the lesion (Jaffe and Lichtenstein, 1942).

One chondroblastoma examined was predominantly a cyst, with tumor presenting as a gritty mass at one pole (Oppenheim and Boal). However, this gross pattern is rare.

Bone surrounding the tumor may be slightly sclerotic. Occasionally the chondroid matrix is sufficiently abundant to impart an appearance similar to that of chondroma or chondrosarcoma (see section on Chondrosarcoma).

MICROSCOPIC. Cells considered as chondroblasts give chondroblastoma its distinctiveness. These cells are usually polygonal or rounded with oval or round nuclei, but in more cellular areas, a spindle contour (figs. 8, 9) may prevail; nucleoli are common. Although not difficult to find, mitotic figures are not numerous. A clearly defined cell membrane for some of these cells is an aid to diagnosis of the tumor. Since the cell pattern is varied (figs. 12, 13), cell membranes are not viewed in every microscopic field. When a chondroid substance is present in cellular areas, it forms the stroma. Foci of possible transitions from the cellular areas into cartilage are present. Multinucleated giant cells are common, but not as numerous as in giant cell tumors.

Jaffe and Lichtenstein (1942) have described two types of giant cells: (1) a small multinucleated giant cell associated with the tumor components, and

(2) a larger multinucleated giant cell seen in areas of hemorrhage and vascular sinuses. The former they consider as tumor giant cells, the latter as multinucleated macrophages. It is from areas of large multinucleated giant cells that a mistaken diagnosis of giant cell tumor may be made (figs. 10, 11). Unfortunately, too, the presence of fibrous stroma and vascularity also tends to support this confusion in diagnosis.

Outstanding histologic support for diagnosis of chondroblastoma is spotty calcification (fig. 9). Its presence is practically invariable. Calcific deposits are noted within and between the cells of the cellular areas of the tumor. Jaffe and Lichtenstein (1942) suggest that this calcification is primary and that accompanying necrosis of tumor is secondary to it. Following necrosis there is repair of tissue, with transformation to hyaline or chondroid tissues, or occasionally to osteoid.

TREATMENT. Since the lesion is benign, treatment is conservative. Curettage, or local excision when deemed appropriate, is sufficient for successful treatment of chondroblastoma. Prolonged follow-up confirms this approach. Radiation therapy combined with curettage also has proved successful, although the role of radiation is difficult to evaluate when combined treatment is used. A few cases treated by radiation therapy following biopsy have been reported in which results have been good (Kunkel et al.; Valls et al.).

DIFFERENTIAL DIAGNOSIS. It is particularly important to recognize the distinction between chondroblastoma and giant cell tumor. Chondroblastoma is so rarely a malignant neoplasm that it is usually curable by conservative measures; we recently have viewed our first metastasizing chondroblastoma. Giant cell tumors in representative numbers behave as malignant neoplasms.

Cellular areas of the tumor, cartilage formation, necrosis, and mitotic figures probably account for the incorrect interpretation of chondroblastoma as either an osteosarcoma or chondrosarcoma.

Chondromyxoid Fibroma

SYNONYMS AND RELATED TERMS: Embryonal enchondroma; myxoma.

DEFINITION. A benign localized lesion with chondromatous and myxoid characteristics. ". . . a peculiarly differentiated connective tissue tumor exhibiting in the course of its evolution certain chondroid and also myxoid traits . . ." (p. 550, Jaffe and Lichtenstein, 1948).

CLINICAL DATA. Although etiology of chondromyxoid fibroma remains unknown, the tumor occurs predominantly in young adults. There is no sex predilection. The lesion has been encountered in the rib, ulna, phalanx, vertebra, pelvis, femur, tibia, fibula, calcaneus, tarsal, and metatarsal bones. Most patients complain of pain in the area of the tumor and have had awareness of a mass for months.

Roentgenologically, the tumor can be accurately localized. In long bones of the lower extremities it is most frequently located eccentrically in the metaphysis (figs. 14, 15), primarily near or contiguous to the epiphysis (Dahlin, 1956). Because of sharp outline, the tumor can be diagnosed as benign; unfortunately, often it is incorrectly interpreted as an aneurysmal bone cyst (figs. 16–18, 24–26), from which differentiation may be extremely difficult. Although the tumor is benign as far as is known, if inadequately removed, it may recur locally and occasionally may be implanted in the soft tissues.

GROSS. Although this tumor is cartilaginous in texture, it lacks the sliminess expected of a myxoid element. Variations in size from 1.5 cm. to 8 cm. in diameter have been reported (figs. 19, 20).

In curetted specimens, fragments of tumor are similar in appearance to cartilage. Totally removed specimens are well circumscribed, lobulated in contour, solid, firm but resilient, and white to gray-white to tan. Tumor is noted to replace bone and seems to prompt sclerosis of surrounding bone (figs. 21, 22). The cortex may be eroded by expansion of the tumor, with periosteum serving as a limiting membrane.

MICROSCOPIC. A broad spectrum of histologic features is seen in this neoplasm (fig. 27), with myxomatous zones seemingly predominant. Because of its mixed components, chondromyxoid fibroma has been confused histologically with chondrosarcoma and myxosarcoma. Thus, recognition of this relatively uncommon lesion, histologically as well as clinically, is of importance to the patient.

Microscopic fields of chondroid material, which are present in every tumor, either may be difficult to find or may predominate. The lobular pattern observed in the gross specimen is maintained by thin fibrous bands containing blood vessels. Multinucleated giant cells, macrophages, mononuclear leukocytes, hemosiderin pigment, and focal calcification are also observed microscopically. However, focal calcification with ossification is unusual.

Cells forming the myxomatous areas may be extremely bizarre. Nuclei vary from ovoid to round to polygonal (figs. 22, 23, 28–31); many have elongated fibrillar processes. The matrix is bluish when stained with hematoxylin and eosin, but does not give a positive response with mucicarmine stain. In more mature lesions, collagen fibers become numerous in lobules and may result in hyaline foci (Jaffe and Lichtenstein, 1948). Dahlin (1956) believes that increased concentration of nuclei at the periphery of lobules is of "extreme importance" in identification of this neoplasm. These cellular areas, bizarre cells in myxomatous lobules, and chondromatous zones previously have led to diagnoses of malignant tumors of bone—usually chondrosarcoma. For instance, the four cases of Dahlin (1956) and two cases of Jaffe and Lichtenstein (1948) were diagnosed as malignant tumors prior to identification of this entity.

TREATMENT. Although curettage may be a successful therapeutic measure, ideal therapy when possible would be sufficiently wide excision of the

tumor to include a rim of normal bone. Radiotherapy has not been evaluated. In one case involving the vertebrae, radiation provided temporary relief from cord compression, with some remodeling of the bone 15 months after therapy.

Osteochondroma

SYNONYMS AND RELATED TERMS: Ecchondroma; osteocartilaginous exostosis.

DEFINITION. A cartilage-capped bony projection arising in the metaphysial area from the cortical surface of bones.

INCIDENCE. Osteochondromas are the commonest benign neoplasms of bone. They occur in any bone developing by endochondral ossification, and arise most frequently in the distal metaphysial region of a femur and the proximal metaphysial region of a tibia (figs. 33, 34). Of 40 consecutive cases studied by us, 38 were found in these long bones of the extremities. In the series of 272 cases of Dahlin (1957), over one-half occurred in lower extremities, 48 in upper portions of humeri, 22 in scapulae (pl. II–A, B), and 26 in pelves. Only 9 occurred in ribs and 8 in vertebrae and sacra.

About 80 percent of patients with these tumors are under 21 years of age.

GROSS. Average diameter of the osteochondromas of our cases was 3.7 cm.; however, one tumor of a lower femur measured 8.5 cm. Tumors even may be larger.

Periosteum from adjacent bone reflects over the surface of the tumor, and it may become thickened. In children and young adults, the surface of the tumor is usually rather smooth. In older individuals who have had tumors for longer periods of time, however, there is greater irregularity of the surface.

On cross section of an osteochondroma, a cartilaginous cap is noted which varies in thickness from about 0.1 to 3 cm. Average thickness in our cases was 0.6 cm. Thickness of the cartilaginous cap is important in judging whether the lesion is benign or malignant.

Bursae may develop over an osteocartilaginous exostosis, particularly in large osteochondromas which impinge on muscles and tendons. These bursae attach around the base of the exostosis; their lining is like synovium, and may contain calcified chondral bodies (Lichtenstein).

MICROSCOPIC. Cartilage of the cap may be relatively acellular or there may be focal zones of increased cellularity (figs. 32, 35–37), particularly in growing osteochondromas of young children. In patients 40 years of age or over, there is often marked irregularity of the cartilaginous cap; it may be completely missing in some zones. Periosteum abuts directly on bone, and as the cap merges with the bone there is enchondral ossification (fig. 36).

TREATMENT. In children and adolescents, osteochondromas usually are not removed unless symptoms are being produced by them, such as those from pressure on nerves or muscles. Since malignant changes occur in less than 1 percent of osteochondromas, there is no reason to remove asymptomatic tumors.

Multiple cartilaginous exostoses, or abnormal osteocartilaginous outgrowths, are rare. About 65 percent of patients with these tumors give histories of similar lesions having occurred in relatives (Hunter and Wiles). At times, then, this hereditary condition has also been termed: diaphysial aclasis; dyschondroplasia; hereditary deforming chondrodysplasia; and hereditary or multiple exostoses.

Characteristic deformities of the forearm were present in 11 cases of this entity reported by Jaffe (1943). In these, the ulna was shortened or deformed by exostoses in its distal portion, and the radius was bowed away from this bone, with outward and posterior dislocation of its head (figs. 38–40). Patients with these lesions have increased possibilities of developing chondrosarcoma; it had developed in three of the cases of Jaffe. This complication usually appears in adults, and rarely is seen in children (Bennett and Berkheimer).

Many pathologists believe that both solitary and multiple exostoses have their origin in perverted activity of the periosteum which forms anomalous foci of metaplastic cartilage. This supposition is difficult to prove. Keith believes that this condition should be termed diaphysial aclasis, because the chief disturbance lies in modeling or pruning of the diaphyses, or shafts, of bone (fig. 38).

Multiple exostoses most commonly present in metaphysial areas of the shoulder, knee, or ankle bones (Jaffe, 1943). The first area apparently involved is often the vertebral margin of a scapula (pl. II–A, B). Extensive involvement encompasses juxta-epiphysial regions of metacarpal and metatarsal bones and also the phalanges, ribs, vertebrae, and innominate bones. In the ilium, exostoses are most numerous and prominent on both anterior and posterior surfaces along the line of attachment of the epiphysis of the crest. The skull is not involved.

Appearance of multiple exostoses is similar to that of single lesions. For instance, the cartilaginous caps tend to diminish in thickness with age, similarly to those of single lesions. Beneath the cartilage is a thin plate of bone under which lies spongy bone with delicate trabeculae chiefly supporting a fatty marrow.

Any of these benign lesions which cause pain or pressure phenomenon should be excised. Tumors showing increase in growth after puberty should be removed by block excision because of the possibility that they have become malignant (fig. 41).

Enchondroma

SYNONYMS AND RELATED TERMS: Chondroma.

DEFINITION. A benign neoplasm of cartilage arising within the medullary cavity of a bone.

INCIDENCE. Enchondromas occur with equal frequency in men and women. Most patients affected are between the ages of 10 and 30 years.

SITES OF TUMOR. Small bones of hands and feet are commonest locations of these tumors. When occurring in hands, they are often multiple and may be deforming (figs. 42, 43, 45). In the cases of Jaffe (1956), 14 were located in phalanges, 6 in metacarpals and metatarsals. The 99 cases of enchondromas reported by Dahlin (1957), however, were located as follows: 56 in hands; 12 in femora; 6 in humeri; 4 each in vertebrae and feet; 3 each in ribs, scapulae, and innominates; 2 each in skull and tarsals; and 1 each in carpals, patellae, fibulae, and tibiae. The relatively small numbers of cases of enchondromas situated in long bones should be noted. Generally, enchondromas of long bones are rare (fig. 46); we have seen only three such cases in Barnes Hospital. In fact, we feel that any intramedullary cartilaginous tumor of a long bone is suspect of being malignant until proved otherwise.

GROSS. Such lesions are rarely seen as gross specimens unless a digit of a hand or foot has been amputated to remove a large deforming enchondroma. The lesions are well delimited and form lobules which thin and distend the cortex but do not rupture it. If a cartilaginous tumor has grown through cortical bone into soft tissue or has grown within a rib or a long bone, however, it is probably malignant.

MICROSCOPIC. Specimens usually consist only of curetted material, since curettement in small bones is invariably curative, without evidence of recurrence. This material has the glistening and gray gross appearance of cartilage, and may contain foci of calcification. These benign cartilaginous tumors within bone have uniform nuclei without aberrations or mitotic activity. Most cartilage cells have a single small nucleus. If the cells are binucleated, nuclei will still be small. Cytoplasm is pale, with indistinct outlines, and is often vacuolated. At times, cartilage cells are not surrounded by lacunae, and their cytoplasm is multipolar or stellate. However, we must admit that some tumors of small bones of the hands and feet may show nuclear atypia (figs. 44, 47, 48). Chondrosarcoma of such small bones is rare, however.

We have seen lesions within long bones in which it had been stated that the lesion was benign at first and then had become malignant. Review of sections of these tumors demonstrated that the lesion had been malignant at the time of first biopsy, but diagnosis was missed microscopically at that time.

ASSOCIATED LESIONS. There is a form of enchondroma, called juxtacortical chondroma by Jaffe and periosteal chondroma by Lichtenstein, which occurs in long bones, such as tibia and humerus, as well as in small bones (Jaffe, 1956). It develops beneath the periosteal connective tissue and erodes underlying cortical bone; margins of the cortical bone are sclerotized. The tumor is a circumscribed, lobulated growth and has the microscopic pattern of a benign cartilaginous lesion.

Another lesion, described as an enchondroma, is calcifying enchondroma (Laurence and Franklin). This lesion is heavily calcified and occurs in long

bones. Radiographically, the involved bone is unaltered except for presence of the densely calcified lesion.

Coley and Higinbotham (1949) have felt that many chondrosarcomas are derived from pre-existing cartilaginous lesions. This impression is difficult to contradict, especially if radiographs demonstrate that a lesion has been present in bone for a long period and then begins to undergo alterations; it is obviously impossible to study histologic sections of the tumor early in the course of its development. In the 13 cases reported by Coley and Higinbotham (1949), 7 had been apparently incorrectly diagnosed microscopically. While 6 had had longer histories, 4 of these had had a history for only two years or less; the latter time lapse was compatible with the natural life history for chondrosarcoma. Therefore, there were only 2 cases, one of 10 years' and one of 30 years' duration, in which there was any possibility that the chondrosarcoma had risen from a pre-existing enchondroma.

Ollier's disease is a rare developmental abnormality, with rounded masses or clumps of unossified cartilage in the metaphysis and diaphysis of certain bones (Fairbank, 1948). This developmental error was first described by Ollier as dyschondroplasia. Unlike multiple cartilaginous exostoses, no hereditary or familial influence exists for this disease.

The region of the knee joint and distal portions of the radius and ulna are the commonest sites of Ollier's disease; the humerus, femur, tibia, and fibula also may be involved (figs. 50, 51). However, the skull, ribs, sternum, spine, carpal and tarsal bones, and the region of the elbow joint escape the process.

The disease predominantly is only on one side of the body; if the phalanges are involved, however, there frequently are a few enchondromas on the opposite hand, particularly on the 1st and 5th digits.

The gross lesion has not been seen by us, but it is well illustrated clinically by Tiwisina (figs. 52–54). It is essentially endosteal and does not project on the surfaces as do exostoses (Fairbank, 1948). Microscopically, the lesion consists of unossified cartilage (fig. 49).

Since bones are often shortened, extensive orthopedic procedures must be undertaken over a long period of time to correct these deformities. On a few occasions, chondrosarcoma has been reported in association with this entity, and treatment would vary accordingly (Tiwisina).

Chondrosarcoma

SYNONYMS AND RELATED TERMS: Chondroblasticsarcoma; chondromyxosarcoma; osteochondrosarcoma; osteogenic sarcoma.

DEFINITION. A tumor arising from cartilage de novo or superimposed on a pre-existing benign cartilaginous process.

Arising de novo, it may be designated as primary chondrosarcoma; arising from a pre-existing benign cartilaginous tumor, it is called secondary chondrosarcoma.

PATHOGENESIS. Dahlin (1957) reported 218 chondrosarcomas; of these, 199 were primary and 19 were secondary. Sixty percent of the primary tumors arose most commonly from bones of the pelvis (48 cases), rib cages (46 cases), and proximal portions of femora (25 cases). The majority of the remaining group originated in distal portions of femora, proximal and distal portions of tibiae, sterna, proximal portions of humeri, and vertebrae.

Although chondrosarcomas arise rarely from small bones of hands or feet, Lansche and Spjut collected 9 cases of these tumors of small bones of the hands; it is interesting that 6 of these 9 cases came from the phalanges (pl. I–A; fig. 78). Even more rarely a chondrosarcoma can occur in the maxilla, mandible, nasal septum, various cartilages of the larynx, or as a primary malignant tumor of soft tissue (Stout and Verner).

Our experience that a high percentage of chondrosarcomas arise de novo corresponds with that of Dahlin (1957); in most instances we are unable to trace development of a malignant cartilaginous tumor from a pre-existing benign chondroma. For instance, cartilaginous tumors within long bones are viewed with great respect; in a high percentage of cases we have no evidence from gross or microscopic examinations of the specimens that these tumors arose from pre-existing benign neoplasms.

Chondrosarcomas can arise from osteochondromas of long duration, multiple cartilaginous exostoses, and Ollier's disease. In all three of these conditions, patients often can be shown to have had lesions for many years. A typical history is that at the time of puberty or later, one of the lesions may have begun to grow and be associated with pain. Gross and microscopic examinations of the tumor gave evidence suggestive of a pre-existing benign process. However, often the chondrosarcoma blotted out any evidence of a pre-existing benign neoplasm. Therefore, any inferences by us on origin of chondrosarcoma from pre-existing benign cartilaginous neoplasms must be based on clinical history and review of roentgenograms. We have seen in our material no example of a chondrosarcoma arising from a pre-existing enchondroma which could be proved pathologically; the experience of Dahlin has been similar (see section on Enchondroma).

GROSS. Appearance of the lesion is typical; it should be divided into (1) those arising centrally and (2) those arising peripherally:

(1) In a bone such as the femur, for instance, a centrally located cartilaginous tumor could cause expansion within the medullary cavity, with occasional patchy thickening of the cortex and formation of reactive bone (figs. 64, 65). Even though these tumors have well defined borders, they eventually cause destruction of the cortex and extend into the surrounding soft tissue. This process gives evidence that the cartilaginous tumor is malignant.

Frequently these tumors become large, and when large, they show cystic areas most prominently; within the cystic areas mucoid material is present (figs. 57, 58). In fact, we have seen extensive cystic changes due to mucoid

degeneration of the cartilaginous matrix (Thompson and Steggall). Flecks of calcium are also present within the neoplasm.

In a rib, chondrosarcoma most frequently arises at the costochondral junction, although it may arise in any location. It forms an expansile mass which destroys cortical bone; it may involve several ribs (figs. 57, 58), extend into the pleural cavity, or even grow deeply into the breast to cause an ulcerating skin mass. A cut through the tumor demonstrates glistening nodules with foci of calcification and mucoid cystic zones (figs. 58, 61, 63).

In the region of the pelvis, these tumors grow even larger; they may involve the entire wing of the ilium (figs. 55, 56), growing inwardly within the pelvis to form a bosselated mass and outwardly to form a huge mass beneath the tense skin (fig. 66). We observed a case in which tumor finally had so destroyed the bladder wall that biopsy of it was obtained through the cystoscope.

(2) In peripheral expressions of this neoplasm, the tumor apparently may arise from a pre-existing cartilaginous exostosis. Therefore, it may be attached to the distal portion of a femur by the broad base of the pre-existing osteochondroma (figs. 59, 60). The cartilaginous cap will be thickened and irregular and invariably 3 cm. or more in width. Such lesions frequently form in the region of the pelvis and have similar characteristics. Clinical evidence of change to chondrosarcoma in a peripheral osteochondroma is indicated by sudden, rapid growth. Usually this occurs after puberty. In the series of Dahlin (1957), 19 secondary tumors arose in pre-existing osteochondromas; 12 of the 19 occurred in patients who had multiple cartilaginous exostoses.

Chondrosarcoma grows slowly, extending locally through pathways of least resistance; occasionally local extension of the tumor may dominate the clinical pattern (fig. 77). For instance, we have seen a huge tumor of the thigh in which, radiographically, there was little evidence of change in the femur; at the time of amputation, however, the tumor was seen to have arisen from the femur and to have grown outward to form the huge mass in the thigh.

These tumors, besides invading the pelvis and growing diffusely in the region of the chest, also have the capacity to invade veins. Propagation of the tumor along veins has been reported. Cases also have been reported in which tumor arose in the region of a thigh, grew into the femoral vein, formed a continuous thrombus into the heart, and extended out the right pulmonary artery into the lung parenchyma.

In contrast, metastases to regional lymph nodes are extremely rare; we have seen only one example of metastasis in an axillary lymph node (figs. 79, 80). In metastases of the tumor, particularly if the lesion is undifferentiated, its cartilaginous nature may be less obvious.

MICROSCOPIC. Since implantation of chondrosarcoma by biopsy or more extensive operation is common, this risk should be considered in obtaining specimens for microscopic study. Thompson and Steggall have illustrated

such implantation along the tract of a needle biopsy, we have observed it in soft tissues of an upper thigh after a biopsy of a chondrosarcoma of the proximal femur, and Dahlin (1957) has illustrated implantation of chondrosarcoma in an operative scar.

Chondrosarcoma has been misdiagnosed as a benign neoplasm more commonly than any other tumor of bone. Although it must be remembered that an osteosarcoma may contain focal areas of chondrosarcoma, this does not warrant its inclusion in the chondrosarcoma group. When a malignant cartilaginous tumor shows zones of sarcomatous stroma or is forming prominent osteoid, this indicates that the tumor must be classified as an osteosarcoma. The distinction is important because of a difference in prognosis in patients with osteosarcoma versus patients with chondrosarcoma (figs. 68–75).

If the cells of a cartilaginous tumor show extreme variations in patterns, such as multiple nuclei and mitotic figures, diagnosis is certain. In some of the larger cartilaginous tumors, however, microscopic diagnosis depends only on subtleties in variations from normal. These changes have been detailed by Lichtenstein and Jaffe as plump nuclei, atypical nuclei, and multiple nuclei, and seem to be most prominent in peripheral margins of an advancing chondrosarcoma. There invariably are also focal areas of calcification and ossification.

If a cartilaginous tumor is poorly differentiated, there is little doubt that it is a malignant neoplasm. However, if a pathologist is given microscopic sections of a well differentiated cartilaginous tumor or of a neoplasm of intermediate differentiation and is asked whether this tumor is benign or malignant, such distinction may be extremely difficult. In growing cartilaginous tumors of children and in some enchondromas of small bones of the hands or feet, there often are also rather cellular zones that may be difficult to evaluate pathologically. However, it is common practice to curet or enucleate cartilaginous tumors of the hand for diagnosis; fortunately these procedures only rarely are followed by complications. We have seen well differentiated tumors arise from bones of the pelvis, invade soft tissues, recur, and cause death of the patient. We are suspicious of all cartilaginous tumors of the ribs or long bones and of all large tumors around the pelvis regardless of microscopic pattern.

Prior to evaluation of a given cartilaginous tumor, therefore, it is imperative, as with other tumors, that the clinical history and knowledge of size and location of the tumor be available to the pathologist.

PROGNOSIS. Chondrosarcoma has a better prognosis than osteosarcoma. If tumors are separated into low, moderate, and highly malignant, the undifferentiated tumors uniformly will do poorly. Although unusual in our experience, we have seen these tumors undergo changes in which individual cartilage cells transform into zones of fibrosarcoma in both the primary tumor and its metastases (figs. 75, 76). In the past the long term results were poor, because potentialities of the neoplasm were not fully realized and the primary surgical procedure often was inadequate (pl. I–B).

CHONDROBLASTOMA

(Figures 4 and 5 are from the same case*)

Figure 4. Hemisection of a head of a humerus demonstrating a characteristic pattern for chondroblastoma. Although well circumscribed, this lesion in the epiphysial area of a 22-year-old man was destructive of cortex and cancellous bone. After resection of the lesion and repair with a bone graft, the patient was well for at least eight years. A.F.I.P. Acc. No. 218757–84.

Figure 5. Roentgenogram of the specimen in figure 4 shows location of the chondroblastoma with its characteristically distinct margins. A.F.I.P. Acc. No. 218757–85.

Figure 6. Hemisection of a chondroblastoma of a head of a humerus of a young man. Destruction of cortex, epiphysial involvement, lobulation, and hemorrhagic necrosis are seen. The gray-white lobulated tissue resembles cartilage. Periosteum over the tumor appears intact. (Courtesy of Dr. A. J. Ramos, Manila, Philippine Islands.) W.U. 57–863; A.F.I.P. Acc. No. 218757–86.

Figure 7. Roentgenogram of the head of the left humerus in a 16-year-old white girl demonstrates a somewhat mottled and radiolucent area. Margins are indistinct and partly sclerotized. (From the Armed Forces Institute of Pathology.) A. F. I. P. Acc. No. 733670.

---

*From Phemister, D. B. Chondrosarcoma of bone. Surg., Gynec. & Obst., 50:216–233, 1930. Figures 16 and 17 are fascicle figures 4 and 5.

Fig. 4

Fig. 5

Fig. 6

Fig. 7

CHONDROBLASTOMA

Figure 8. Photomicrograph of a chondroblastoma from a head of a femur of a 20-year-old man. Note the multinucleated giant cells, cartilaginous matrix, and round, fairly distinct cells characteristic of chondroblastoma. Hematoxylin and eosin stain. X 165. B.H.* 52–1441; A.F.I.P. Acc. No. 218757–87.

Figure 9. Photomicrograph of a chondroblastoma from a tibia of a 20-year-old man. Distinctly outlined cells and calcium, which is almost invariably present, are demonstrated. Original diagnosis from biopsy was of giant cell tumor, but later curettings were diagnosed incorrectly as chondrosarcoma. Although the lesion is cellular, the atypical nuclei do not have characteristics of a chondrosarcoma. Hematoxylin and eosin stain. X 225. B.H. 44100; A. F. I. P. Acc. No. 218757–88.

*In this and following legends, B. H. stands for Barnes Hospital, St. Louis, Mo.

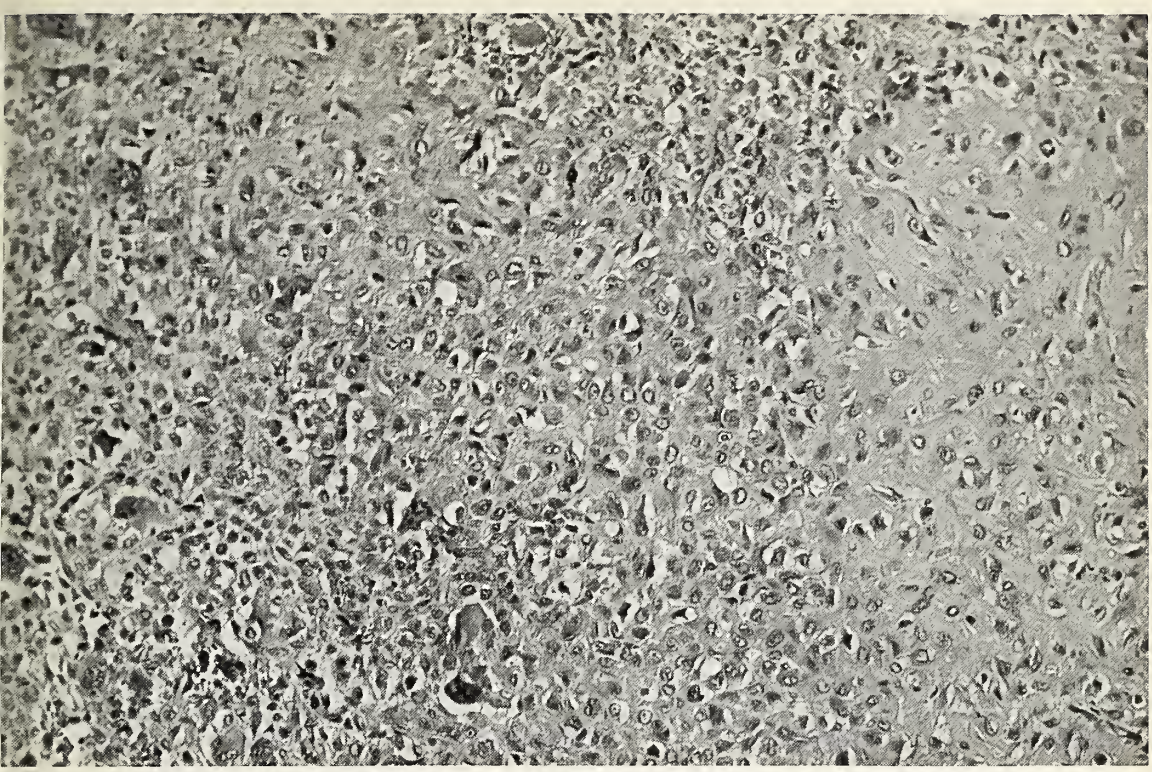

Fig. 8

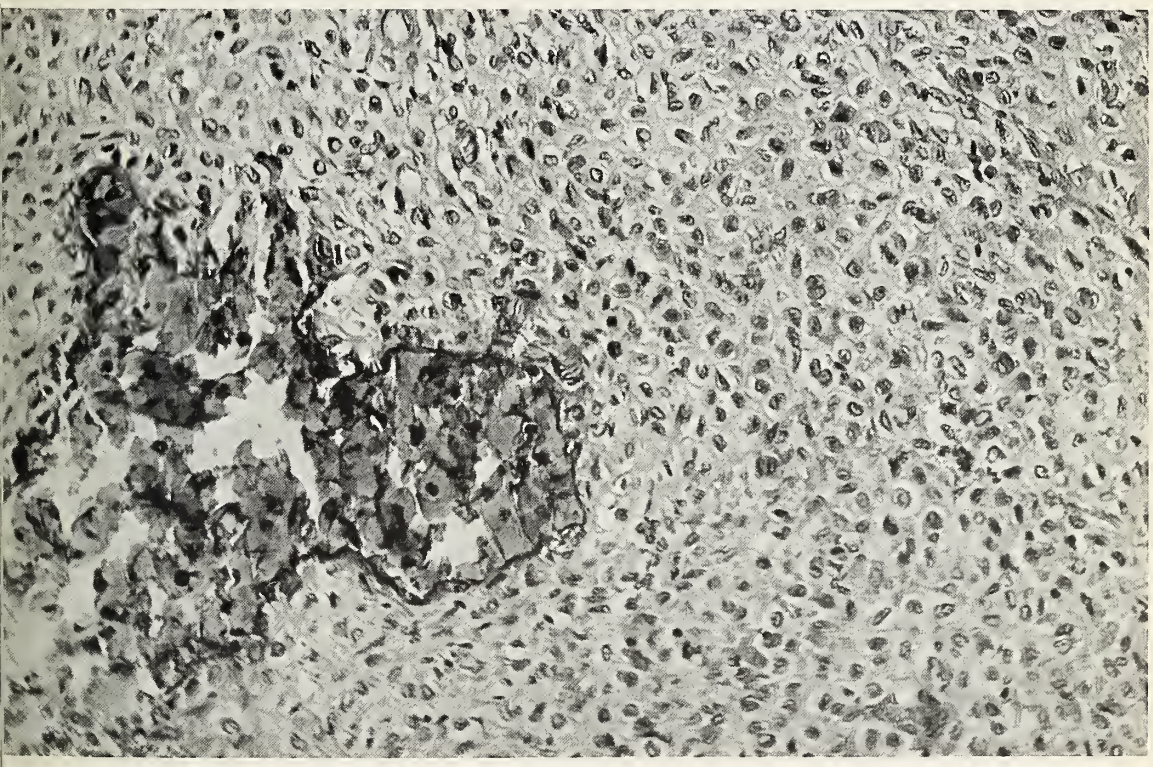

Fig. 9

CHONDROBLASTOMA

Figure 10. Photomicrograph of a section of a chondroblastoma from the greater trochanter of the left femur of a 27-year-old Negro man. Illustrated are the abundant multinucleated giant cells that led to a mistaken diagnosis of giant cell tumor. Elsewhere in the sections more characteristic areas of chondroblastoma were found. Hematoxylin and eosin stain. X 260. (From the Armed Forces Institute of Pathology.) A. F. I. P. Acc. No. 584582.

Figure 11. Photomicrograph of multinucleated giant cells in a chondroblastoma from a head of a femur in a 15-year-old boy. Hematoxylin and eosin stain. X 615. B.H. 52–2188; A. F. I. P. Acc. No. 218757–89.

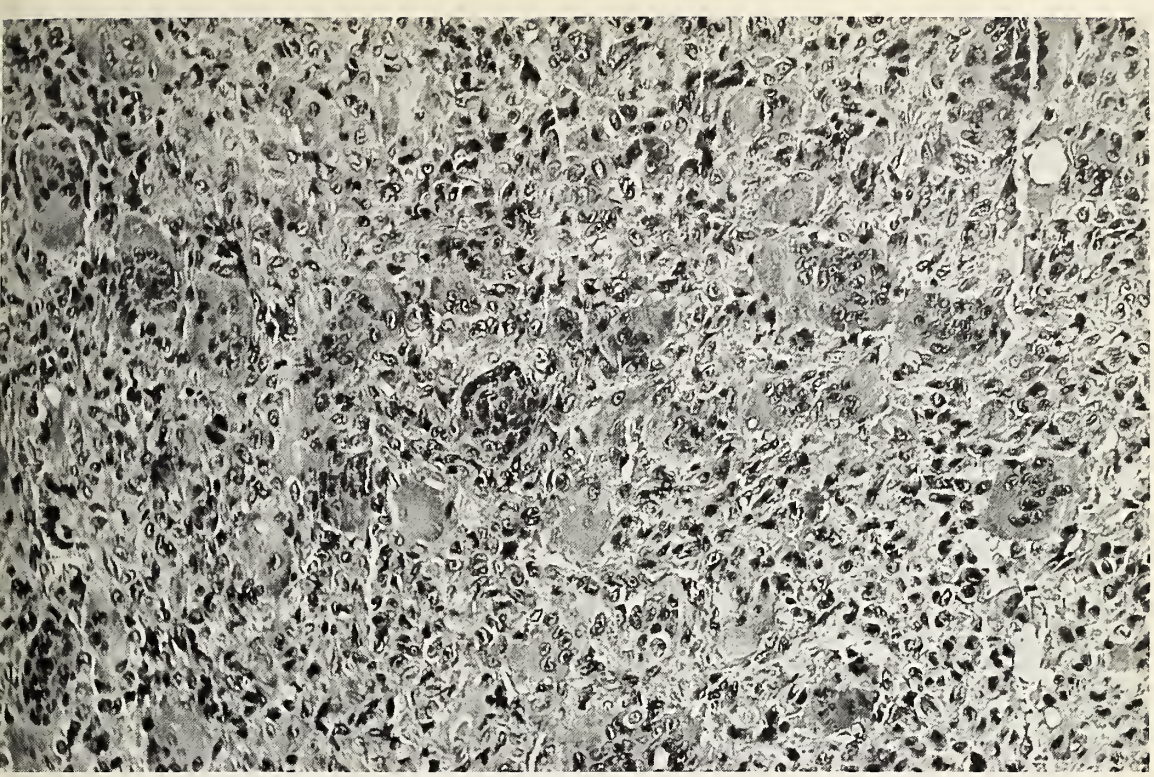

Fig. 10

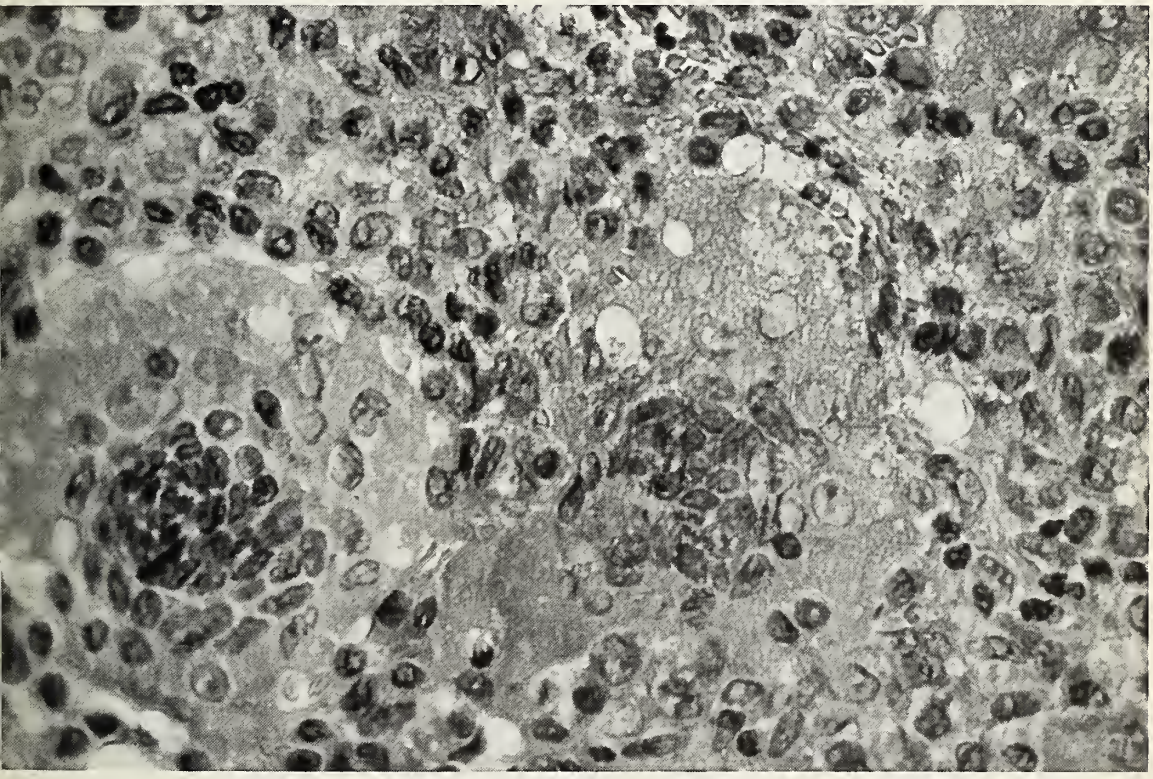

Fig. 11

CHONDROBLASTOMA

(Figures 12 and 13 are from the same case*)

Figure 12. This photomicrograph presents a detailed view of the distinct, rounded cells which form a chondroblastoma; it also shows transition of tissue into cartilage-like matrix. The lesion was curetted from the intercondylar area of the left femur of a 20-year-old man. It had originally been diagnosed as a giant cell tumor of bone. Hematoxylin and eosin stain. X 615. A. F. I. P. Acc. No. 238908–1.

Figure 13. A spindle cell area within the chondroblastoma. This diversity of patterns is commonly seen in histologic studies of this type of tumor and probably accounts for the varied diagnoses offered for biopsies of this lesion. Hematoxylin and eosin stain. X 615. A. F. I. P. Acc. No. 238908–2.

---

*From the Armed Forces Institute of Pathology.

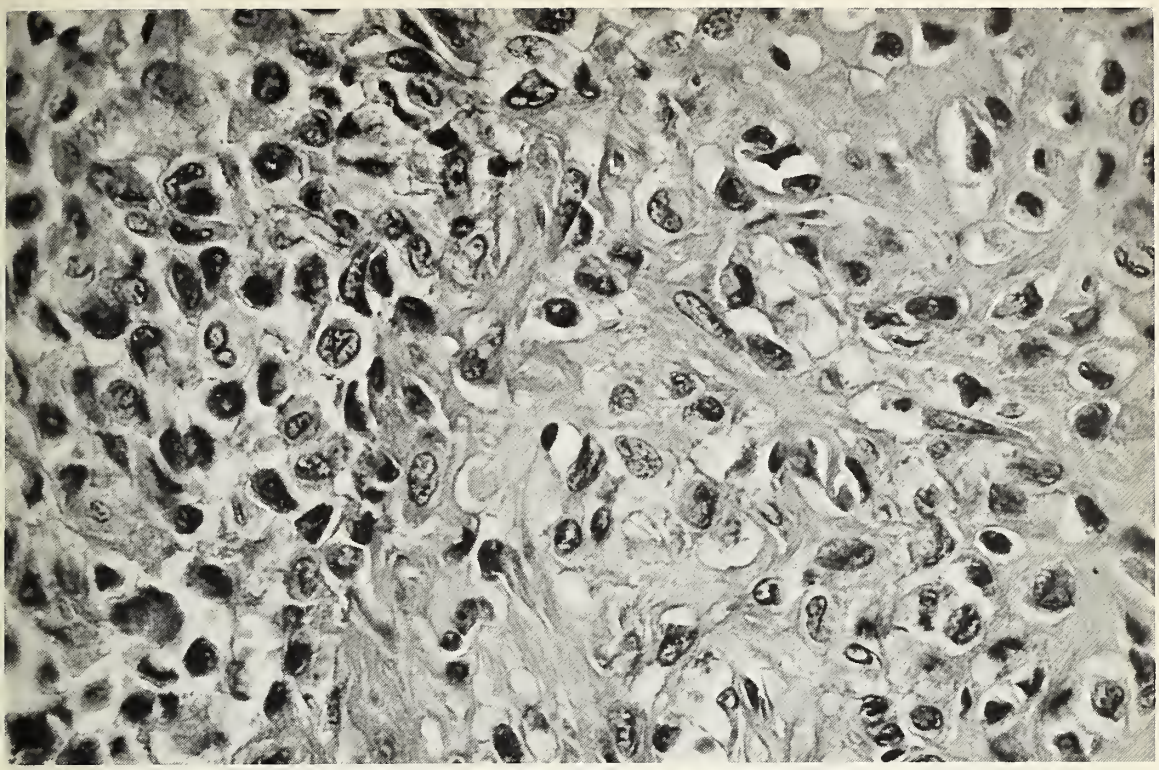

Fig. 12

Fig. 13

CHONDROMYXOID FIBROMA

(Figures 14 and 15 are from the same case.* Figures 16–18 are from the same case)

Figure 14. Illustration of a gross specimen of a chondromyxoid fibroma from the proximal portion of a femur of a 47-year-old man. This tumor is unusual because of its prominent extraosseous component. A. F. I. P. Acc. No. 218757–338.

Figure 15. Hemisection of this femur. Histologically, the lesion proved characteristic of chondromyxoid fibroma. A. F. I. P. Acc. No. 218757–388.

Figure 16.** Roentgenogram demonstrating a multiloculated chondromyxoid fibroma of a rib of a young man. Tumor has greatly expanded the posterior portion of the rib. The expansion and multiloculated appearance of the tumor could be misinterpreted roentgenographically as an aneurysmal bone cyst. A. F. I. P. Acc. No. 268835–3.

Figure 17.** Irregularly eroded cortex of the resected rib is shown. The major part of the tumor is lobulated and shiny, having the appearance of cartilage; a portion also appears cystic. A. F. I. P. Acc. No. 268835–2.

---

*Courtesy of Dr. E. Uehlinger, Zurich, Switzerland.

**From the Armed Forces Institute of Pathology.

Fig. 14

Fig. 15

Fig. 16

Fig. 17

CHONDROMYXOID FIBROMA

(Figures 16–18 are from the same case. Figures 19 and 20 are from the same case.* Figures 21–23 are from the same case)

Figure 18.** Roentgenogram of the gross specimen in figure 17. The reticulated pattern formed by trabeculae traversing the tumor corresponds well to that in figure 16. A. F. I. P. Acc. No. 268835–1.

Figure 19. Roentgenogram shows a fusiform multiloculated-appearing lesion of the distal portion of a fibula of a 16-year-old girl. The patient had had swelling in this region for two years. A. F. I. P. Acc. No. 218757–90.

Figure 20. Resected specimen of this tumor shows a partly cystic but fairly well circumscribed lesion which appears lobulated and cartilaginous. Microscopic sections examined by us showed a typical chondromyxoid fibroma. A. F. I. P. Acc. No. 218757–91.

Figure 21.** Portion of a whole mount section of a chondromyxoid fibroma from the left tibia of a 21-year-old white man. This illustrates the lobulated contour of the tumor and its relation to the bone. Within the tumor are areas of degeneration. Swelling at the site of the tumor was known to have been present for six months. Hematoxylin and eosin stain. X 12. A. F. I. P. Acc. No. 689151–1.

---

*Courtesy of Dr. R. P. Tamayo, Mexico, D. F.

**From the Armed Forces Institute of Pathology.

Fig. 18

Fig. 19

Fig. 20

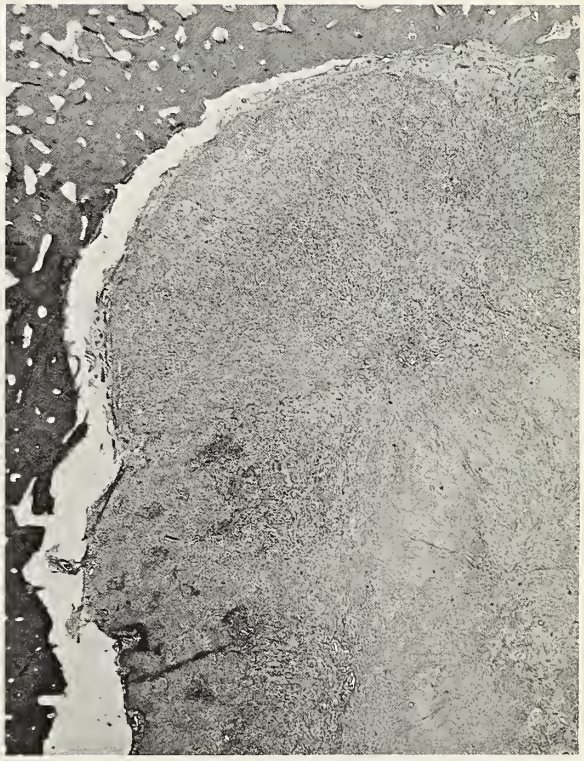

Fig. 21

CHONDROMYXOID FIBROMA

(Figures 21–23 are from the same case)

Figure 22.* Higher power photomicrograph of this tumor shows a vascularized periphery blending with stellate cells and myxomatous background. Relationship between tumor and bone is again seen. Hematoxylin and eosin stain. X 112. A. F. I. P. Acc. No. 689151–2.

Figure 23.* An area of this histologic section viewed at higher microscopic power shows nuclear aberrations which simulate a malignant lesion, such as chondrosarcoma. Similarly selected fields with background matrix of chondroid appearance may be seen in most chondromyxoid fibromas. Hematoxylin and eosin stain. X 700. A. F. I. P. Acc. No. 689151–3.

*From the Armed Forces Institute of Pathology.

Fig. 22

Fig. 23

CHONDROMYXOID FIBROMA

Figure 24. The roentgenogram illustrates a cystic-appearing destructive lesion of the calcaneus, with lobulated outline and thin sclerotized margin.

The patient was a 15-year-old girl who had traumatized her heel four years before excision of the chondromyxoid fibroma. During this 4-year period there had been mild swelling and redness of the heel, but it had not become painful until a month prior to excision of the tumor. W.U. 54–5919; A.F.I.P. Acc. No. 218757–92.

Figure 25. Roentgenogram of a chondromyxoid fibroma of the left femur of a 19-year-old man. The lesion had been curetted twice in 1954. In 1956, a follow-up radiograph was said to be "all right." In 1959, recurrence of the lesion was biopsied and interpreted as chondrosarcoma. Disarticulation at the hip was performed. Review of histologic sections from the biopsy and from the amputation specimen prompted the diagnosis of chondromyxoid fibroma with atypical cellular alterations. W.U. 60–968. (Courtesy of Dr. V. M. Carnes, Columbia, Mo.) A.F.I.P. Acc. No. 218757–398.

Figure 26. Antero-posterior and lateral roentgenographic views show a characteristic defect of a left tibia near the epiphysial plate, with margins of the tumor faintly outlined by sclerotic bone. W.U. 53–5896; A.F.I.P. Acc. No. 218757–93.

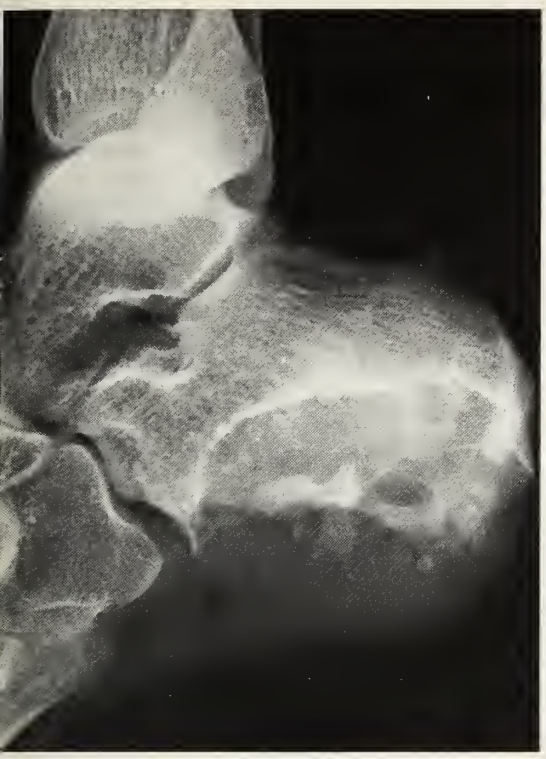

Fig. 24

Fig. 25

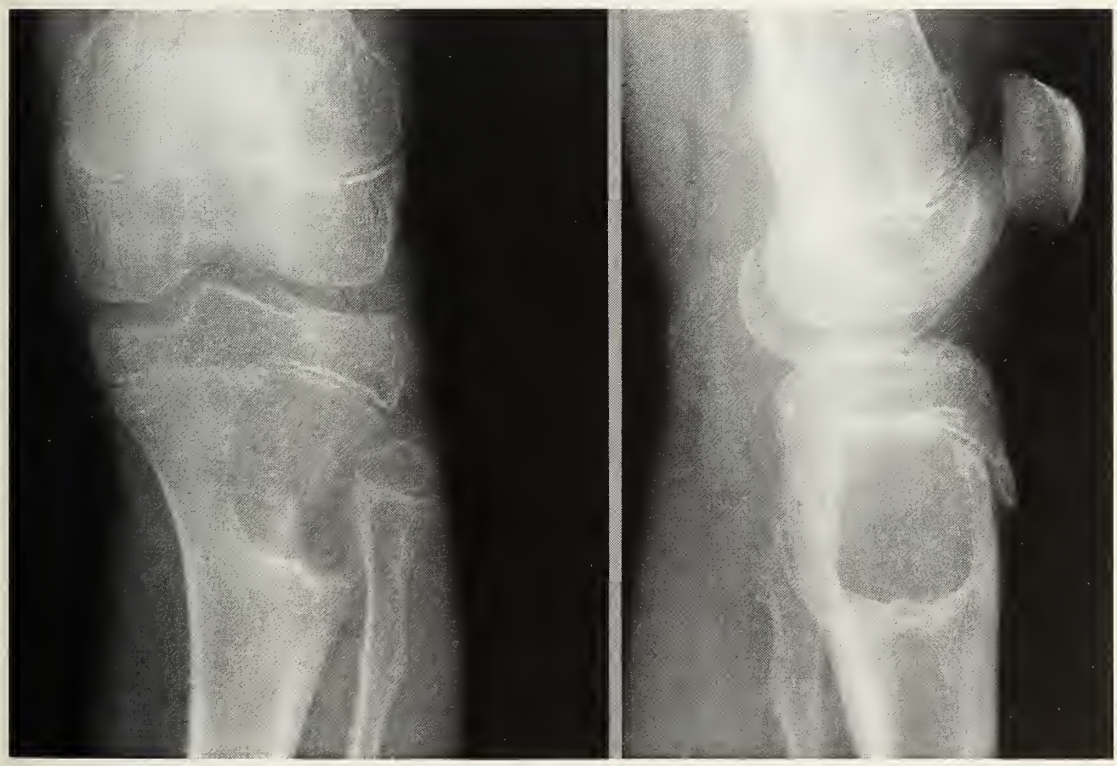

Fig. 26

CHONDROMYXOID FIBROMA

(Figures 27 and 28 are from the same case)

Figure 27. Peripheral cellularity of lobules of a chondromyxoid fibroma, as demonstrated in this photomicrograph, is an outstanding feature of the tumor. Hematoxylin and eosin stain. X 150. B.H. 54-5011; A.F.I.P. Acc. No. 218757-94.

Figure 28. Higher power photomicrograph illustrates the margin of the tumor in association with the fibrous capsule. Hematoxylin and eosin stain. X 225. B.H. 54-5011; A.F.I.P. Acc. No. 218757-95.

Fig. 27

Fig. 28

CHONDROMYXOID FIBROMA

(Figures 30 and 31 are from the same case*)

Figure 29. Focal calcification and edematous fibrous stroma are seen in this microscopic section. The nuclei of the stromal cells are rounded and spindle shaped rather than stellate. The lesion was curetted from the proximal portion of the left tibia of a 50-year-old woman who had had pain in the left knee. This had become progressively severe over a 6-year period. Hematoxylin and eosin stain. X 225. B.H. 54–1651; A.F.I.P. Acc. No. 218757–96.

Figure 30. Photomicrograph of an area of a chondromyxoid fibroma in which the chondroid tissue has the appearance of mature hyaline cartilage. Hematoxylin and eosin stain. X 330. A.F.I.P. Acc. No. 218757–13.

Figure 31. An area of multinucleated giant cells in this chondromyxoid fibroma is shown at higher power. Hematoxylin and eosin stain. X 890. A.F.I.P. Acc. No. 218757–14.

---

*Courtesy of Dr. Leo Lowbeer, Tulsa, Okla.

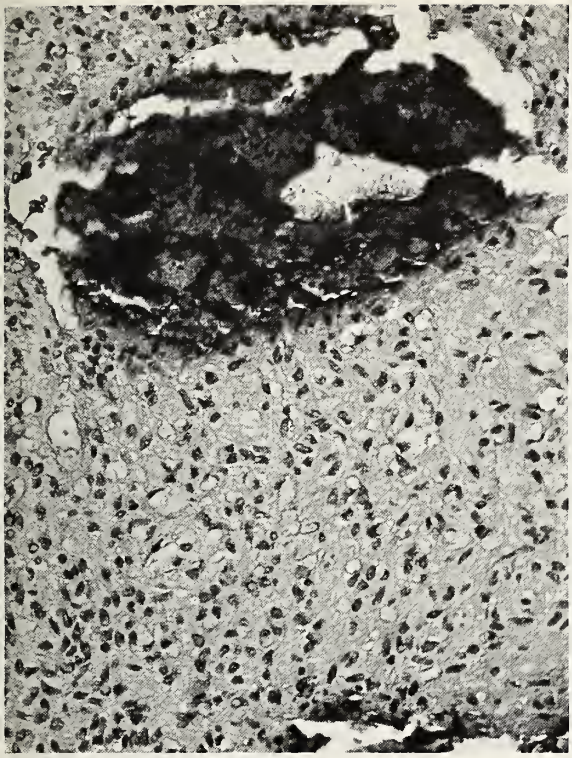

Fig. 29

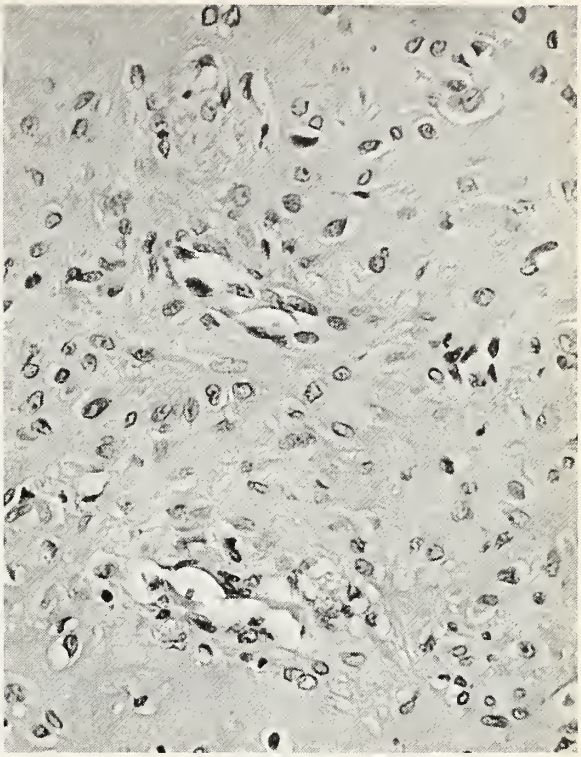

Fig. 30

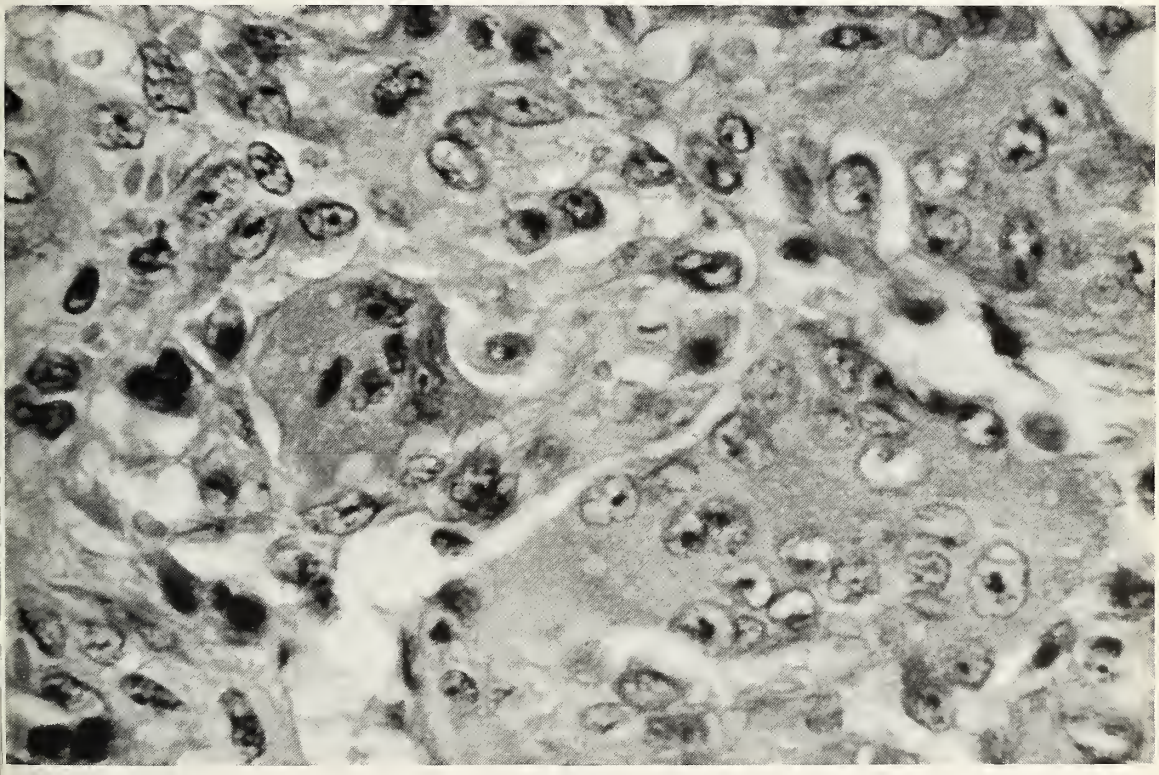

Fig. 31

OSTEOCHONDROMA

(Figure 32 and plate II–A, B are from the same case. Figures 33 and 34 are from the same case)

Figure 32. Photomicrograph illustrating cellular changes in an osteochondroma; one cell is binucleate. Similar cellular areas were seen in multiple sections made from the gross specimen shown in plate II–A, B. Hematoxylin and eosin stain. X 600. W.U. 58–4082; A.F.I.P. Acc. No. 218757–102.

Figure 33. Roentgenogram of an osteochondroma in the distal portion of a femur of a 13-year-old boy. W.U. 58–3985; A.F.I.P. Acc. No. 218757–98.

Figure 34. Gross specimen and cross section of this tumor are shown. Its outer surfaces are knobby; some of the projections are covered by cartilage while others are bony. Its center is heavily ossified and calcified. A thin cartilaginous cap is also noted. W.U. 57–4677; A.F.I.P. Acc. No. 218757–97.

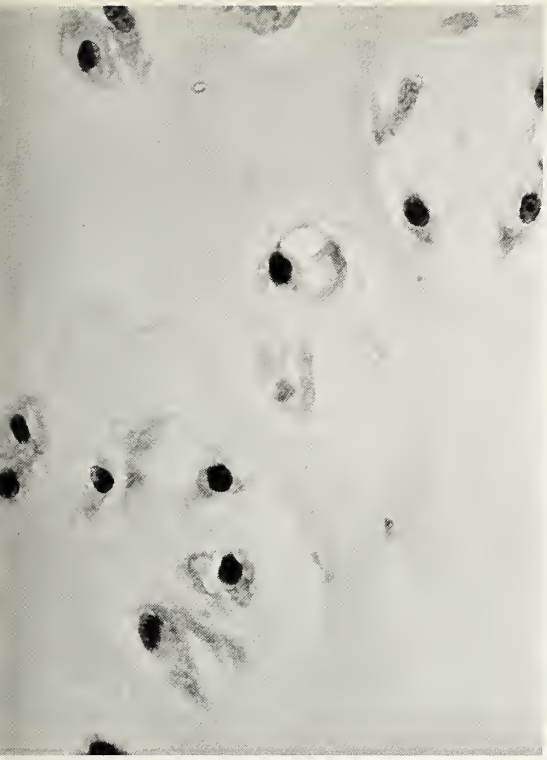

Fig. 32

Fig. 33

Fig. 34

OSTEOCHONDROMA

(Figures 35–37 are from the same case)

Figure 35. This whole mount section of an osteochondroma of the femur shows a thick cartilaginous cap and a zone of chondro-osseous transformation. Only one portion of the surface of the cap is covered by periosteum. Hematoxylin and eosin stain. X 55. W.U. 58–4204; A.F.I.P. Acc. No. 218757–99.

Figure 36. A selected field of the cartilaginous cap of this osteochondroma shows a few atypical cartilage cell nuclei. Usual bone formation is noted at the chondro-osseous junction. Hematoxylin and eosin stain. X 125. A.F.I.P. Acc. No. 218757–49.

Figure 37. Higher power view of the histologic section of the osteochondroma. Hematoxylin and eosin stain. X 550. W.U. 58–4205; A.F.I.P. Acc. No. 218757–103.

Fig. 35

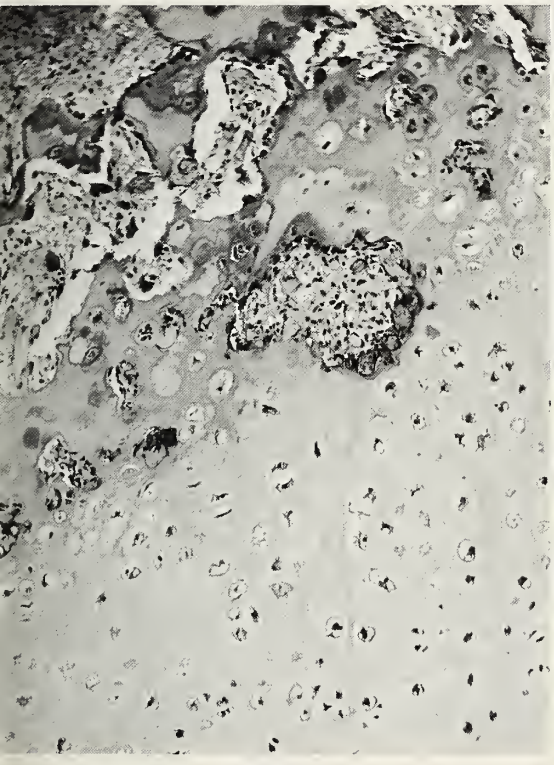

Fig. 36

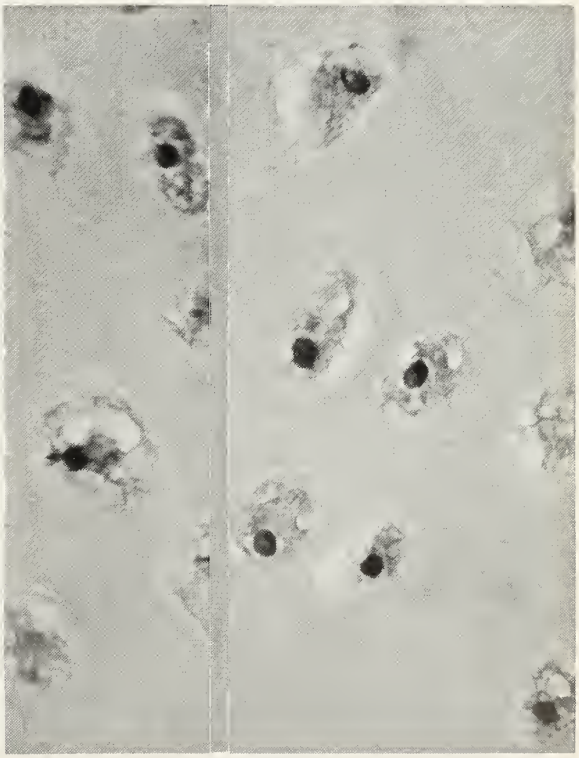

Fig. 37

OSTEOCHONDROMA

(Figures 38 and 39 are from the same case)

Figure 38. Lateral and antero-posterior roentgenograms demonstrate multiple osteochondromas involving the distal portion of a femur and proximal portion of a tibia and fibula. Defects are also apparent in the medullary portions of the bones. W.U. 58–4315; A.F.I.P. Acc. No. 218757–100.

Figure 39. In the roentgenogram, note osteochondromas of the humerus and scapula. A.F.I.P. Acc. No. 218757–101.

MULTIPLE CARTILAGINOUS EXOSTOSES

(Figures 40 and 41 are from the same case)

Figure 40. The roentgenogram illustrates the deformity and shortening of a long bone that accompanies hereditary multiple cartilaginous exostoses. Since the age of 12, this 23-year-old man had been aware of a mass involving the manubrium. Biopsy proved it a low grade chondrosarcoma. W.U. 58–4317; A. F. I. P. Acc. No. 218757–104.

Figure 41. Another mass arose in the lumbar area of the vertebrae of this patient at 26 years of age and was partly removed. Characteristics of this mass which proved to be a chondrosarcoma are shown in the roentgenogram. The patient died four years later. W.U. 58–4316; A. F. I. P. Acc. No. 218757–105.

Fig. 38

Fig. 39

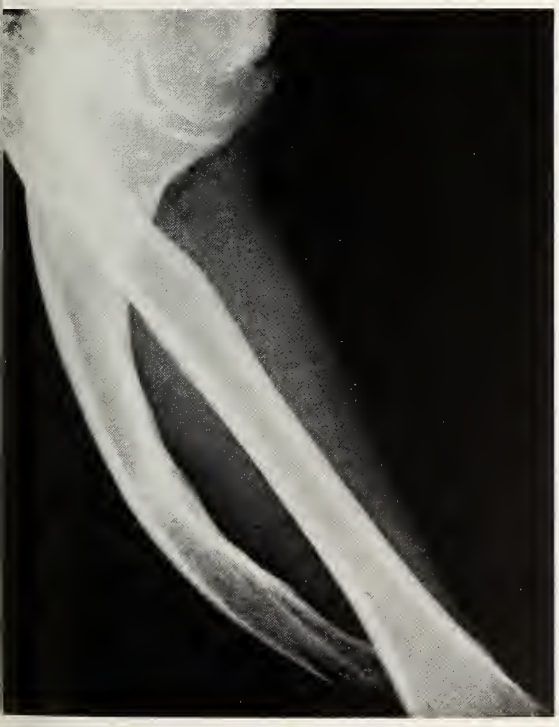

Fig. 40

Fig. 41

ENCHONDROMA

(Figures 43 and 44 are from the same case*)

Figure 42. These multiple, deforming enchondromas were confined to the hands. Usually these tumors cause little or no swelling of the involved parts. (This is figure 1 in Shellito, J. G., and Dockerty, M. B. Cartilaginous tumors of the hand. Surg., Gynec. & Obst., 86:465–472, 1948.) A. F. I. P. Acc. No. 218757–106.

Figure 43. Roentgenogram showing a radiolucent cystic-appearing defect of a proximal phalanx of a thumb. Histologically the tumor was an enchondroma. A.F.I.P. Acc. No. 763895–1.

Figure 44. This photomicrographic field from the tumor illustrates the slight variation in cell types seen in enchondromas. One cell is binucleate. Hematoxylin and eosin stain. X 660. A. F. I. P. Acc. No. 763895–2.

---

*From the Armed Forces Institute of Pathology.

Fig. 42

Fig. 43

Fig. 44

ENCHONDROMA

(Figures 47 and 48 are from the same case)

Figure 45.* This roentgenogram of a right hand illustrates multiple cystlike lesions of proximal and middle phalanges; histologically these lesions were enchondromas. Roentgenogram of the left hand showed no involvement. A. F. I. P. Acc. No. 332547.

Figure 46.* Roentgenogram showing spotty sclerosis in a head of a humerus. Areas such as these may be seen in enchondromas of long bones, in contrast to a more cystic appearance of the tumors in smaller bones. A. F. I. P. Acc. No. 631454.

Figure 47. This photomicrographic field illustrates a typical area of a section of an enchondroma and shows the relationship of tumor to bone. The cartilage cells appear generally well oriented toward maturation, but a few have enlarged hyperchromatic nuclei. Hematoxylin and eosin stain. X 175. B.H. 51-4237; A. F. I. P. Acc. No. 218757-107.

Figure 48. Higher power microscopic view of a different field of this section in which are included a few bizarre nuclei. Fields such as these are common in enchondromas in small bones and may be confused with malignant lesions. Hematoxylin and eosin stain. X 615. B. H. 51-4237; A. F. I. P. Acc. No. 218757-108.

---

*From the Armed Forces Institute of Pathology.

Fig. 45

Fig. 46

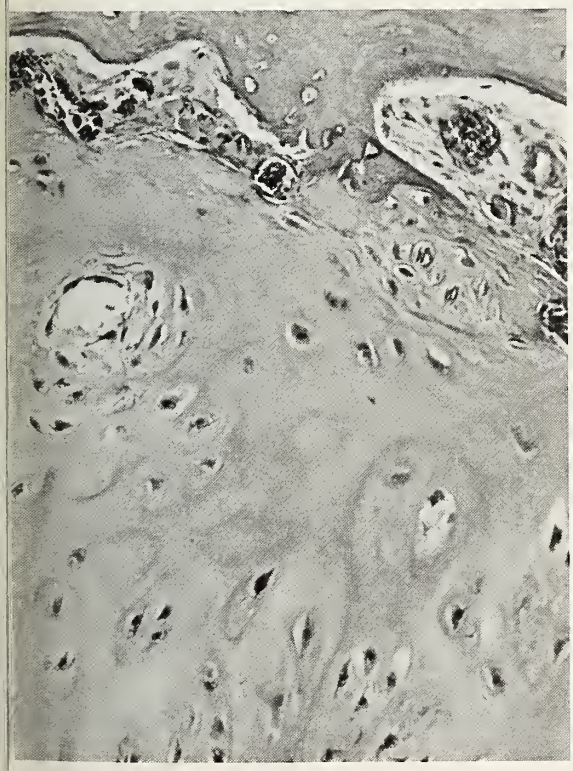

Fig. 47

Fig. 48

OLLIER'S DISEASE

(Figures 49–51 are from the same case)

Figure 49. Histologic section of biopsy material shows mature-appearing cartilage representative of a biopsy done on a 5-year-old boy. Hematoxylin and eosin stain. X 270. W.U. 58–4080; A. F. I. P. Acc. No. 218757–111.

Figure 50. Roentgenogram demonstrating typical features of Ollier's disease in the right femur which was diagnosed in this same patient at 13 years of age. In the lower portion of the femur, a streaming effect is seen with what appears to be spotty calcification in the cartilaginous portions. W.U. 58–3982; A. F. I. P. Acc. No. 218757–109.

Figure 51. Roentgenogram of the right tibia of this patient. W.U. 58–3981; A. F. I. P. Acc. No. 218757–110.

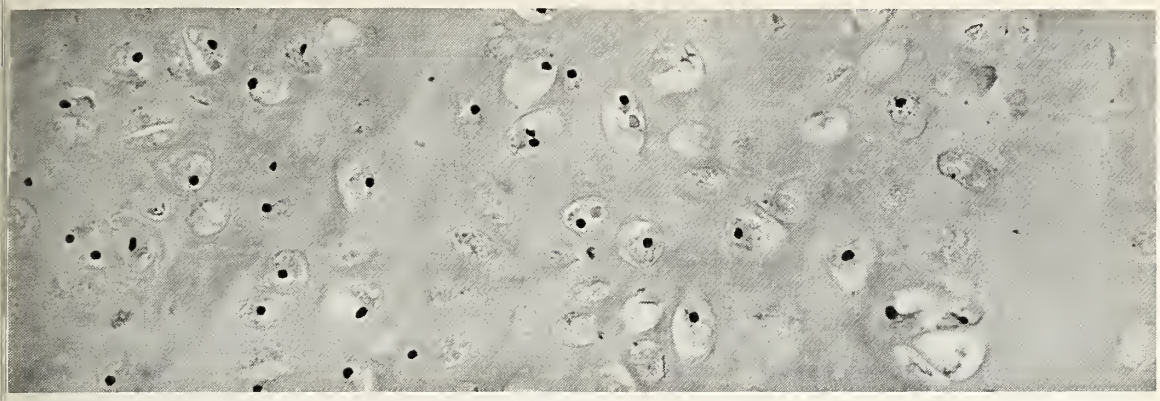

Fig. 49

Fig. 50

Fig. 51

OLLIER'S DISEASE

(Figures 52–54 are from the same case*)

Figure 52. This 59-year-old man had advanced Ollier's disease. In the photograph, note extreme deformity of the upper right extremity and hand and the nodules which are evident along the ribs. Progression of the disease had been observed for 19 years and seemed to be confined to one side of the body. There were associated hemangiomas. A. F. I. P. Acc. No. 218757–112.

Figure 53. Arteriogram of the extremity demonstrates shortening of upper arm, deformity of radius and ulna, and multiple cartilaginous tumors containing spotty calcification. Destruction of bones of the hand is almost complete. A. F. I. P. Acc. No. 218757–113.

Figure 54. Roentgenogram of a foot of this patient outlines a mass which was histologically a chondrosarcoma. A. F. I. P. Acc. No. 218757–114.

---

*From Tiwisina, T. Dyschondroplasie (Ollier) mit multiplen Haemangiomen und örtlicher maligner Entartung (Chondrosarkom). Beitr. klin. Chir., 188:8–15, 1954. Figures 1, 2, and 3b are fascicle figures 52–54.



Fig. 52

Fig. 53

Fig. 54

CHONDROSARCOMA

(Figures 55 and 56 are from the same case)

Figure 55. Roentgenogram demonstrating a characteristic chondrosarcoma, a large, partly calcified, partly ossified mass involving the wing of the left ilium.

The lesion occurred in a 38-year-old man. It was locally resected in 1945. It recurred, and four re-excisions were done over a period of four years. The patient finally died in the fourth year with inoperable local persistence. W.U. 51–4297; A. F. I. P. Acc. No. 218757–115.

Figure 56. The photomicrograph represents histologic findings of this fairly well differentiated chondrosarcoma. Numbers of bizarre and enlarged nuclei are noted. Hematoxylin and eosin stain. X 105. B.H. 67832; A. F. I. P. Acc. No. 218757–130.

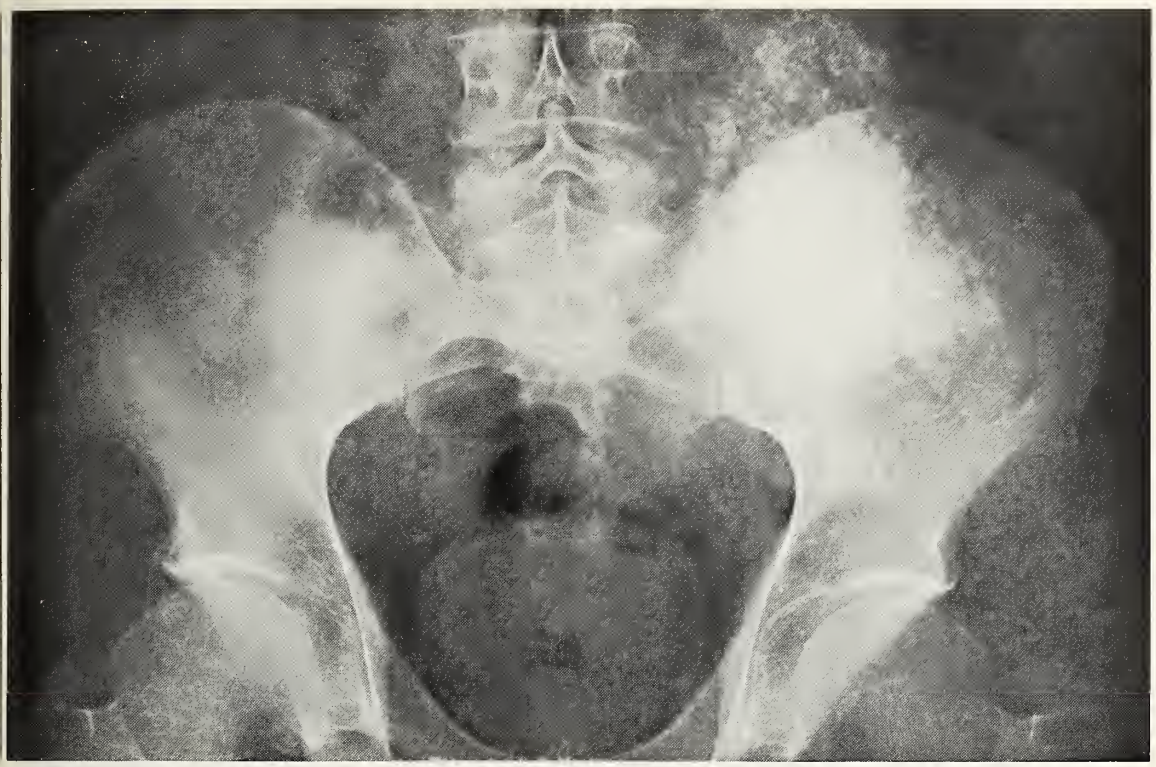

Fig. 55

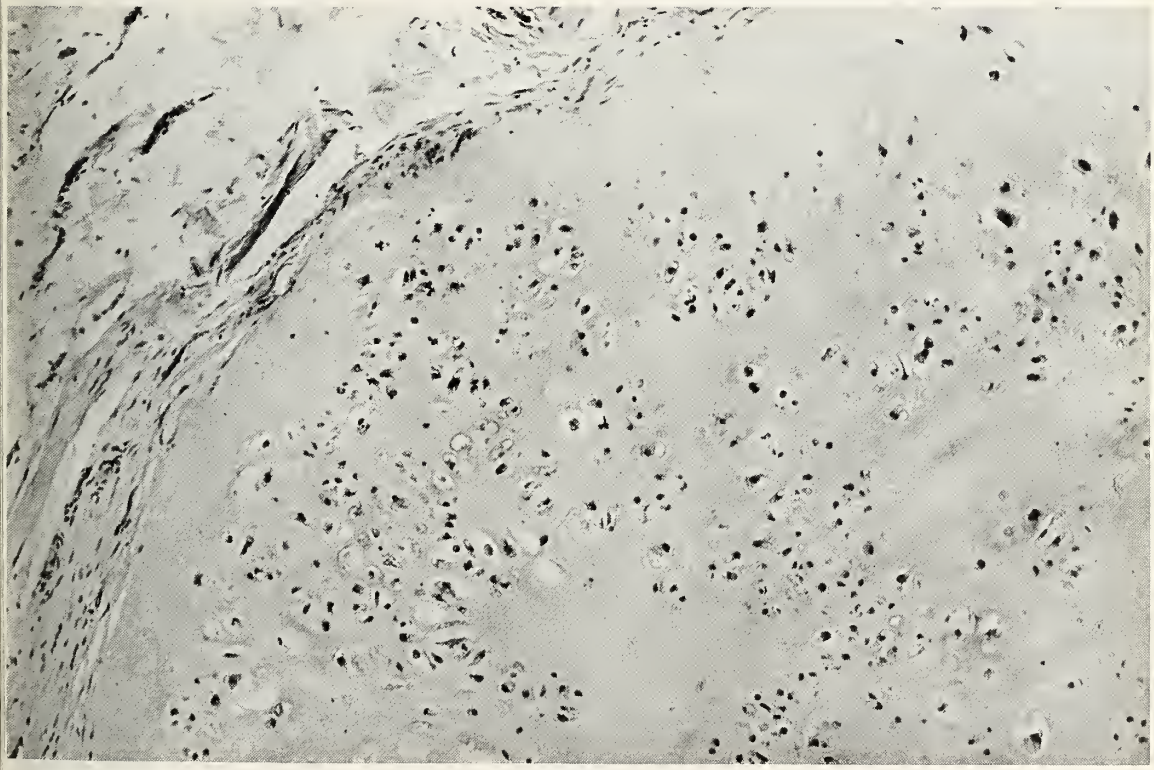

Fig. 56

CHONDROSARCOMA

(Figures 57 and 58 are from the same case)

Figure 57. Roentgenographic illustration of focal calcification in a chondrosarcoma removed from a 12th rib of a 36-year-old man. W.U. 48-6675; A. F. I. P. Acc. No. 218757-117.

Figure 58. Hemisection demonstrates characteristic lobulated contour and cartilaginous convolutions often seen in chondrosarcomas. Cystic degeneration and numerous areas of calcification are present. W.U. 48-6599; A. F. I. P. Acc. No. 218757-116.

Fig. 57

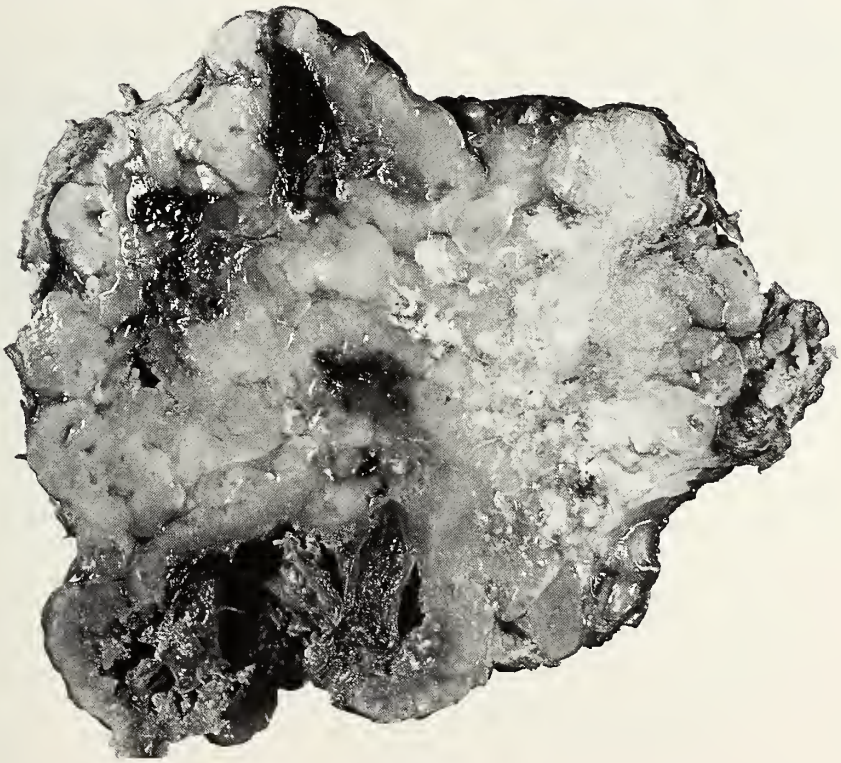

Fig. 58

CHONDROSARCOMA

(Figures 59–61 are from the same case*)

Figures 59 and 60. A chondrosarcoma of the lower end of a femur of a 42-year-old man is shown on the roentgenograms. The tumor mass had been present for five years but had recently increased in size.

This tumor with osseous and calcific components is fairly characteristic of peripheral chondrosarcoma. It has a broad base and is so situated that it would be amenable to block excision. B.H. 56–9006; A. F. I. P. Acc. Nos. 218757–118, 119.

Figure 61. This cross section of the tumor contains a large quantity of bone. Centrally and peripherally there are large islands of calcific material. The characteristic thick cartilaginous cap is present, as is lobular contour. W.U. 57–780; A. F. I. P. Acc. No. 218757–120.

---

*Courtesy of Dr. O. P. Hampton, Jr., St. Louis, Mo.

Fig. 59

Fig. 60

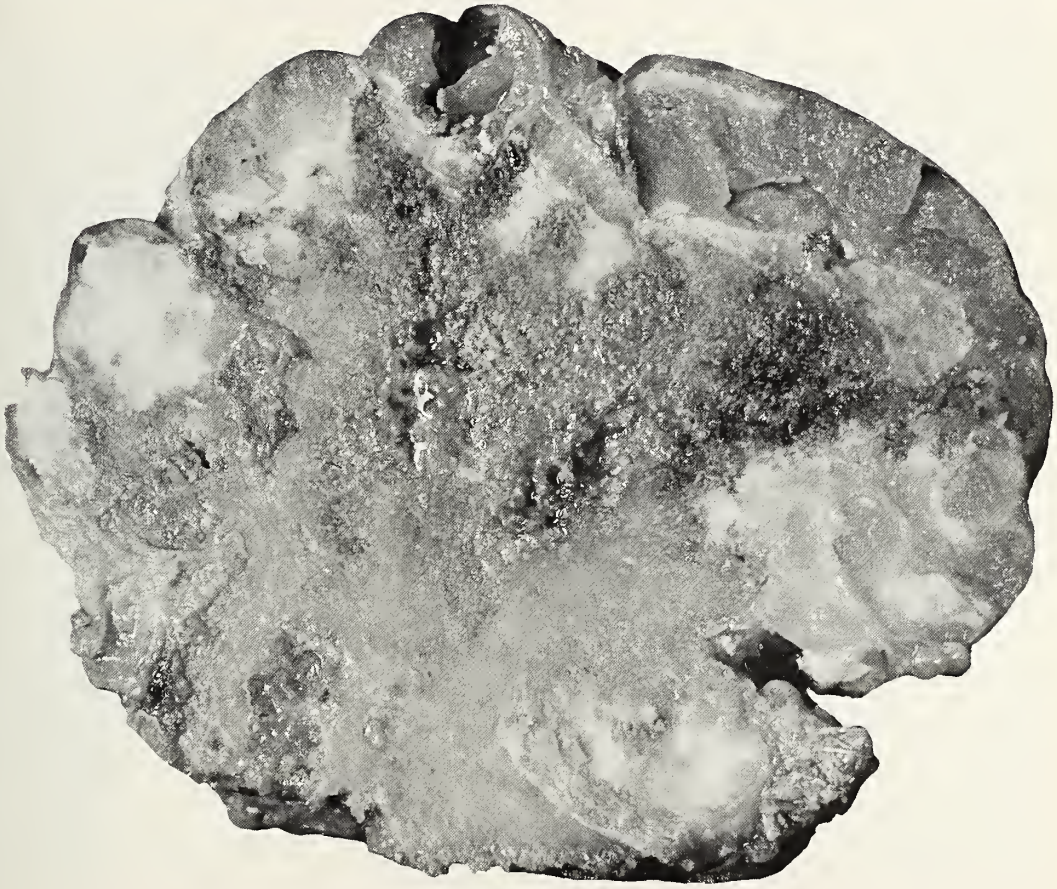

Fig. 61

CHONDROSARCOMA

(Figures 62 and 63 are from the same case)

Figure 62. Roentgenogram showing a mass on the left pubic ramus near the symphysis. This was interpreted as chondrosarcoma. The patient was a 31-year-old woman who had had progressive urinary frequency for eight weeks. Pelvic examination had disclosed a hard mass. Without biopsy, block excision of the tumor was done. W.U. 54–3577; A. F. I. P. Acc. No. 218757–121.

Figure 63. Gross specimen of this mass presented knobby outer surfaces. Cut surfaces revealed shiny convoluted masses of cartilage intermingled with calcium deposits. Tumor extended into the ramus of the pubic bone and grossly the symphysis was not involved, but a small osteochondroma was attached nearby. Histologically this tumor was diagnosed as a well differentiated chondrosarcoma. The patient was living at least four years without evidence of persistent disease. W.U. 54–3512; A. F. I. P. Acc. No. 218757–122.

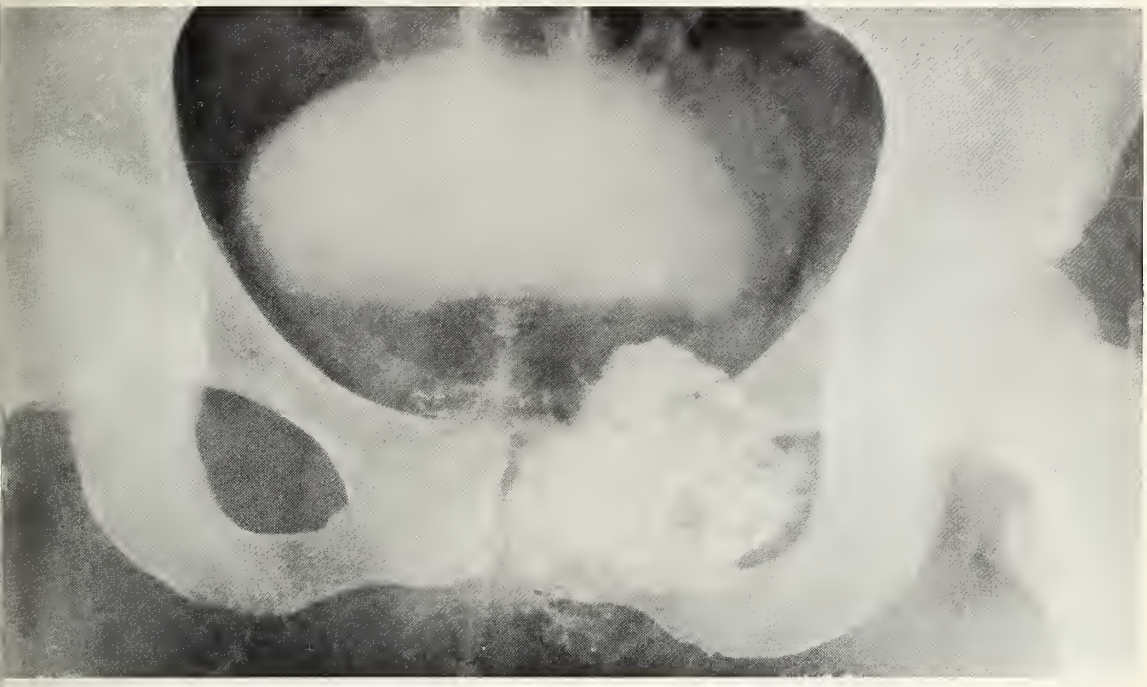

Fig. 62

Fig. 63

CHONDROSARCOMA

(Figures 64 and 65 are from the same case. Figures 66 and 67 are from the same case*)

Figure 64. A central area of destruction and an extraosseous component of a tumor are to be noted in this roentgenogram; biopsy site is evident. The patient was living and well at least seven years postoperatively. W.U. 51–4587; A. F. I. P. Acc. No. 218757–124.

Figure 65. Resected specimen of the chondrosarcoma of the proximal portion of a femur of this 39-year-old man. The centrally destructive portion and extraosseous components of the tumor outlined by roentgenogram are confirmed. This suggests that the tumor arose centrally. W.U. 51–4627; A. F. I. P. Acc. No. 218757–123.

Figure 66. Clinical photograph of a 19-year-old girl with multiple cartilaginous exostoses (diaphysial aclasia). The mass shown had grown rapidly within six months to measure 57 cm. in circumference. Exostoses were present on all four extremities and the ribs. Since the patient refused disarticulation, the tumor increased in circumference to 100 cm. during the next two years. A hemipelvectomy was performed. At least 13 years later the patient was living and well. A. F. I. P. Acc. No. 218757–126.

Figure 67. Roentgenogram of this large chondrosarcoma of the right femur. Note spotty calcification, ossification, and lobulated appearance which are characteristics of this lesion. W.U. 57–2885; A. F. I. P. Acc. No. 218757–125.

---

*Courtesy of Ellis Fischel State Cancer Hospital, Columbia, Mo.

Fig. 64

Fig. 65

Fig. 66

Fig. 67

CHONDROSARCOMA

Figure 68. Photomicrograph illustrating an advancing boundary line of a well differentiated chondrosarcoma of the rib. The cartilage cells remain reasonably well oriented. Only a few atypical nuclei may be seen. Hematoxylin and eosin stain. X 98. B.H. 52–4203; A. F. I. P. Acc. No. 218757–127.

Figure 69. This photomicrograph shows a variation in the pattern of chondrosarcoma. Cells in this tumor have assumed a spindle-like pattern. Atypical nuclei are present. Relationship of tumor to peripheral bone is demonstrated. Hematoxylin and eosin stain. X 112. B.H. 46464; A. F. I. P. Acc. No. 218757–128.

Figure 70. Photomicrograph showing well oriented cartilage cells with evidence of enchondral bone formation. The cartilage cells demonstrate bizarre and plump nuclei. The characteristics of these cartilage cells, with the additional features of the roentgenogram and gross pattern, aid in the diagnosis of chondrosarcoma. Hematoxylin and eosin stain. X 98. B.H. 56–9006; A. F. I. P. Acc. No. 218757–129.

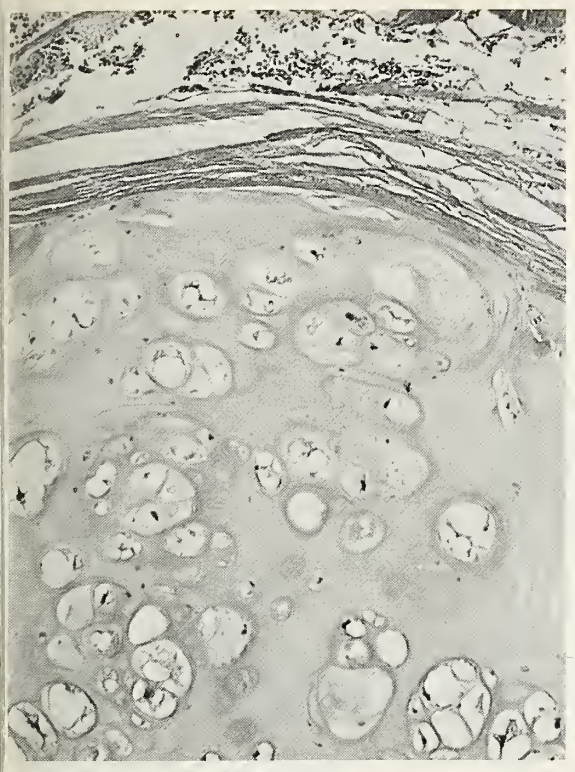

Fig. 68

Fig. 69

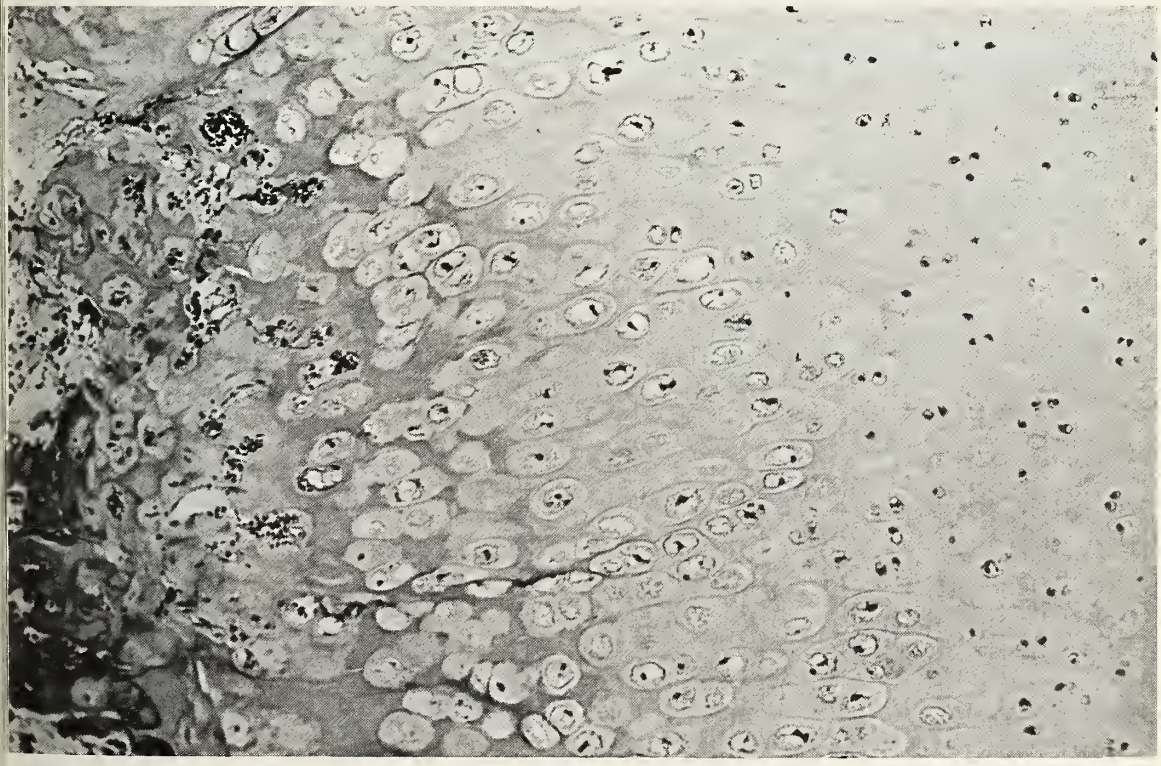

Fig. 70

CHONDROSARCOMA

(Figures 73 and 74 are from the same case)

Figure 71. Photomicrograph of this well differentiated chondrosarcoma also shows "plump" and bizarre nuclei and binucleate cells. Hematoxylin and eosin stain. X 245. B.H. 57–836; A. F. I. P. Acc. No. 218757–131.

Figure 72. The chondrosarcoma in this photomicrograph is poorly differentiated; malignant-appearing nuclei are obvious. Cartilage cells have lost normal groupings. Histologic diagnosis in this lesion is comparatively simple in contrast to that for figure 71. Hematoxylin and eosin stain. X 550. B.H. 55–153; A. F. I. P. Acc. No. 218757–132.

Figure 73. Poorly differentiated chondrosarcoma of a humerus. This photomicrograph illustrates the lobular pattern and myxomatous character that may be seen in chondrosarcomas. Hematoxylin and eosin stain. X 119. B.H. 39668; A. F. I. P. Acc. No. 218757–133.

Figure 74. Higher power microscopic view shows the myxomatous background and bizarre stellate cells. Hematoxylin and eosin stain. X 615. B.H. 39668; A. F. I. P. Acc. No. 218757–134.

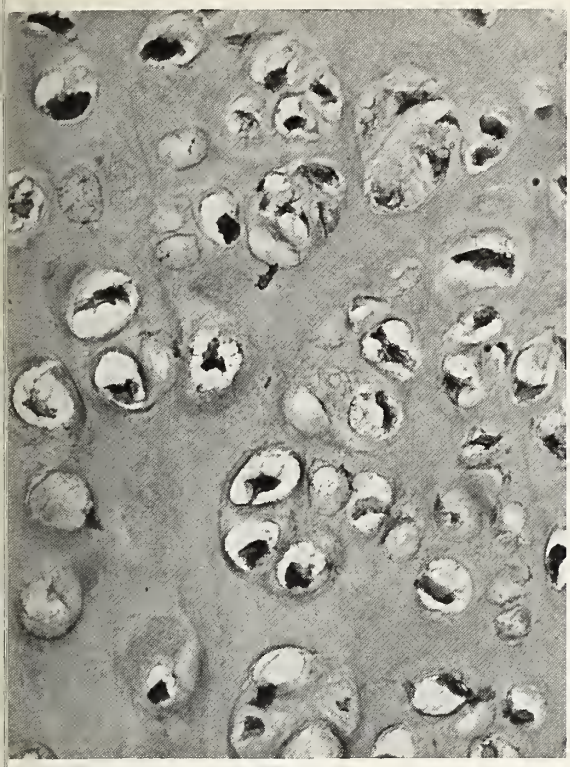

Fig. 71

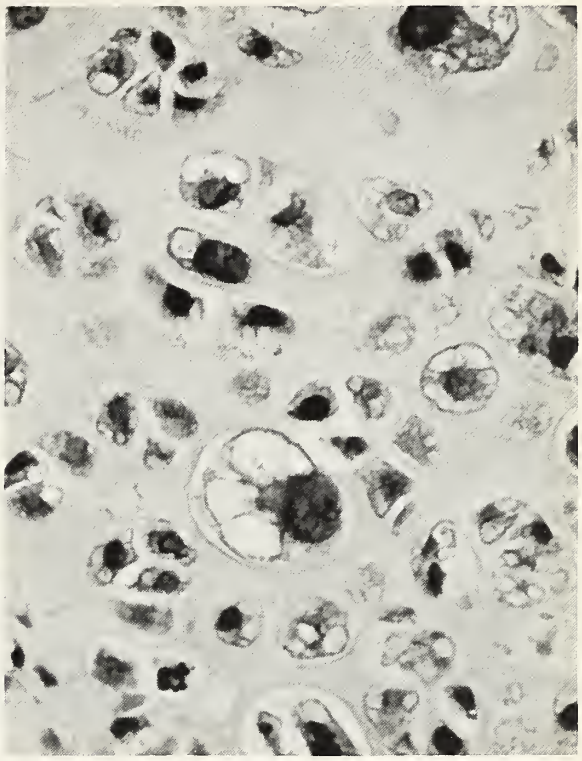

Fig. 72

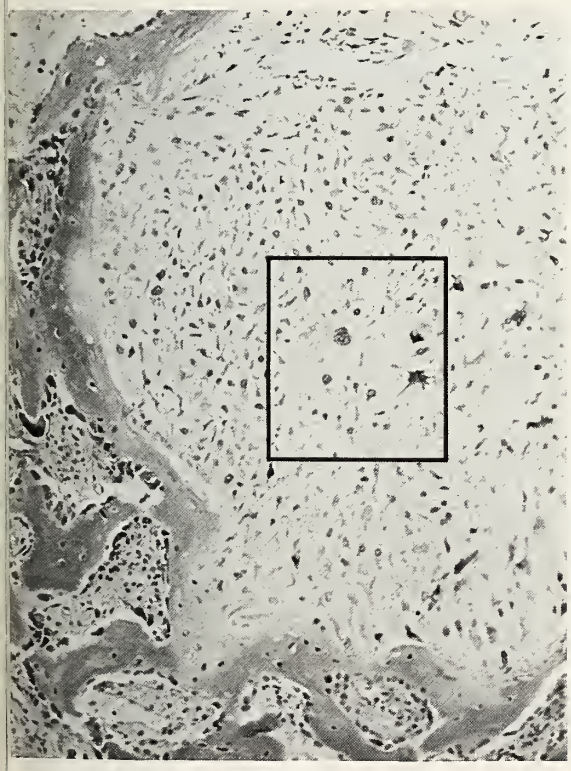

Fig. 73

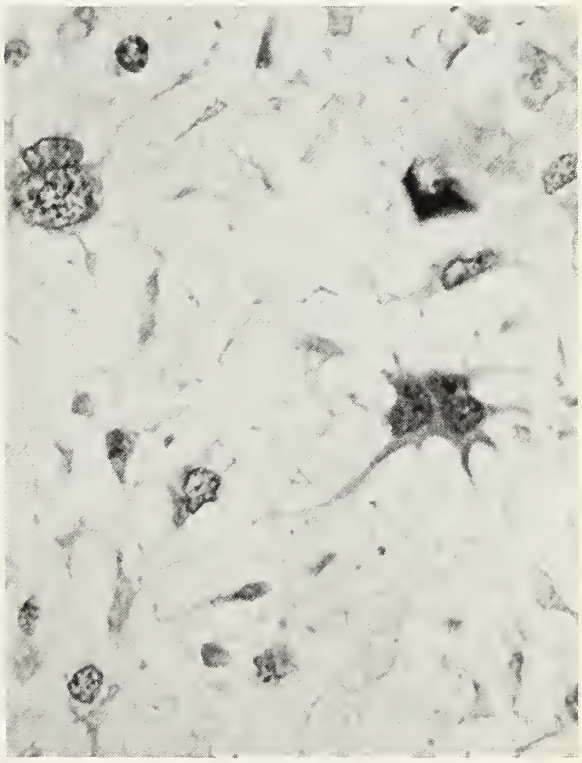

Fig. 74

CHONDROSARCOMA

(Figures 75 and 76 are from the same case)

Figure 75. Photomicrograph of a section of a poorly differentiated chondrosarcoma removed by local resection from the proximal portion of a femur of a 49-year-old man. Note myxomatous background and bizarre tumor cells. Previous biopsy had been interpreted as chondrosarcoma.

The resected femur was replaced by a metallic prosthesis. Two months later chest roentgenograms revealed findings interpreted incorrectly as lung abscess. Hematoxylin and eosin stain. X 660. B.H. 67120; A. F. I. P. Acc. No. 218757–135.

Figure 76. Photomicrograph of a representative section of the lung lesion obtained at pneumonectomy, following which the patient had died. This was interpreted as metastatic chondrosarcoma with a fibrosarcomatous pattern. At autopsy, additional metastatic nodules were found in the opposite lung and pleura. Examination of the stump of the femur revealed persistent sarcoma having a pattern similar to that in the metastatic lesions. Hematoxylin and eosin stain. X 245. B.H. 68122; A. F. I. P. Acc. No. 218757–136.

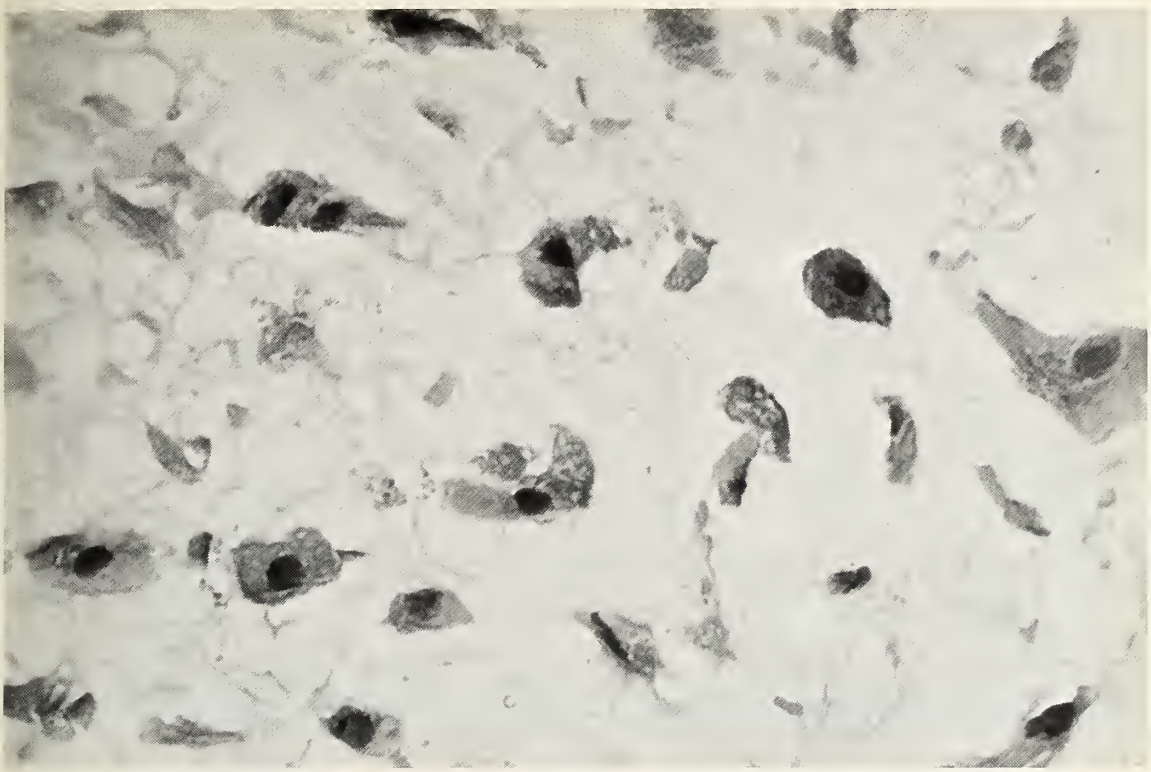

Fig. 75

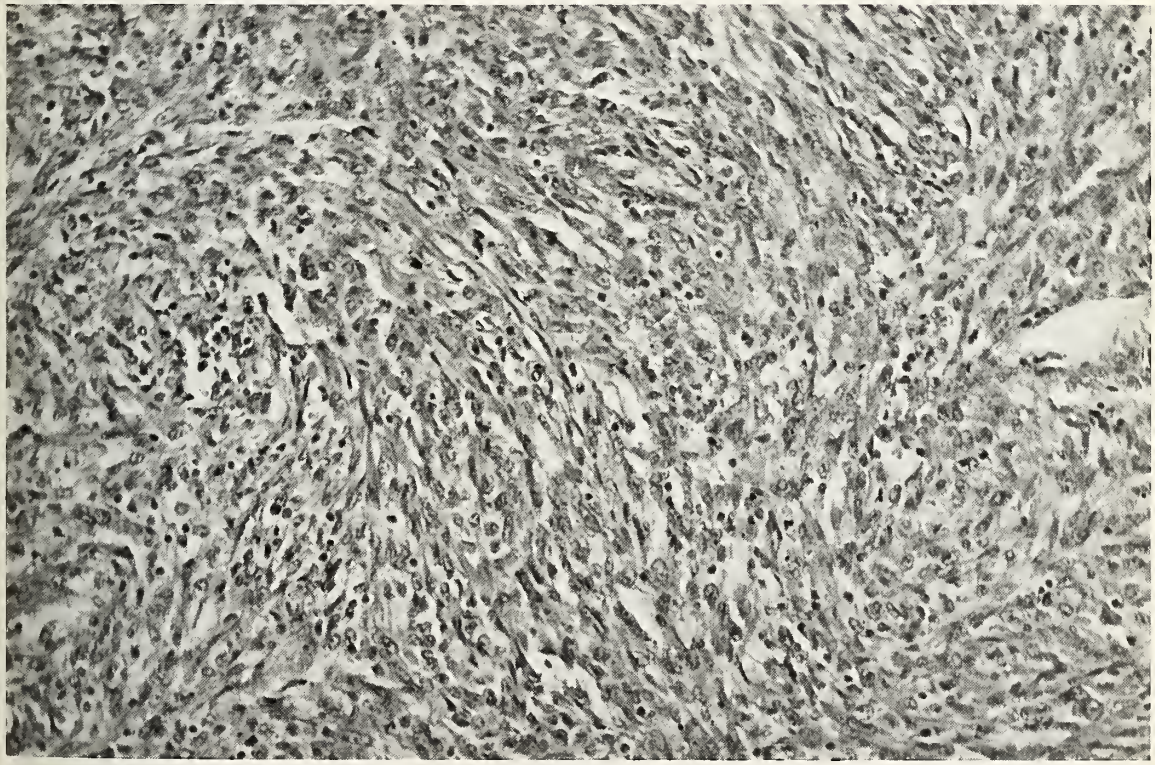

Fig. 76

CHONDROSARCOMA

(Figure 78 and plate 1–A are from the same case)

Figure 77. Bizarre and "plump" nuclei in a rather well differentiated chondrosarcoma from a pelvis. This histologic section also shows tumor protruding through the cortical bone into the surrounding soft tissues. This pattern and the lobular pattern seen grossly illustrate the danger of enucleating these tumors. Persistent tumor is almost inevitable. Hematoxylin and eosin stain. X 125. (Courtesy of Dr. Maurice Ernest, Moose Jaw, Saskatchewan, Canada.) W.U. 58–3091; A. F. I. P. Acc. No. 218757–137.

Figure 78. This photomicrograph represents a section from a recut tissue block of a biopsy, initially interpreted as a benign lesion of a finger. Note the malignant cartilage cells in the tumor. Hematoxylin and eosin stain. X 400. B.H. 57–5026; A. F. I. P. Acc. No. 218757–138.

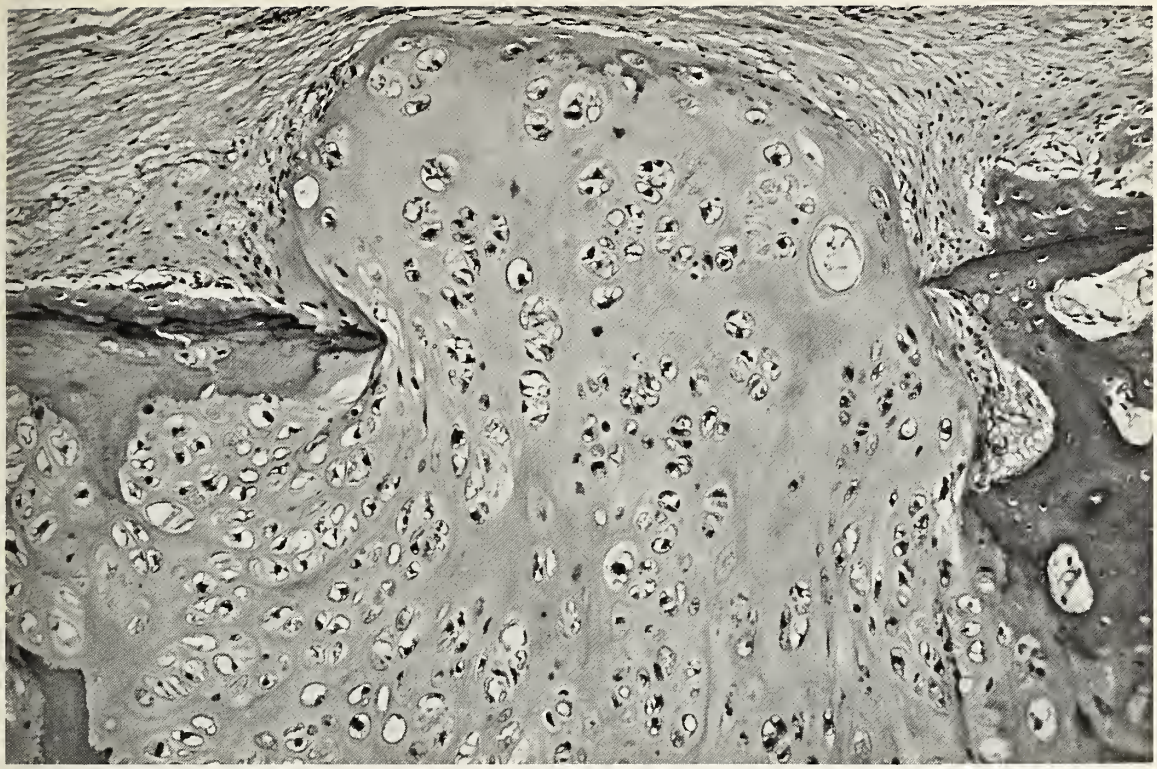

Fig. 77

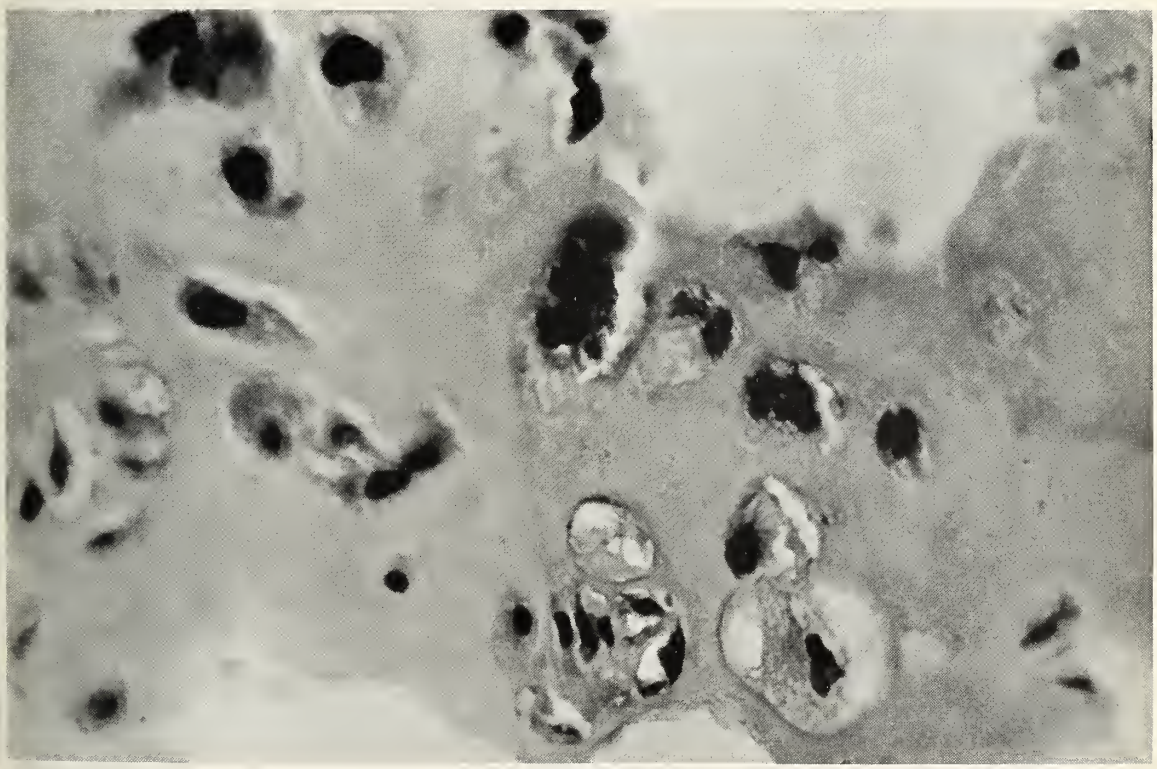

Fig. 78

CHONDROSARCOMA

(Figures 79 and 80 are from the same case)

Figure 79. This photomicrograph represents the only instance we have seen of chondrosarcoma metastatic in a lymph node. The patient was a 28-year-old woman with primary chondrosarcoma of the ribs. Hematoxylin and eosin stain. X 84. B.H. 51–204; A. F. I. P. Acc. No. 218757–139.

Figure 80. Higher power magnification of this tumor shows the malignant character of the cells, although they retain a recognizable cartilaginous appearance. Lymphocytes and plasma cells are noted (left). Hematoxylin and eosin stain. X 705. B.H. 51–204; A. F. I. P. Acc. No. 218757–140.

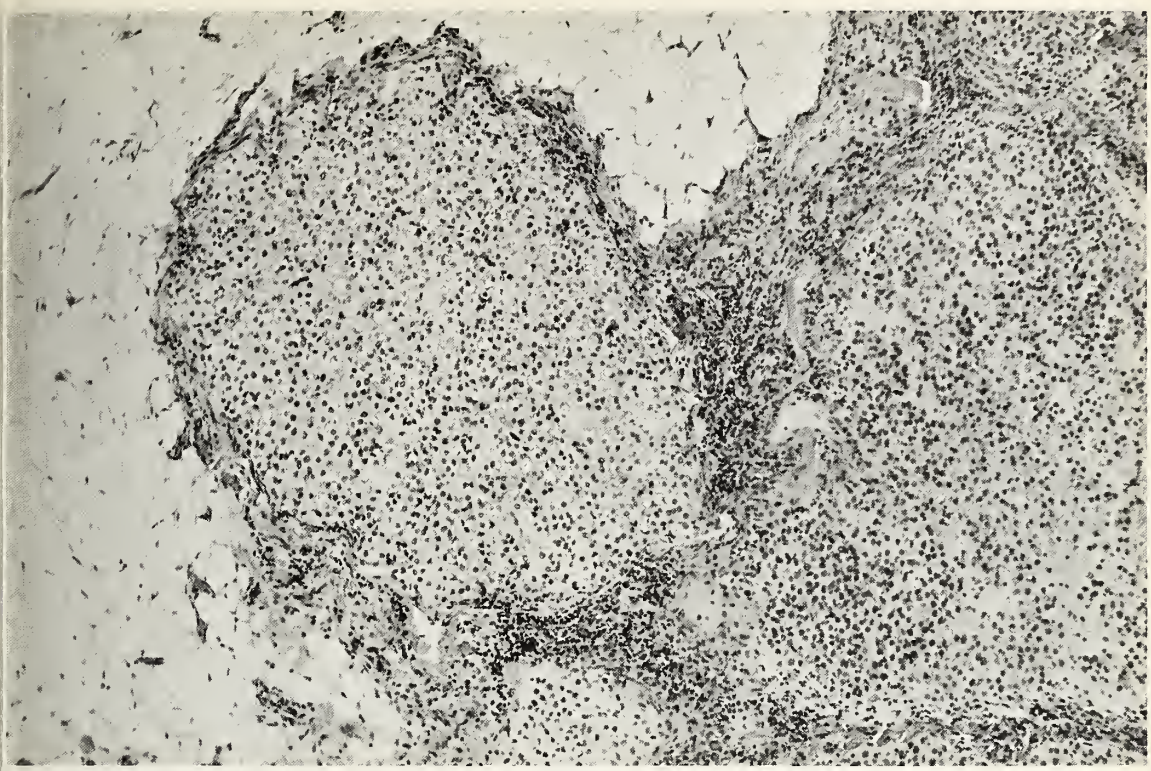

Fig. 79

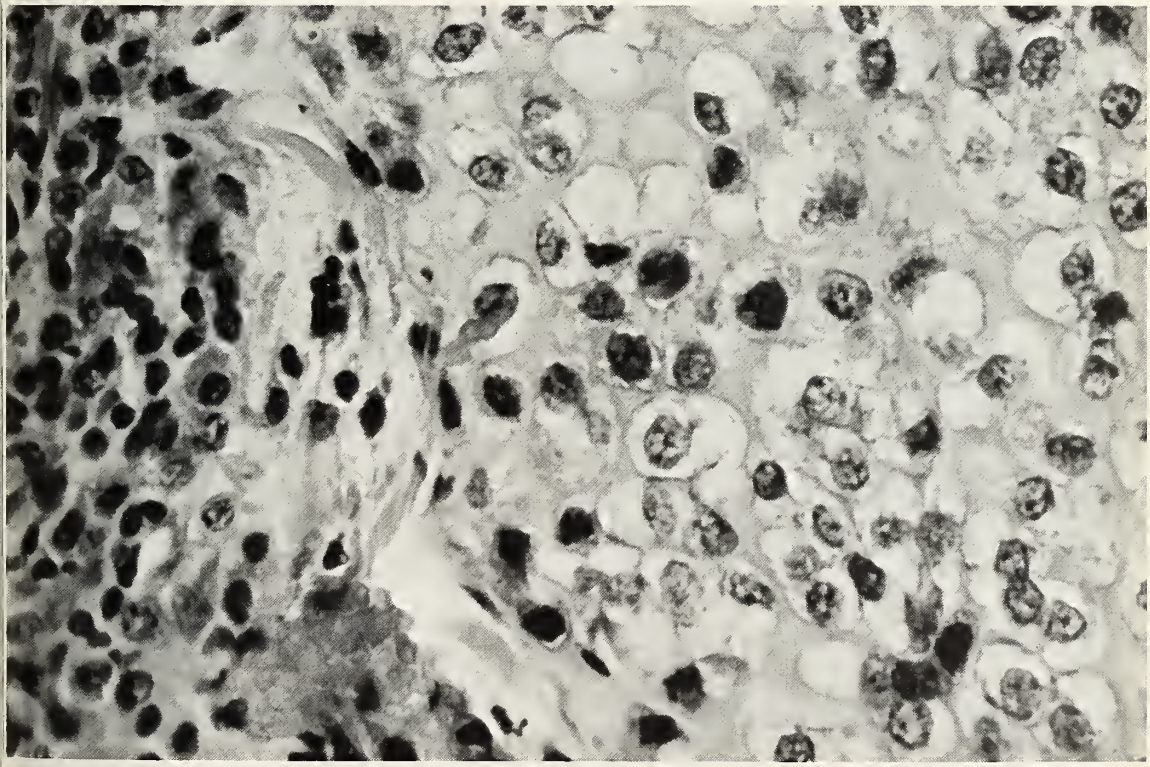

Fig. 80

PLATE I

CHONDROSARCOMA

(Plate I–A and figure 78 are from the same case)

A. Resected specimen of the third metacarpal from a 59-year-old woman. Nine months previously, because of pain in the area, biopsy had been taken and the tissue interpreted as enchondroma. When swelling recurred, amputation was performed.

In this sagittal section of the specimen, a cartilaginous tumor replaces marrow spaces, destroys cortex, and extends into soft tissues. Histologic examination of this specimen revealed chondrosarcoma (fig. 78). Sections from a second cartilaginous tumor in the proximal part of the metacarpal proved histologically benign. A. F. I. P. Acc. No. 218757–374.

B. Sagittal section through an acetabulum and surrounding soft tissues showing persistent chondrosarcoma. The patient, a 45-year-old woman, had had chondrosarcoma of the pubis resected six years previously. Two years later a persistent chondrosarcoma was resected from the pubic symphysis. Prior to the present hemipelvectomy, a mass in the inguinal region was present. A. F. I. P. Acc. No. 218757–375.

A

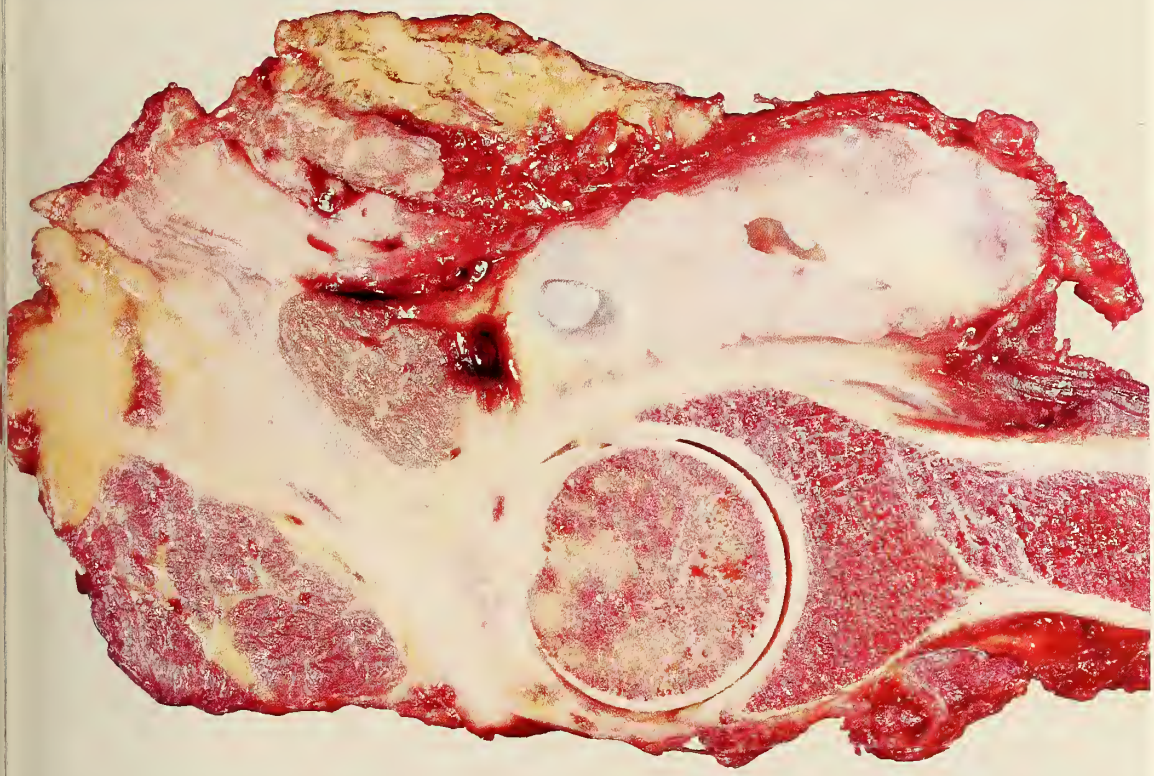

B

Plate I

Experience with chondrosarcoma of the rib cage has shown us numerous examples in which a cartilaginous tumor of a rib had recurred after the original tumor had been designated as benign. However, in each instance, review of the previous sections showed that this had been an error in microscopic interpretation. At the present time we know that if the primary lesion is in the rib, adequate resection of the tumor will result in cure in a high percentage of cases (O'Neal and Ackerman, 1951). Such resection always must include the tumor and underlying pleura and possibly other ribs.

In the pelvic area, even when the chondrosarcoma is extremely large, it may be cured by hemipelvectomy. This is one neoplasm that accounts for almost all successful hemipelvectomies. If the tumor is located in a long bone, amputation usually is indicated; only infrequently will it be possible to do block excision of a well localized tumor (figs. 62, 63).

References

Bennett, G. E., and Berkheimer, G. A. Malignant degeneration in a case of multiple benign exostoses. With a brief review of the literature. Surgery, 10:781–792, 1941.

Benson, W. R., and Bass, S., Jr. Chondromyxoid fibroma. First report of occurrence of this tumor in vertebral column. Am. J. Clin. Path., 25:1290–1292, 1955.

Buraczewski, J., Lysakowska, J., and Rudowski, W. Chondroblastoma (Codman's tumour) of the thoracic spine. J. Bone & Joint Surg., 39–B:705–710, 1957.

Codman, E. A. Epiphyseal chondromatous giant cell tumors of the upper end of the humerus. Surg., Gynec. & Obst., 52:543–548, 1931.

Coley, B. L., and Higinbotham, N. L. Tumors primary in the bones of the hands and feet. Surgery, 5:112–128, 1939.

———, and Higinbotham, N. L. The significance of cartilage in abnormal locations. Cancer, 2: 777–788, 1949.

———, and Higinbotham, N. L. Secondary chondrosarcoma. Ann. Surg., 139:547–559, 1954.

———, and Santoro, A. J. Benign central cartilaginous tumors of bone. Surgery, 22:411–423, 1947.

Copeland, M. M., and Geschickter, C. F. Chondroblastic tumors of bone: benign and malignant. Ann. Surg., 129:724–735, 1949.

Dahlin, D. C. Chondromyxoid fibroma of bone, with emphasis on its morphological relationship to benign chondroblastoma. Cancer, 9:195–203, 1956.

———. Bone Tumors. Osteochondroma (Osteocartilaginous Exostosis), pp. 14–21; Chondroma, pp. 22–29; Benign Chondroblastoma, pp. 30–37; Primary Chondrosarcoma, pp. 114–127. Springfield, Ill.: Charles C Thomas, 1957.

———, and Henderson, E. D. Chondrosarcoma, a surgical and pathological problem. Review of 212 cases. J. Bone & Joint Surg., 38–A:1025–1038, 1956.

Denko, J. V., and Krauel, L. H. Benign chondroblastoma of bone. An unusual localization in temporal bone. A.M.A. Arch. Path., 59:710–711, 1955.

Ewing, J. Neoplastic Diseases. A Treatise on Tumors, pp. 293–334. 3rd ed. Philadelphia & London: W. B. Saunders Co., 1928.

Fairbank, H. A. T. Dyschondroplasia. Synonyms—Ollier's disease, multiple enchondromata. J. Bone & Joint Surg., 30–B:689–708, 1948.

Fairbank, T. An Atlas of General Affections of the Skeleton, pp. 60–68. Baltimore: Williams & Wilkins Co.; Edinburgh & London: E. & S. Livingstone, Ltd., 1951.

Hadders, H. N., Donner, R., and Van Rijssel, T. G. Chondroblastoma benignum. Ned. tschr. geneesk., 100:2648–2652, 1956.

PLATE II

OSTEOCHONDROMA

(Plate II–A, B and figure 32 are from the same case)

A. Hemisection of an osteochondroma of the scapula from a 10-year-old boy. This is one of multiple osteochondromas of the patient. It had been gradually increasing in size over the past six months. Because of its size and roentgenographic characteristics, an en bloc excision was performed. Sagittal section of the amputation specimen shows a thick, lobulated cartilaginous cap.

The patient's father and brother also have multiple osteochondromas. W.U. 58–3161A; A. F. I. P. Acc. No. 218757–372.

B. Cross section of the tumor shows that the central portion is calcified and ossified. W.U. 58–3161; A. F. I. P. Acc. No. 218757–373.

OSTEOSARCOMA

C. Sagittal section through the right leg of a 56-year-old man demonstrates a hemorrhagic destructive lesion of the metaphysis and diaphysis of the distal tibia. Extensive hemorrhagic necrosis, destruction of medulla and cortex, and soft tissue extension can be noted. W.U. 47–508; A. F. I. P. Acc. No. 218757–376.

D. Sagittal section of an osteosarcoma of the distal portion of the femur from a 10-year-old girl. The patient had had pain in the right knee for five weeks, plus a gradually increasing tumor mass.

The lesion is partly sclerotic and necrotic, and there is destruction of the cortex. The epiphysial plate is spared. Soft tissue extension is evident and corresponds to the mass palpable prior to amputation. W.U. 55–2853; A. F. I. P. Acc. No. 218757–377.

RETICULUM CELL SARCOMA

E. Reticulum cell sarcoma of the distal portion of a fibula from a 13-year-old girl. Note irregular destruction of marrow space and cortex, with the large extraosseous component characteristic of reticulum cell sarcoma of bone. Hemorrhagic necrosis is also present.

The patient was treated with radiation therapy postoperatively and was known to be well four years after completion of therapy. (Courtesy of Dr. N. L. Higinbotham, New York, N.Y.) A. F. I .P. Acc. No. 218757–383.

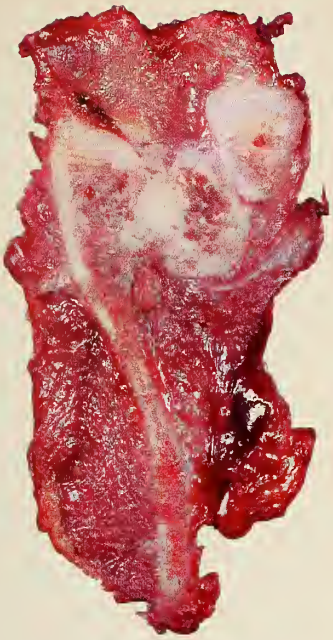

A

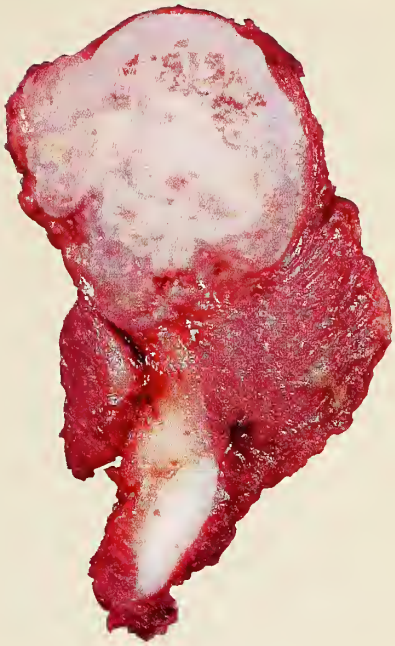

B

C

D

E

Plate II

Harsha, W. N. The natural history of osteocartilaginous exostoses (osteochondroma). Am. Surgeon, 20:65–72, 1954.

Heckman, J. A. Ollier's disease. A.M.A. Arch. Surg., 63:861–865, 1951.

Hunter, D., and Wiles, P. Dyschondroplasia (Ollier's disease): with report of a case. Brit. J. Surg., 22:507–519, 1925.

Jaffe, H. L. Hereditary multiple exostosis. Arch. Path., 36:335–357, 1943.

_____. Juxtacortical chondroma. Bull. Hosp. Joint Dis., 17:20–29, 1956.

_____, and Lichtenstein, L. Benign chondroblastoma of bone. A reinterpretation of the so-called calcifying or chondromatous giant cell tumor. Am. J. Path., 18:969–992, 1942.

_____, and Lichtenstein, L. Solitary benign enchondroma of bone. Arch. Surg., 46:480–493, 1943.

_____, and Lichtenstein, L. Chondromyxoid fibroma of bone. A distinctive benign tumor likely to be mistaken especially for chondrosarcoma. Arch. Path., 45:541–551, 1948.

Keith, A. Studies on the anatomical changes which accompany certain growth-disorders of the human body. J. Anat., 54:101–115, 1919-20.

Kunkel, M. G., Dahlin, D. C., and Young, H. H. Benign chondroblastoma. J. Bone & Joint Surg., 38–A:817–826, 1956.

Lansche, W. E., and Spjut, H. J. Chondrosarcoma of the small bones of the hand. J. Bone & Joint Surg., 40–A:1139–1145, 1958.

Laurence, W., and Franklin, E. L. Calcifying enchondroma of long bones. J. Bone & Joint Surg., 35–B:224–228, 1953.

Lichtenstein, L. Bone Tumors. Osteocartilaginous Exostosis (Osteochondroma), pp. 35–44; Benign Chondroblastoma of Bone, pp. 61–71; Chondromyxoid Fibroma of Bone, pp. 72–83. 2nd ed. St. Louis: C. V. Mosby Co., 1959.

———, and Hall, J. E. Periosteal chondroma. A distinctive benign cartilage tumor. J. Bone & Joint Surg., 34–A:691–697, 1952.

———, and Jaffe, H. L. Chondrosarcoma of bone. Am. J. Path., 19:553–589, 1943.

Ollier, M. Dyschondroplasie. Lyon méd., 93:23–24, 1900.

O'Neal, L. W., and Ackerman, L. V. Cartilaginous tumors of ribs and sternum. J. Thoracic Surg., 21:71–108, 1951.

———, and Ackerman, L. V. Chondrosarcoma of bone. Cancer, 5:551–577, 1952.

Oppenheim, J. M., and Boal, R. W. Benign chondroblastoma (Codman's tumor). Case report and review of literature. U.S. Armed Forces M. J., 6:279–282, 1955.

Plum, G. E., and Pugh, D. G. Roentgenologic aspects of benign chondroblastoma of bone. Am. J. Roentgenol., 79:584–591, 1958.

Posch, J. L. Tumors of the hand. J. Bone & Joint Surg., 38–A:517–540, 1956.

Shellito, J. G., and Dockerty, M. B. Cartilaginous tumors of the hand. Surg., Gynec. & Obst., 86:465–472, 1948.

Stout, A. P., and Verner, E. W. Chondrosarcoma of the extraskeletal soft tissues. Cancer, 6:581–590, 1953.

Thompson, V. P., and Steggall, C. T. Chondrosarcoma of the proximal portion of the femur treated by resection and bone replacement. A six-year result. J. Bone & Joint Surg., 38–A:357–367, 1956.

Tiwisina, T. Dyschondroplasie (Ollier) mit multiplen Haemangiomen und örtlicher maligner Entartung (Chondrosarkom). Beitr. klin. Chir., 188:8–15, 1954.

Valls, J., Ottolenghi, C. E., and Schajowicz, F. Epiphyseal chondroblastoma of bone. J. Bone & Joint Surg., 33–A:997–1009, 1951.

Willis, R. A. The pathology of osteoclastoma or giant-cell tumour of bone. J. Bone & Joint Surg., 31–B:236–240, 1949.

Flaherty et al.). The nidus is friable, red to red-gray, soft, discrete, and rounded. Frequently it becomes readily dislodged from surrounding sclerotic bone. Its consistency varies; if heavily calcified, it is firm or hard.

If sclerosis is sufficiently excessive to obscure the small nidus, a roentgenogram of the excised specimen may be helpful in gaining assurance that the tumor has been removed completely.

Multiple osteoid osteomas have not been reported. However, Sherman reports one case, occurring in a tibial epiphysis, which had three nidi adjacent to one another.

MICROSCOPIC. The nidus is the center of histologic attraction (fig. 87). It is formed by a maze of closely situated osteoid trabeculae that set it off from surrounding sclerotic bone. The trabeculae vary in thickness; their boundaries are irregular and often are outlined by osteoblasts (figs. 88, 89). Portions of the trabeculae are only osteoid, seemingly free of calcium deposition; commonly, cement lines and small calcific deposits are observed, but cartilage is not present. The center of the nidus is generally the site of most pronounced calcification with less or none noted peripherally. Vascularity of the nidus has been well demonstrated by angiography (fig. 84; Lindbom et al.); "younger" lesions are said to be the most vascular. The intertrabecular tissue is also frequently highly vascular (fig. 90). Blood vessels are thin-walled, small, and congested (figs. 92, 93). Surrounding connective tissue consists of fibroblasts; osteoblasts also seem to spring from the connective tissue. Multinucleated giant cells, probably osteoclasts, are present (fig. 91). Hematopoietic elements and marrow fat are not seen. Scattered lymphocytes and plasma cells occasionally have been noted.

Adjacent bone is characteristically sclerotic, with the exceptions previously noted. Thickened trabeculae are usually well oriented in contrast to those of the disorganized pattern of the nidus. Intertrabecular spaces are narrowed and contain fibrous tissue and few blood vessels. The periosteum is not remarkable except for fibrous thickening.

TREATMENT. The most successful method of treatment is by en bloc excision. If the nidus is incompletely removed by curettage, symptoms and roentgenographic evidence of the lesion may reappear. Only rare cases of osteoid osteoma have been treated by roentgen ray therapy.

Jaffe (1953) reported a case of a 15-year-old boy who had received 10 roentgen ray treatments to an osteoid osteoma of the humerus; these treatments consisted of 200 r each and extended over a period of a year. Pain was relieved for three years. The lesion was excised one year after pain had recurred. It was histologically confirmed as an osteoid osteoma. During the entire course of these five years, the nidus remained visible.

Stauffer also reported a case of an osteoid osteoma of the head of the radius treated with roentgenographic therapy to a total dose of 1,575 r. Pain and the nidus persisted; the lesion was excised for histologic confirmation.

Since the tumor invariably is treated after diagnosis has been made, the eventual fate of an untreated osteoid osteoma is not definitely known. By study of interval radiographs, some information regarding growth and fate of the nidus has been obtained (Freiberger et al.). Roentgenographic correlation of this material with the pathology suggests that the more radiolucent nidus is the fully developed stage, whereas an opaque nidus is the earlier phase of tumor development. It also confirms the observation that osteoid osteomas with roentgenographic evidence of calcification usually are of shorter clinical duration than those apparently free of calcification. However, it failed to find any apparent correlation between the degree of sclerosis about the nidus and the duration of symptoms.

Patients followed by these roentgenographic examinations have had varied courses: one patient followed for six years had complete regression of symptoms, although the nidus remained visible (Golding). In some patients the nidus even increased in size (Moberg). In others an increase of severity of symptoms was noted, but roentgenographic findings for the tumor remained unchanged (Flaherty et al.).

Osteoblastoma

SYNONYMS AND RELATED TERMS: Giant osteoid osteoma; osteogenic fibroma.

As the synonym "giant osteoid osteoma" suggests, the tumor is clinically and pathologically similar to osteoid osteoma. However, sufficient differences exist for us to prefer the less confusing, though not entirely satisfactory name, "osteoblastoma."

DEFINITION. An uncommon solitary, benign osteoblastic tumor which most often involves vertebrae and long bones of the extremities.

CLINICAL DATA. Pain in the region of the lesion is the major complaint. Although it is not so characteristically more severe at night or relieved by aspirin as the pain of osteoid osteoma, it is comparable in that slight tenderness and swelling are usually present over the lesion and in that symptoms may be present from a few weeks to as long as five years.

Lichtenstein (1956) noted no sex predilection for benign osteoblastoma; whereas 10 of 11 patients of Dahlin and Johnson were men, Jaffe (1958) noted higher incidence of the tumor in women.

The majority of patients having this tumor are above 10 or below 35 years of age, with an age range of 5 to 60 years.

Although roentgenograms are most often interpreted as osteomyelitis or osseous tumor and destruction is frequently demonstrated, the lesion remains fairly well circumscribed and does not commonly provoke the extensive sclerosis of bone which accompanies osteoid osteomas (figs. 94, 96). Roentgenograms, as well as a few intact gross specimens, demonstrate that many but not all osteoblastomas are associated with a zone of sclerotic bone about the lesion. Nor

is the zone of sclerotic bone, when present, as pronounced as that associated with osteoid osteoma (Lichtenstein, 1959). However, the periosteum may be thickened. A few tumors also have been reported as destructive and expansile. In long bones, either the metaphysis or the diaphysis may be involved. Where vertebrae are affected, neural arches, spinous processes, and bodies of these bones are sites for tumor.

Laboratory findings are not rewarding.

SITES OF TUMOR. Osteoblastoma has been reported as occurring in many different bones (figs. 94, 95). Combining data on sites of tumor from the four major reports (Dahlin and Johnson; Lichtenstein; Dahlin; Jaffe, 1958) with one case sent to us by Uehlinger, the lesion has been noted in: vertebrae, 11 cases; femur and tibia, each 6 cases; sacrum, 4 cases; temporal bone, 3 cases; humerus, 2 cases; rib, 2 cases; and radius, metacarpal, scapula, patella, metatarsal, and talus, each 1 case. However, since Jaffe did not tabulate all of his cases, the totals are incomplete.

GROSS. In contrast to the small size of osteoid osteoma, an osteoblastoma may measure from 2 to 10 cm. in diameter. It is hemorrhagic, granular, friable, and demarcated from surrounding normal or sclerotic bone (figs. 95–97). Its color varies from red to a purplish hue to gray-brown. Evidence of excessive bleeding having occurred during surgery is also a gross feature of the tumor (Dahlin and Johnson).

MICROSCOPIC. The lesion may be histologically confused with giant cell tumor of bone or osteosarcoma (fig. 100), because of its osteoid formation and cellularity. The latter includes osteoblasts and multinucleated giant cells, probably osteoclasts. The abundant osteoid, exhibiting varied quantities of calcium, also bears resemblance to osteoid osteoma (figs. 98, 99). Osteoblasts are abundant and closely allied to the osteoid trabeculae. However, Dahlin and Johnson noted that the trabeculae are broader, more widely spaced, and longer than those of osteoid osteoma. Intertrabecular tissues are highly vascular and contain numerous dilated, thin-walled capillaries. Therefore, extravasated blood may be present. Fibrous tissue is present but not predominant.

Careful attention to benign characteristics of histologic detail of various components of the tumor, particularly in more cellular areas, will reduce the risk of calling this lesion malignant.

TREATMENT. Since the lesion is benign, treatment should be conservative. Therapy of choice consists of curettement, or conservative excision where anatomically possible. Conservative types of therapy have arrested clinical progression of the lesion, with follow-up data confirming the benign character of the tumor.

A few cases have been treated by curettement and postoperative irradiation, because of histologic confusion of this tumor with osteosarcoma or giant cell tumor. A case was reported by Jaffe (1956) in which the lesion was par-

tially curetted and the area then irradiated. The lesion became radiopaque within six months.

Eventual outcome of untreated benign osteoblastoma can only be surmised on the basis of one of the cases of Lichtenstein (1956). In this instance, only partial removal of a lesion of a tibia was done because of uncertainty of the nature of the tumor. Radiographs taken 14 months later demonstrated no increase in size of the lesion but showed actual reconstruction of the cortical defect.

Osteosarcoma

SYNONYMS AND RELATED TERMS: Osteogenic sarcoma.

INCIDENCE. Osteosarcomas occur in a high percentage of instances in the metaphysial areas of long bones: most commonly in the lower femur, upper tibia or femur, and upper humerus; in fact, they occur in almost every bone of the body (pl. II–C, D). Coventry and Dahlin reported 430 cases of osteosarcoma, of which 233 involved either the proximal portion of the tibia or the distal portion of the femur. Multiple independent osteosarcomas have been reported (Finlayson; Lichtenstein, 1959).

CLINICAL DATA. These rare malignant tumors occur more commonly in men (about 60 percent) than in women. They can appear at almost any age but are seen more frequently in the second decade. They are also quite common in the third and fourth decades; in the later decades men predominate, probably because of concomitant Paget's disease.

PATHOGENESIS. Whether osteosarcoma evolves from a "primitive mesenchyme" or mature bone components is conjectural. Since its cellular elements commonly show areas of malignant osteoid, cartilage, and stroma, the combination of patterns rather than pure development of one of the elements justifies its discussion as an entity. Therefore, tumors almost exclusively of cartilage (chondrosarcomas) and tumors exclusively of neoplastic fibrous tissue (fibrosarcomas) must be excluded from this section; neither are we concerned here with rare osteosarcomas occurring in soft tissues (Fine and Stout).

Osteosarcomas have been and are often designated as osteogenic sarcomas; complicated classifications also have been used to indicate the different types: sclerosing, osteolytic, medullary, subperiosteal, and periosteal. Such distinctive designations are completely artificial and are often based on radiographic and/or gross appearance. Multiple or large sections of an osteosarcoma often show one type of tissue or pattern blending into another.

GROSS. These tumors present variable amounts of cartilaginous, fibroblastic, or bone-producing zones. If an osteosarcoma is highly vascular with little cartilage, osteoid, or bone formation, then grossly it will be extremely hemorrhagic and often show large zones of bone destruction, with destruction of the cortex (fig. 101) and extension of highly vascularized tumor tissue into surrounding soft tissues (figs. 102–104). If cartilage predominates, then some-

what opalescent bluish gray glistening zones may prevail. If osteoid and bone predominate (figs. 103, 104), the tumor is hard and often forms a well delimited mass which may extend through the cortex into soft tissues. If the tumor is predominantly osteolytic, fractures of weight-bearing bones may occur; this may complicate the microscopic pattern because of attempted repair of the fracture. These malignant neoplasms practically never involve the joint space, unless they reach it by extension through the cortex and then spread around the end of the bone to involve the joint space itself. Such unusual involvement may be facilitated by fracture.

It is common for these tumors to produce a Codman's triangle which is due to elevation of the periosteum, with reactive bone stimulated by the advancing tumor (fig. 107). Extension of osteosarcoma through the epiphysial plate in young patients is uncommon but is not always blocked by cartilage (figs. 109, 110). This finding is particularly well seen in lesions of the tibia and femur where the tumor advances to the epiphysis and then does not extend beyond it. The tumor also extends up or down the shaft, usually for short distances; discontinuous involvement of the marrow cavity is unusual. The tumor can extend far enough into soft tissues to put the skin under tension, but ulceration through the skin, except following biopsy, is unusual in our experience.

MICROSCOPIC. Classic osteosarcoma is not difficult to diagnose, for neoplastic osteoid is invariably present (figs. 111, 112) and grows directly out of a sarcomatous stroma. Tumor cells vary greatly in size, shape, and nuclear pattern (figs. 113, 114). Giant atypical mitotic figures are frequently observed.

Multiple sections from an osteosarcoma may show many patterns (figs. 117–121) and may reveal zones of neoplastic cartilage comparable to that seen in pure chondrosarcomas (fig. 108). Individual cartilage cells present multiple, plump, and atypical nuclei, or even mitotic figures (figs. 107, 108). There also may be areas of indolent growth in which the tumor is producing fairly well oriented and organized bone (fig. 115). In such instances, attention of the pathologist must be directed toward stromal alterations.

In highly vascular tumors it may be difficult to make a diagnosis of osteosarcoma, unless attention is also paid to the radiographic pattern of an osteolytic lesion showing extreme destruction of bone in a metaphysial area. In such vascular osteosarcomas there is extreme variation of pattern, with innumerable atypical forms and vascular channels lined by malignant cells (fig. 116).

It is not too rare to find zones within an osteosarcoma where there are veritable islands of giant cells similar to those observed in a giant cell tumor. However, if roentgenographic and pathologic studies are thorough, osteosarcoma should not be confused with giant cell tumor of bone.

SPREAD OF TUMOR. Distant spread of osteosarcoma is almost exclusively through the blood stream, although in a rare instance we have seen

direct invasion of lymph nodes by tumor, or even distant metastases (figs. 122, 123). Because of the highly vascular zone in which these tumors are growing and because of their ability to invade vascular channels, tumor spreads quickly to the lung. By radiographic examination, such metastases can often be demonstrated to contain bone. Under even more exceptional circumstances, such metastases may undergo bony maturation and arrest.

TREATMENT. Radiation therapy of these tumors generally has not proved effective, even though Cade has described long term survivors and Tudway believes that preoperative irradiation in well differentiated osteosarcomas is of value.

An almost exclusive surgical approach to these tumors is indicated. The level of amputation recommended is through bone above the affected area; this may be modified, particularly for distal lesions of the femur where it has not been proved whether this high amputation is less desirable than disarticulation. Without disarticulation, particularly in the diaphysial lesion, there is some risk of local persistence of sarcoma in the remaining stump. Cure rate for osteosarcoma has always been reported at dismally low levels. Recent follow-up of patients treated at Mayo Clinic, however, introduces a note of optimism. Dahlin divided his group into osteoblastic, chondroblastic, and fibroblastic types. The five year survival rates were 15.6 percent, 22.7 percent, and 22.9 percent respectively, survival rates for young patients being somewhat better than for older ones. Particularly striking is the 34.6 percent five year survival rate of patients with osteosarcoma of the tibia compared with 17 percent for those with osteosarcoma of the femur (Coventry and Dahlin). One of us (L.V.A.) reviewed these cases in sequence and found no reason to disagree with the diagnoses. Although grading of these tumors does not seem valuable to us, other authors, such as Price, disagree with our impression.

Of 41 patients with osteosarcoma (excluding parosteal sarcoma) at our institution, seven (17.1 percent) are living without evidence of disease five or more years after surgery (Lansche). In Sweden a similar survival rate was noted among 96 patients with osteosarcomas; 16 of 84 patients (19 percent) eligible for five year follow-up survived five or more years (Lindbom et al., 1960). We even have seen a few cures following removal of a single metastasis from the lung of a patient who had previously had an amputation.

Parosteal sarcoma is a rare low grade variant of osteosarcoma, with good prognosis and sufficiently distinctive clinical, radiographic (figs. 129, 130), and pathologic features to warrant discussion of it as an entity.

In the past, unfortunately, this malignant neoplasm has been confused with myositis ossificans, a lesion to which it bears no relationship. This impression is well supported by clinical findings, roentgenograms, gross appearance, and the microscopic patterns of individual cases reported as "A study of an unusual case of myositis ossificans" (Paul), as Case II in the article of Coley, and as "Myositis ossificans. A study of another unusual case" (Cham-

bers). These three cases have been résuméd (Geschickter and Copeland). The tumor, on occasion, further has been termed an atypical myositis ossificans or described as atypical bone or cartilage formation. Other terms which more frequently have been applied to this tumor are chronic formative osteitis, parosteal juxtacortical osteogenic sarcoma (Jaffe and Selin), and parosteal osteoma. However, the suggestion is made that the term parosteal osteoma be abandoned to avoid the implication that this is a benign neoplasm.

Dwinnell and associates, in reviewing 400 cases of osteosarcoma, found 15 cases which they identified as parosteal sarcoma. Ten of these cases involved the distal portion of the femur, and five involved the humerus and tibia. In one case (figs. 124, 125) the tumor had been present for at least seven years without involvement of the marrow cavity. This case would support the fact that the tumor has long clinical duration.

Grossly, in certain cases the tumor tends to surround the bone and completely envelop it (fig. 128). These lesions form large, irregular, bosselated, firm masses which are in intimate association with the periosteum and cortex. Destruction of the cortex may be present, and the lesion may extend to involve the marrow cavity. Cartilage can be identified as being interspersed between the disturbed bony pattern, but the bony component predominates. Reactive periosteal bone formation is uncommon, however, and occasionally muscle may enter the tumor.

Microscopically, this is a very difficult lesion to identify. If multiple biopsies are taken or multiple sections made, there may be wide zones in which bone and osteoid will be well oriented; the osteoid also may show calcification. Therefore, it will be difficult, if not impossible, to designate the tumor as malignant. In the islands of cartilage, there may be zones compatible with chondrosarcoma (Dwinnell et al.). There are other areas, too, in which the malignant quality of this tumor can be identified by seeing obviously malignant zones evolving from a sarcomatous stroma (figs. 126, 127, 132).

Although it is possible that in a few locations the tumor could be treated by adequate local excision, amputation in most instances is the treatment of choice.

Sarcoma arising in Paget's disease of bone is predominantly an osteosarcoma, although rare chondrosarcomas, fibrosarcomas, and giant cell tumors have been reported (Summey and Pressly; Goldenberg; Snapper). The reason for this malignant transformation remains unknown, but it is suggested that the extreme stromal activity accompanying Paget's disease may serve as its focus.

Incidence of this complication is difficult to determine, even though Paget's disease of bone per se has been well described by many authors (Jaffe, 1933; Goldenberg; Rosenkrantz et al.). The figure varies and ranges from 1 to 11 percent, according to the method of determination used. Based on the number of sarcomas detected in a group of patients with clinically diagnosed Paget's

disease, these figures are probably too high. Specifically, for instance, sarcoma was present in 16 of 1,753 patients (0.9 percent) with Paget's disease (Porretta et al.). Since follow-up reports were not available on all patients, however, this incidence was not exact. Exactness of incidence further is complicated by subclinical or clinically undetected Paget's disease which occurs in a fairly high percentage of carefully studied autopsies. In one study of autopsy material, an incidence of 3.7 percent of previously undetected Paget's disease was discovered (Collins), thus making it a fairly common disease of bone when specially sought (figs. 137, 138).

Sarcoma is more commonly seen in polyostotic Paget's disease of bone than in its monostotic form. In long bones it is commoner in the midshaft than an osteosarcoma unrelated to Paget's disease (Sherman and Soong). Most bones of the body are known to have been affected, except small bones of the hands and feet. The commonest sites, however, are the skull, humerus, scapula, pelvis, femur, and tibia (figs. 133, 134). Twenty-one percent of a collected group of sarcomas from these sites was considered multicentric (Porretta et al.).

Sarcomas complicating Paget's disease of bone are usually seen in older individuals, particularly in patients over 50 years of age. Coley and Sharp stated that 60 percent of patients in this age group with osteosarcomas of the humerus, tibia, or ilium have had pre-existing Paget's disease, and that 100 percent of patients in this age group with osteosarcomas of the skull have had pre-existing Paget's disease.

In uncomplicated Paget's disease of bone, 65 percent of patients were men and 35 percent were women; when sarcoma complicated Paget's disease, however, the sex distribution was 84 percent men and 16 percent women (Summey and Pressly).

It has been estimated that the duration of Paget's disease of bone varies from 10 to 15 years (Coley and Sharp). However, duration of this disease is difficult to determine prior to discovery of malignant transformation, because many cases of Paget's disease are discovered only through routine roentgenographic examinations.

Detection of sarcomatous transformation in Paget's disease of bone is difficult roentgenographically as well as clinically, except that often the first manifestation of the disease is pathologic fracture. Sherman and Soong have warned that fractures occurring in patients having Paget's disease should be carefully studied in order to rule out the possibility of underlying malignant neoplasm. Their earliest roentgenographic finding of a malignant lesion in the disease was a small area of destruction in the subcortical portion of a bone.

Clinically, constant pain in the affected bone may be a sign of development of a malignant lesion, particularly if the pain is not relieved by rest. In fact, rather severe localized pain was the chief complaint of almost all patients studied by Porretta and associates. Although a palpable mass at the site of the lesion is noted in most patients, Sherman and Soong described

a pulsating mass as being an important clinical feature of the disease in cranial bones. As would be expected, alkaline phosphatase is usually elevated in this disease process.

Sarcomas arising in Paget's disease have similar gross characteristics to those arising in bones free of Paget's disease. In nonmalignant areas, the bone maintains characteristics and deformities of Paget's disease (figs. 135, 136). There is usually an associated thickening and an apparent porosity of the cortex; islands of sclerotic bone in the medullary cavity with areas of hemorrhage and occasional cyst formation may be seen. In fact, irregular islands of thickened trabeculae may be quite prominent (figs. 139, 140). Fibrosis in the surrounding Paget's area also may be noted. Periosteal reaction is less common than in sarcomas arising in bones not affected by Paget's disease. While soft tissue extension of the tumor may occur, it is uncommon for the joint to be invaded (fig. 144).

Histologic characteristics of sarcomas arising in Paget's disease of bone are also similar to those features expected when the lesion arises de novo (figs. 142, 143, 145, 146). Surrounding bone usually shows the characteristic pattern associated with Paget's disease (fig. 141).

Prognosis of sarcomas arising in Paget's disease is extremely poor, since growth rate of the lesion seems faster than in uncomplicated osteosarcoma. Numbers of these patients have multiple sites of involvement, and the tumor metastasizes to the lung in most cases. Most authors state that they know of no cure. However, Sherman and Soong reported one patient treated by radiation therapy who survived five years and then died of heart disease. Other single cases of survival beyond five years also have been recorded (Cowie et al.; Stevens and Lennox).

Sarcoma arising in irradiated bones is a well established entity clinically and experimentally. Attention was initially directed to this complication, induced with roentgen ray therapy, by a report from Beck in 1922. Sarcoma from exposure to radioactive materials was first reported by Martland and Humphries in 1929 with two cases: (1) histologically proved osteosarcoma of the scapula eight years after exposure to luminous paint; (2) histologically unproved, but with clinical and radiographic evidence of osteosarcoma of the femur. These cases represented 15 patients who died following the use of radium and radiomesothorium for painting luminous watch dials, a process which began in America in 1914.

Between the years 1915 and 1930, radium salts were given intravenously and orally for hypertension, arthritis, anemia, and other conditions. More recently the effects of radium and radium salts have been thoroughly investigated (Aub et al.; Looney et al.). While it generally may be said that those patients who had had large amounts of radium had more severe disease than those who had had small amounts, and that some direct correlation exists between the amounts of radium received and ill effects noted, these authors

feel that there is no constant correlation between the amount of body radium content and induction of tumor or severity of disease.

Of 4 of the patients described by Looney and associates, 2 had subsequently developed sarcomas of bone following therapeutic administration of radium salts and 2 following ingestion of the radium salts used in painting watch dials. Total body burdens of radium salts of these cases were 0.86μg. and 1.3μg. respectively, and 0.56μg. and 1.3μg. respectively (figs. 154–157). Each of these patients, in addition to malignant neoplasms, had radiographic changes in bones reportedly characteristic of chronic effects of radium salt deposition. When death occurred, it resulted from malignant tumors of the skeleton, anemias, crippling bone lesions, or combinations of factors.

Comparatively few of the estimated 2,000 luminous watch-dial painters and the hundreds, or perhaps thousands, of those who received radium salts have been available for study. A need to further investigate persons in these categories for chronic effects from radioactive materials is indicated to determine also the dangers of fallout from nuclear weapons; however, whereabouts of these patients is essentially unknown (Clark).

The amount of irradiation necessary to induce sarcoma of bone is variable. In roentgen ray therapy, the necessary dose is usually considered as 3,000 r or more; however, cases have been recorded in which sarcoma has apparently been induced by much less than 3,000 r.

Cruz and associates (p. 72) have set forth these criteria to qualify a case as an irradiation induced sarcoma:

"1. Microscopic or roentgenographic evidence of the benignancy of the primary condition.

2. Irradiation in any of its forms must have been given and the sarcoma that later developed must have arisen in the area included within the radiotherapeutic beam.

3. A relatively long symptom-free latent period.

4. All the sarcomas should be proved histologically."

The majority of sarcomas arising secondary to roentgen ray therapy have occurred in the femur and tibia. Others have been reported in the mandible, bones of upper extremities, rib irradiated for carcinoma of the breast, scapula, and in one case (Cruz et al.) a phalanx. In reviewing similar cases, we noted that in many instances radiation therapy had been given to lesions which later were thought to have been initially benign, e.g. osteoid osteomas, fibrous dysplasias, aneurysmal and other bone cysts, chondroblastomas, inflammatory lesions, and giant cell tumors (figs. 157, 158). Giant cell tumors commonly receive radiation therapy. A report from the Mayo Clinic stated that 9 of 17 postradiation sarcomas of bone arose after irradiation of giant cell tumors (Sabanas et al.), while 22 similar cases reported from the Memorial Center for Cancer and Allied Diseases, New York City, included 5 such sarcomas. Sabanas and associates also recorded a case of osteosarcoma of the clavicle,

IRRADIATION INDUCED MALIGNANT TUMOR SITES INGESTION OF RADIUM AND RADIUM SALTS

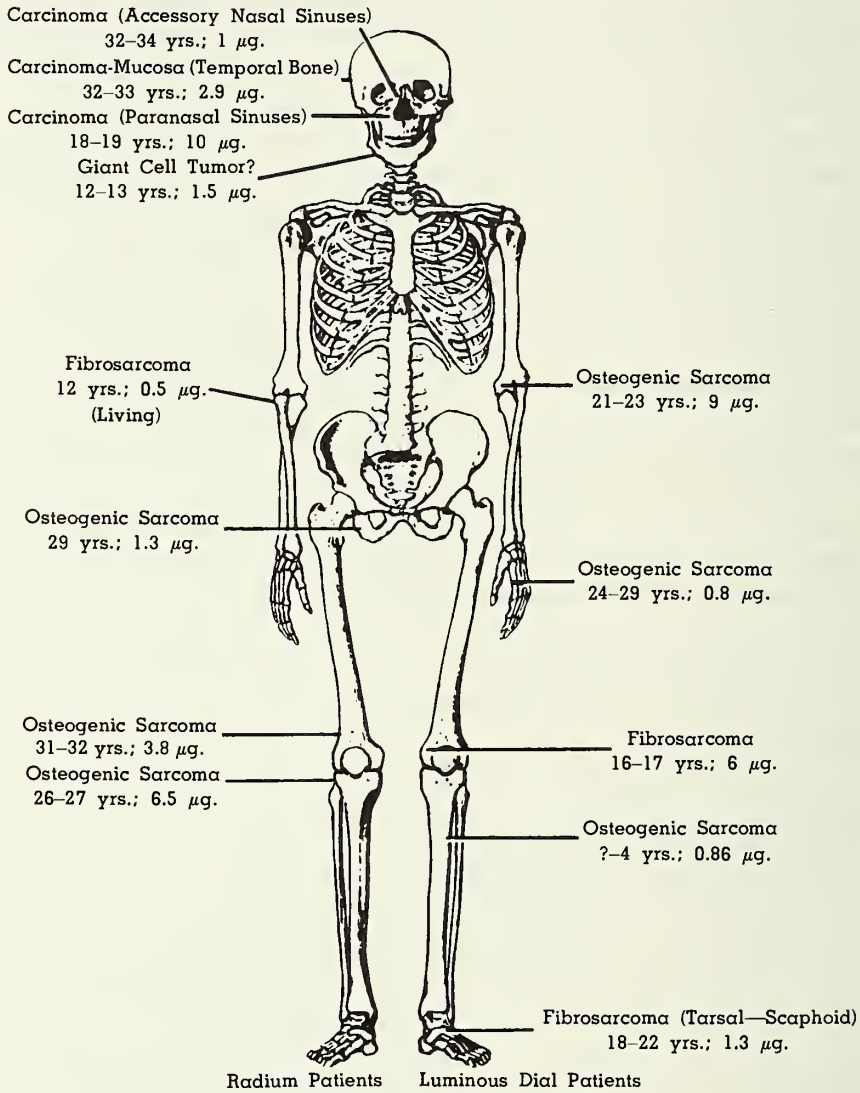

Adapted from figure 19 in Looney, W. B. II. Late effects (twenty-five to forty years) of the early medical and industrial use of radioactive materials. J. Bone & Joint Surg., 38–A: 175–218, 1956.

sternum, and first rib, following radiation therapy of a nevus of the neck. They further recorded a case of an osteogenic sarcoma of the mandible following radiation therapy for keloids of the face and neck, which had a latent period of 21 years. These cases, with the osteosarcoma of the vertebra following roentgen therapy to the retroperitoneal area for seminoma, serve to illustrate that apparently normal bones within the beam of therapeutically administered

irradiation are susceptible to sarcomatous transformation. A report of an earlier group of cases (Cahan et al.) indicated that tuberculosis, particularly of the knee joint, rather than giant cell tumor had been the common benign lesion which had been irradiated prior to the appearance of a sarcoma.

Sex distribution for sarcomas induced by irradiation is found almost equally divided between men and women, while ages range from 11 to over 60 years of age.

It was postulated by Looney and Woodruff that macroscopic areas of destruction occurred as a result of fusion of adjacent central canals of haversian systems which had undergone destructive changes. When repair maintained pace with destruction, radiographic changes were not apparent, but imbalance of these processes produced radiolucent foci, such as "punched-out" areas in the skull, or radiodense foci as seen in cortical areas of long bones.

Genesis of the changes seen in bones after deposition of radium or radium salts has been partially clarified by use of autoradiographs (Looney and Woodruff). By this method, distribution and concentration of radium were observed and found irregular. Heavy, rather uniform concentrations of radium were present at the junction of articular cartilage with trabeculae of the long bones. In compact bone, however, only a small percentage of haversian systems and interstitial lamellae had appreciable concentrations. Most important, diagnostically, was the formation of an atypical osseous tissue in the trabecular spaces of cancellous bone, associated with areas of destruction in compact bone. Areas of destroyed, or "dead," bone often were found associated with areas of bone formation, since bone regeneration was at a rather low level. The zones of destroyed bone often were replaced by fibrous connective tissue. Aseptic necrosis also appeared, particularly in the mandible, heads of femora, and bones of feet.

Grossly these tumors are not unlike sarcomas arising de novo in bone (figs. 154–156).

Histologically, the majority are osteosarcomas or fibrosarcomas, although chondrosarcomas have been reported (Hatcher). Cruz and associates studied changes in bone in patients who had developed postradiation bone sarcoma. They emphasized the patchy nature of the changes and the fact that badly damaged bone often was interspersed through intact bone. They noted that marrow was also damaged and reduced to a poorly cellular, hyaline, relatively avascular, connective tissue with foci of fat necrosis. They illustrated solitary, large connective tissue cells like those seen in skin badly damaged by radiation. Therefore, they believe that sarcomatous changes occur in areas of intermediate damage, whereas more heavily damaged areas even lack recuperative power. We fortunately obtained the blocks of tissue which illustrate the changes described in figures 18 to 22 of their paper. From these, we have made new photomicrographic slides (figs. 150–153).

OSTEOID OSTEOMA

(Figures 82 and 83 are from the same case)

Figure 81. Roentgenogram showing an irregularly rounded nidus in an astragulus. An indistinct zone of bony sclerosis surrounds it. The 11-year-old patient had had pain characteristic of osteoid osteoma for 11 months prior to treatment, but there had been no signs or symptoms suggesting infection. W.U. 48-3921; A. F. I. P. Acc. No. 218757-143.

Figure 82. Typical roentgenographic configuration of an osteoid osteoma. The nidus is seen as a rounded radiolucent area surrounded by sclerotic bone. Periosteal bone reaction is also present. W.U. 55-6099; A. F. I. P. Acc. No. 218757-142.

Figure 83. This whole mount section of the tumor demonstrates cortical bone with intact nidus. Periphery of the nidus is vascular, and surrounding cortical bone is sclerotic. The lesion is from a femur of a 22-year-old man, who had characteristic night pain that was relieved by aspirin. Hematoxylin and eosin stain. X 10. B.H. 55-3449; A. F. I. P. Acc. No. 218757-141.

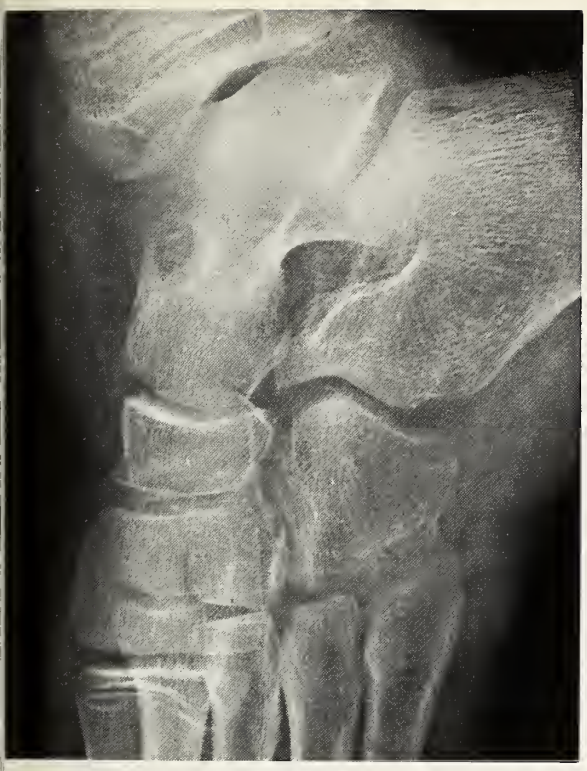

Fig. 81

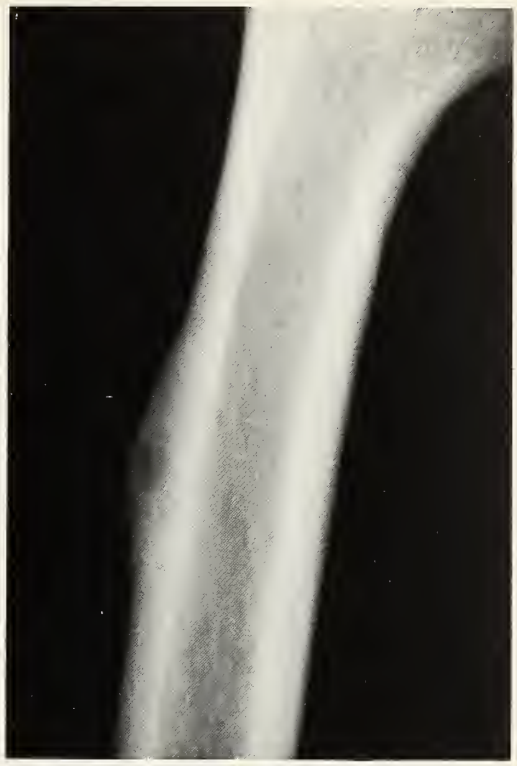

Fig. 82

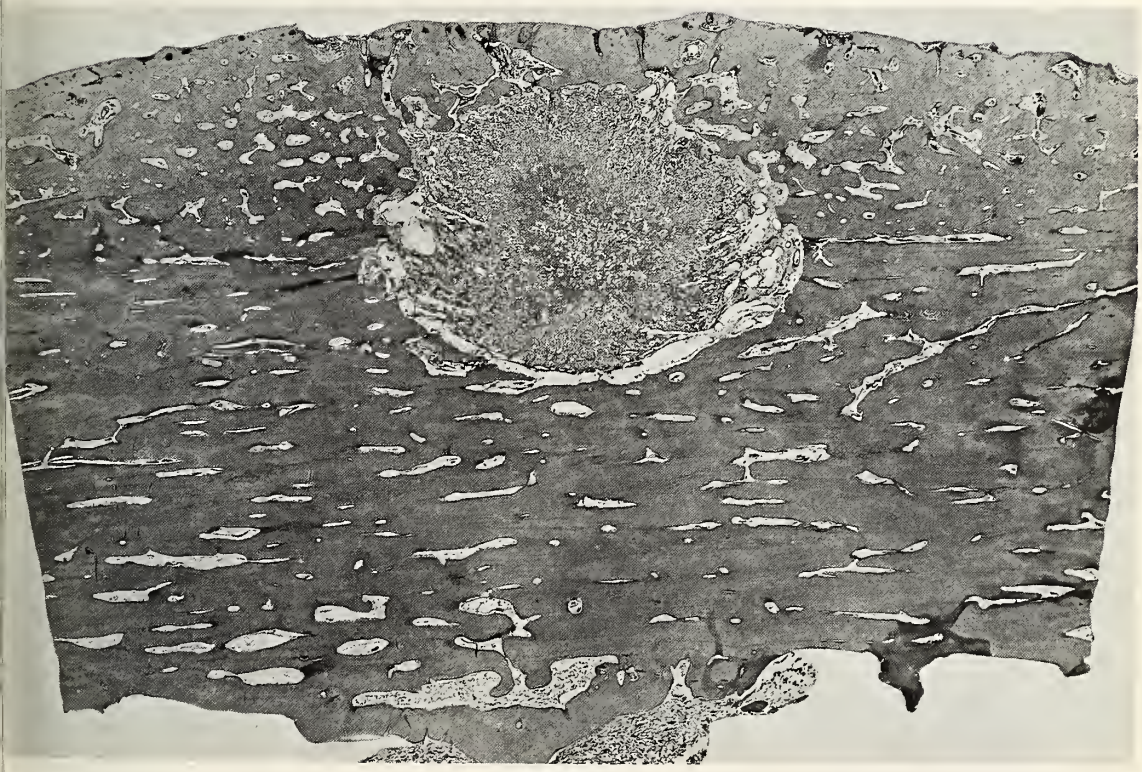

Fig. 83

OSTEOID OSTEOMA

Figure 84. Arteriogram of an osteoid osteoma of the ulna showing (1) the nidus as a radiolucent area before dye has arrived (left), followed by (2) opacification of nidus by dye in arterial phase (center), demonstrating that at least part of the blood supply of the nidus comes from the interosseous artery and (3) opacification of dye in venous phase (right). The halo around the opacified nidus has been seen in arteriograms of other osteoid osteomas. (Courtesy of Dr. Å. Lindbom, Stockholm, Sweden.) A. F. I. P. Acc. No. 218757–393.

Figure 85. Roentgenogram shows cortical thickening secondary to chronic osteomyelitis in a 42-year-old white woman. The pyogenic process is seen in the subperiosteal area. A single symptom was pain, relieved by aspirin. W.U. 59–6880; A. F. I. P. Acc. No. 218757–392.

Figure 86. Roentgenogram of a tibial lesion histologically proved a focus of osteomyelitis. However, its radiographic features were those of cortical osteoid osteoma, as seen. (This is figure 23 in Goidanich, I. F., and Zanasi, R. Osteoma osteoide ed Osteomielite sclerosante: due entità cliniche definite e distinte. Chir. org. movim., 43:427–460, 1956.) A. F. I. P. Acc. No. 218757–339.

Figure 87. This histologic section demonstrates the vascularity, irregular bony trabeculae, and increased fibrous component of an intact nidus. In contrast to the typical structure of most osteoid osteomas (fig. 83), surrounding bone of this nidus is not sclerotic. Hematoxylin and eosin stain. X 15. W.U. 54–5990; A. F. I. P. Acc. No. 218757–144.

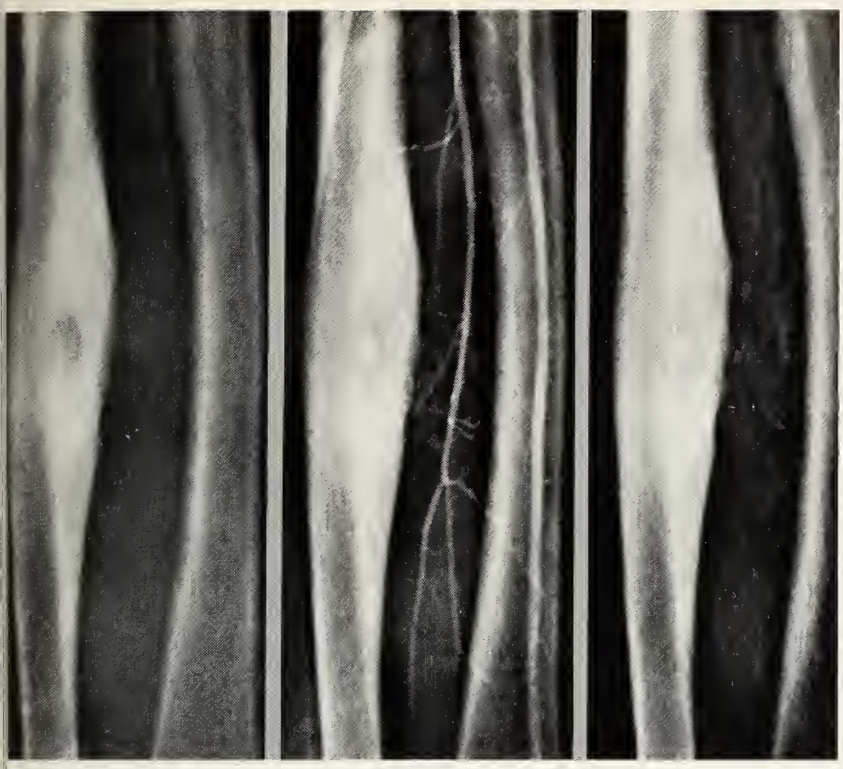

Fig. 84

Fig. 85



Fig. 86

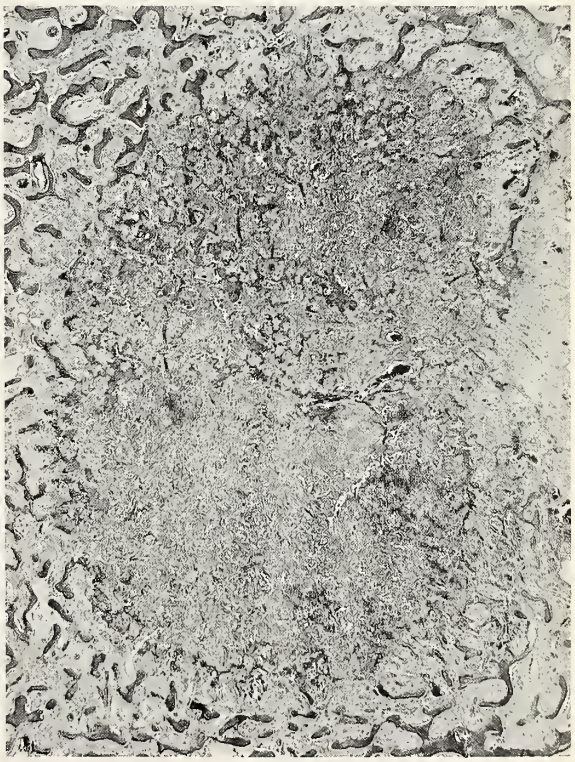

Fig. 87

OSTEOID OSTEOMA

(Figures 89 and 90 are from the same case)

Figure 88.* Histologic section of a center of a nidus from an osteoid osteoma removed from the proximal phalanx of the right second toe of a 23-year-old man. Note irregular abnormal bone formation, cement lines, and scanty vascular stroma between bony trabeculae. Hematoxylin and eosin stain. X 245. A. F. I. P. Acc. No. 682927.

Figure 89. Disoriented pattern of bone formation in a photomicrograph of a section of a nidus of osteoid osteoma from a femur of a 31-year-old man. Note very vascular fibrous tissue, prominent osteoblastic activity, and peripheral sclerotic cortical bone. Hematoxylin and eosin stain. X 98. B.H. 54–1375; A. F. I. P. Acc. No. 218757–145.

Figure 90. The richly vascular fibrous stroma and disorganized osteoid and bone are apparent in this photomicrograph of the lesion. Hematoxylin and eosin stain. X 245. B.H. 54–1375; A. F. I. P. Acc. No. 218757–146.

Figure 91.* Photomicrograph showing section of a nidus of an osteoid osteoma of the first phalanx from right middle finger of a 31-year-old man. Note fibrous stroma containing multinucleated giant cells and thin-walled blood vessels. Hematoxylin and eosin stain. X 245. A. F. I. P. Acc. No. 708079.

---

*From the Armed Forces Institute of Pathology.

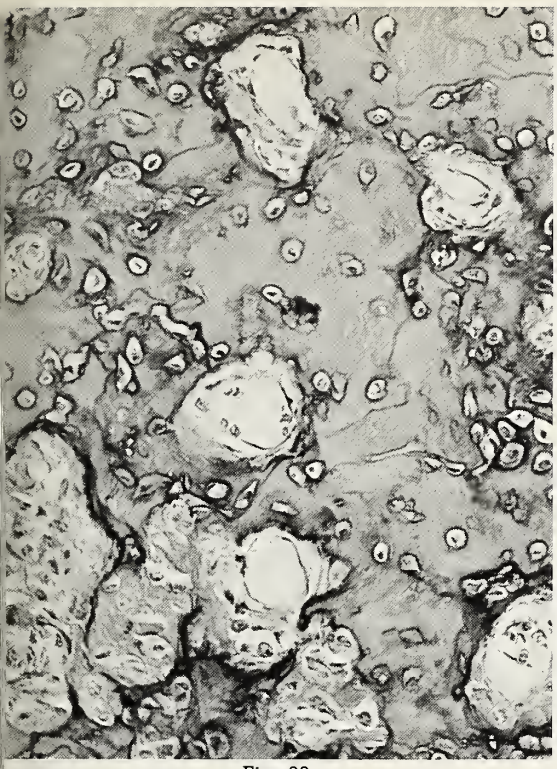

Fig. 88

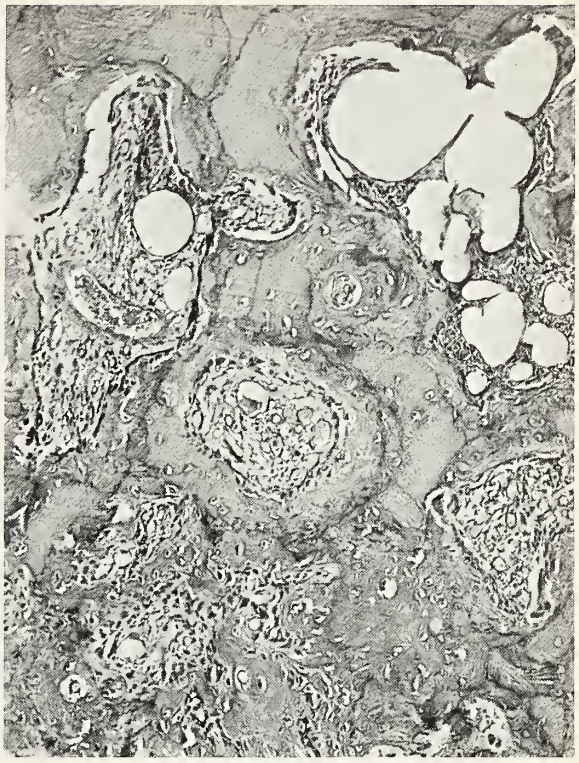

Fig. 89

Fig. 90

Fig. 91

OSTEOID OSTEOMA

(Figures 92 and 93 are from the same case*)

Figure 92. Photomicrograph clearly illustrating prominent vascularity of the stroma of a nidus of an osteoid osteoma. The lesion was removed from the mandible of a 23-year-old man. Hematoxylin and eosin stain. X 175. A. F. I. P. Acc. No. 694246–1.

Figure 93. Higher power photomicrograph demonstrates blood vessels, osteoblastic activity, and irregular bone formation of the nidus. Hematoxylin and eosin stain. X 660. A. F. I. P. Acc. No. 694246–2.

---

*From the Armed Forces Institute of Pathology.

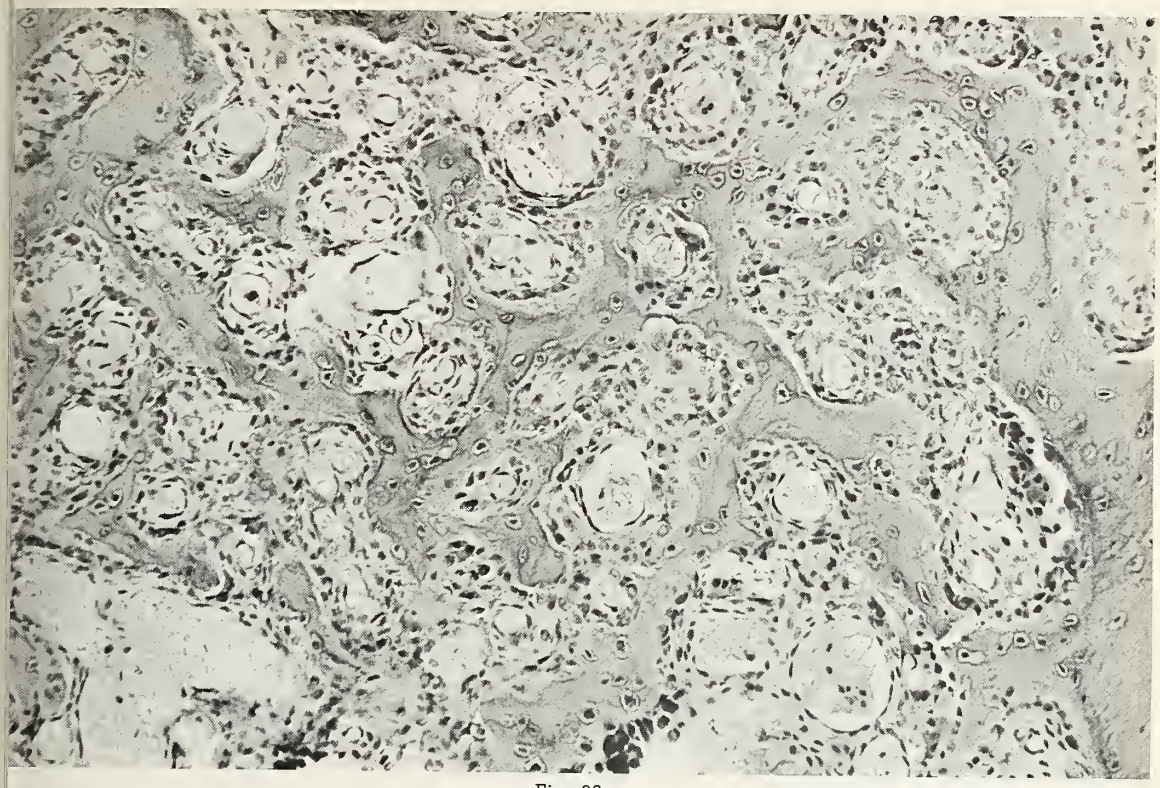

Fig. 92

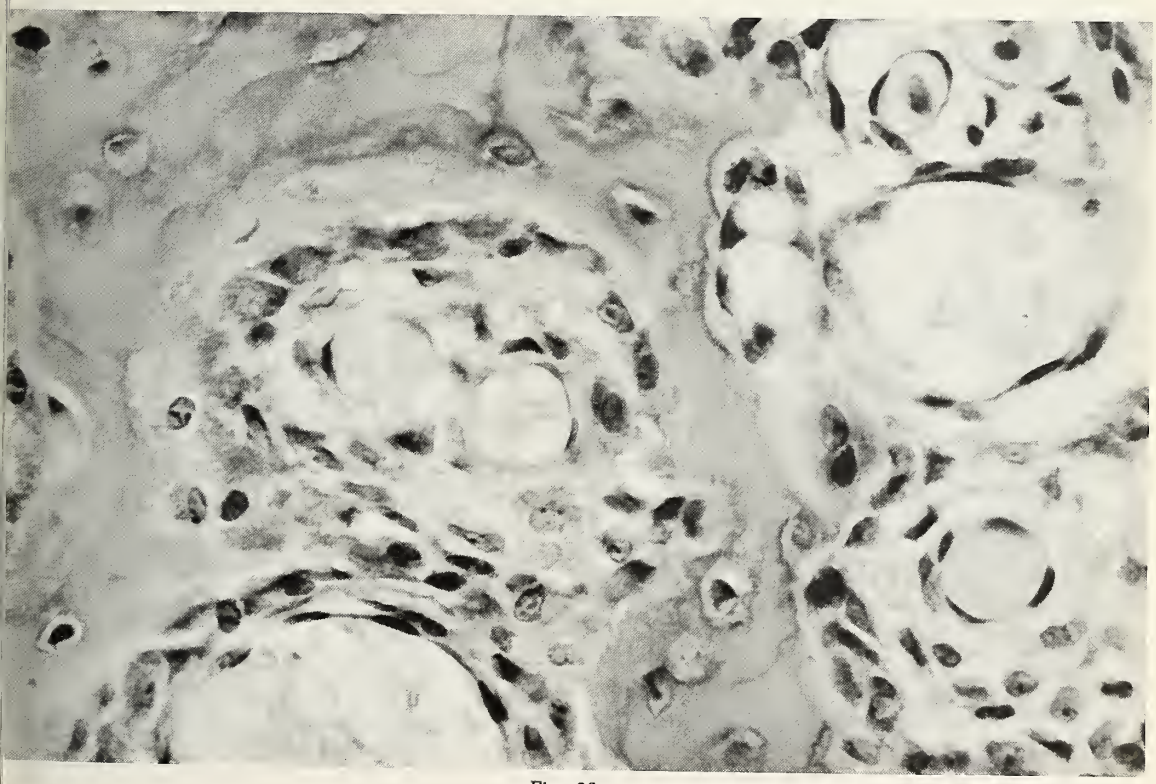

Fig. 93

OSTEOBLASTOMA (BENIGN)

(Figures 94 and 95 are from the same case. Figures 96 and 97 are from the same case*)

Figure 94. Roentgenogram of a benign osteoblastoma of a tibia in a young adult showing an irregular radiolucent defect without periosteal bone formation. (Courtesy of Dr. H. L. Jaffe, New York, N.Y.) A. F. I. P. Acc. No. 218757–147.

Figure 95. Hemisections of the resected specimen show a well circumscribed lesion with hemorrhagic border and thickening of the overlying cortex. (This is figure 2B in Jaffe, H. L. Benign osteoblastoma. Bull. Hosp. Joint Dis., 17:141–151, 1956.) A. F. I. P. Acc. No. 218757–148.

Figure 96. This roentgenogram of a benign osteoblastoma shows a small but radiolucent nidus with surrounding sclerotic bone. Note also the fusiform symmetrical expansion of the shaft of the bone. A. F. I. P. Acc. No. 218757–150.

Figure 97. The photograph illustrates the irregular character of this nidus and its characteristic loose attachment to the surrounding bone. A. F. I. P. Acc. No. 218757–149.

---

*From Dockerty, M. B., Ghormley, R. K., and Jackson, A. E. Osteoid osteoma. A clinicopathologic study of 20 cases. Ann. Surg., 133:77–89, 1951. Figures 8a and 8c are fascicle figures 96 and 97.

Fig. 94

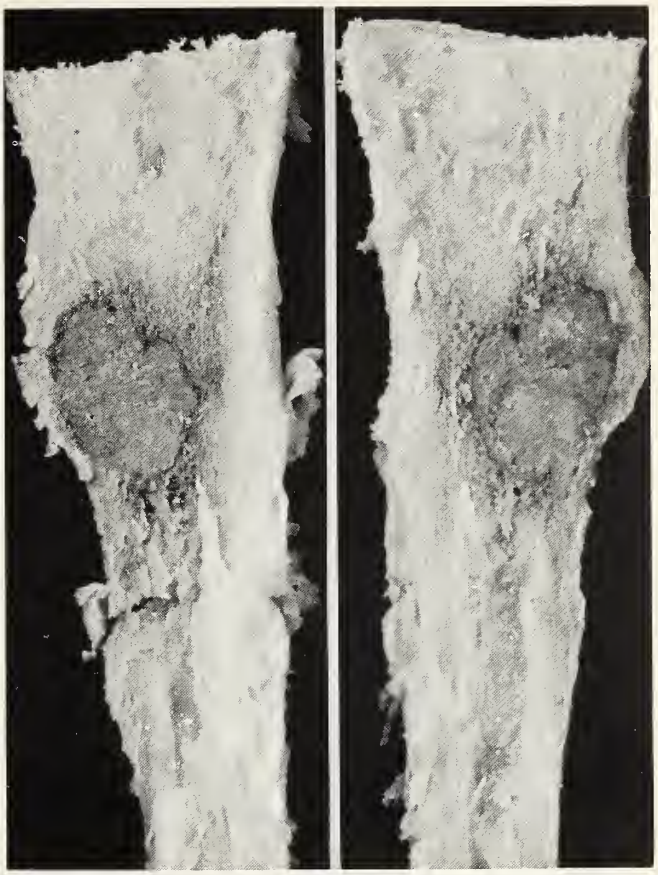

Fig. 95



Fig. 96

Fig. 97

OSTEOBLASTOMA (BENIGN)

(Figures 98–100 are from the same case)

Figure 98.* Photomicrograph showing irregular bone formation and highly vascular stroma. The bone is partially calcified. Numerous osteoblasts and occasional osteoclasts are present. Because of the numerous multinucleated giant cells, this type of lesion has been mistaken for giant cell tumor. Hematoxylin and eosin stain. X 215. A. F. I. P. Acc. No. 218757–30.

Figure 99.* Higher power microscopic view of the center of a nidus demonstrates osteoblastic activity, rich vascular stroma, and extravasated blood. Hematoxylin and eosin stain. X 235. A. F. I. P. Acc. No. 218757–32.

*Courtesy of Dr. Louis Lichtenstein, Los Angeles, Calif.



Fig. 98

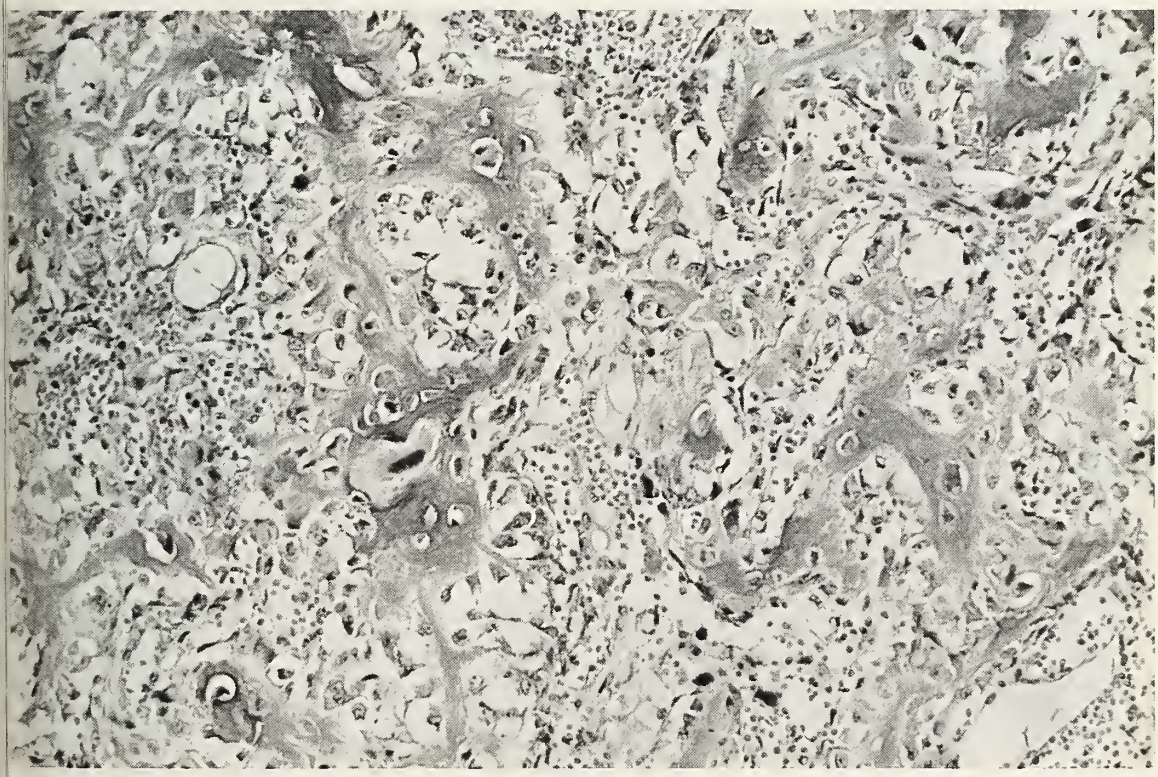

Fig. 99

Gross and microscopic patterns of tumors produced experimentally in animals by irradiation of bone are similar to those in human beings. For instance, Kuzma and Zander and Anderson and associates reported the following on the use of radioactive Ca^{45} and Sr^{89} in production of bone tumors in rats and mice (figs. 147–149): (1) Early changes showed widening of epiphysial plates, enlargement and ballooning of cartilage cells on the metaphysial side, and irregularity of columns of cartilage cells. (2) Later changes showed widening of metaphysial areas, irregularity of endosteal bone formation, and development of irregular masses of fibrous tissue in the metaphysis. (3) Malignant bone tumors developed chiefly in the hind limbs. In rats given Ca^{45}, tumors of the spine and pelvic bones also developed.

Radiation osteitis as interpreted by Martland consisted of two stages: (1) hyperplasia of marrow, perhaps due to a compensatory mechanism caused by stimulation from alpha particles; (2) in contrast, hypoplasia and atrophy of marrow, as observed in experimental animals by Dunlap and associates, follows and represents a healing phase which often occurs in patchy areas; there is then an actual replacement of hyperplastic marrow by fibrosis which, in the beginning, is very cellular and contains numerous mitoses. Martland (p. 2491) felt that this "very cellular stage of radiation osteitis is responsible for the development of sarcoma."

Survival from radiation induced sarcoma of bone is only fair. Of the collected group of 39 cases from the Mayo Clinic and Memorial Center, 30 patients are either living with the disease or dead. Those dying of the disease usually died with widespread metastases, except that two (Sabanas et al.) had only regional lymph node metastases. Nine are living and apparently well, some of them living up to 20 years after treatment and others for less than five years.

References

Anderson, W. A. D., Zander, G. E., and Kuzma, J. F. Cancerogenic effects of Ca^{45} and Sr^{89} on bones of CF_1 mice. A.M.A. Arch. Path., 62:262–271, 1956.

Aub, J. C., Evans, R. D., Hempelmann, L. H., and Martland, H. S. The late effects of internally-deposited radioactive materials in man. Medicine, 31:221–329, 1952.

Beck, A. Zur Frage des Röntgensarkoms, zugleich ein Beitrag zur Pathogenese des Sarkoms. München. med. Wchnschr., 69:623–625, 1922.

Bergstrand, H. Über eine eigenartige, wahrscheinlich bisher nicht beschriebene oteoblastische Krankheit in den langen Knochen der Hand und des Fusses. Acta radiol., 11:596–612, 1930.

Cade, S. Osteogenic sarcoma. A study based on 133 patients. J. Roy. Coll. Surgeons Edinburgh, 1:79–111, 1955.

Cahan, W. G., Woodard, H. Q., Higinbotham, N. L., Stewart, F. W., and Coley, B. L. Sarcoma arising in irradiated bone. Report of eleven cases. Cancer, 1:3–29, 1948.

Carroll, R. E. Osteoid osteoma in the hand. J. Bone & Joint Surg., 35–A:888–893, 1953.

Chambers, T. R. Myositis ossificans. A study of another unusual case. Arch. Surg., 16:755–763, 1928.

Clark, S. D. Where are the cases of radium poisoning? A plea for assistance. J.A.M.A., 168:761–762, 1958.

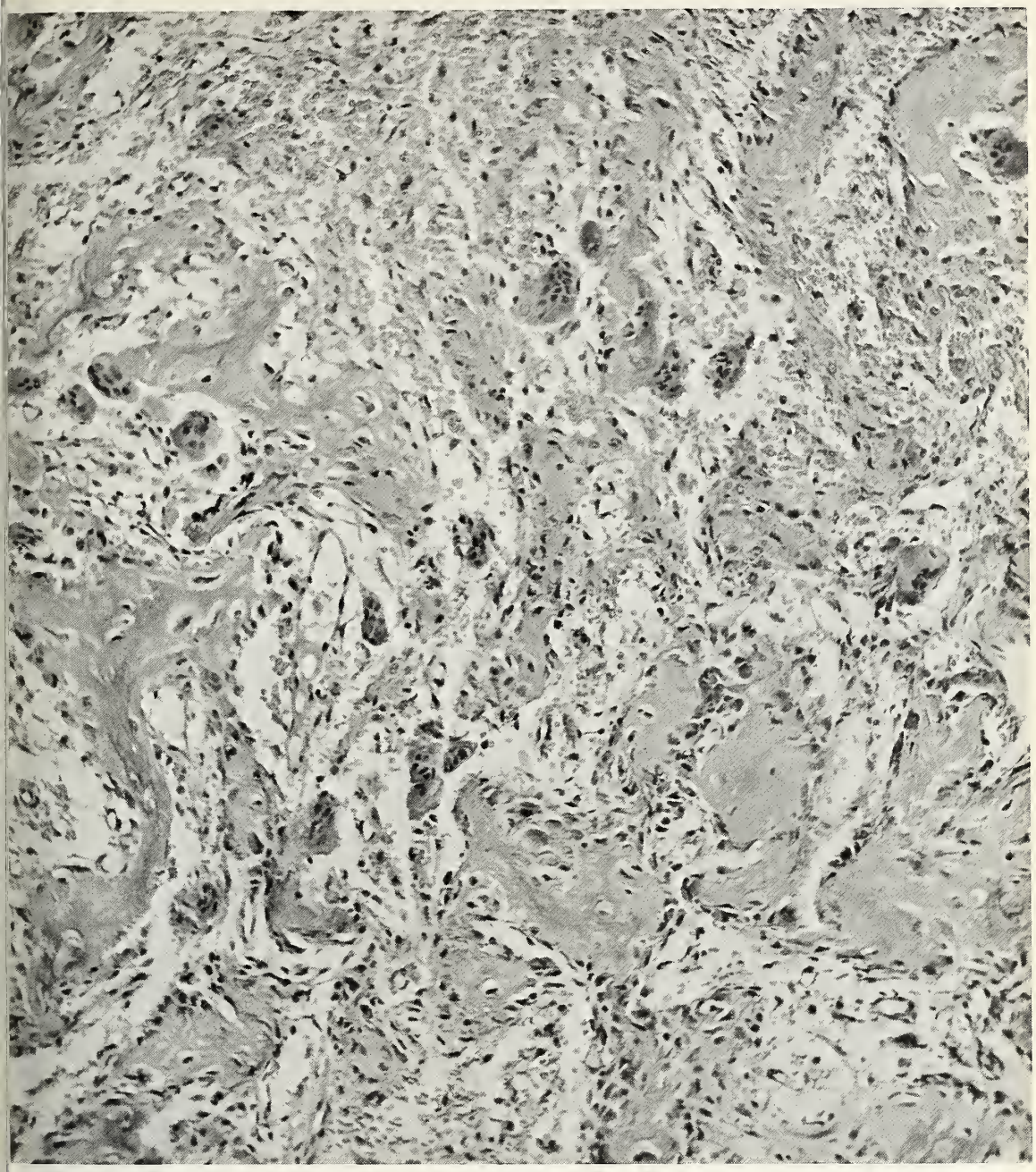

Fig. 100

OSTEOBLASTOMA (BENIGN)

(Figures 98–100 are from the same case)

Figure 100. Multinucleated giant cells (probably osteoclasts), irregular bone formation, vascular stroma, and intense osteoblastic activity are evident in this photomicrograph. Hematoxylin and eosin stain. X 235. (Courtesy of Dr. Louis Lichtenstein, Los Angeles, Calif.) A. F. I. P. Acc. No. 218757–31.

OSTEOSARCOMA

(Figures 101 and 102 are from the same case)

Figure 101. Roentgenogram demonstrating cortical and extraosseous components of an osteosarcoma of the metaphysis and diaphysis of a tibia. This lesion occurred in a 14-year-old Negro boy who had been struck at this site eight months previously. Intermittent swelling at the site had been noted since the blow. W.U. 48–6537; A. F. I. P. Acc. No. 218757–154.

Figure 102. Hemisection confirmed the extraosseous components. Note also that the epiphysial plate was spared. Thickening toward obliteration of both cortical structure and medulla is prominent. W.U. 48–5884; A. F. I. P. Acc. No. 218757–153.

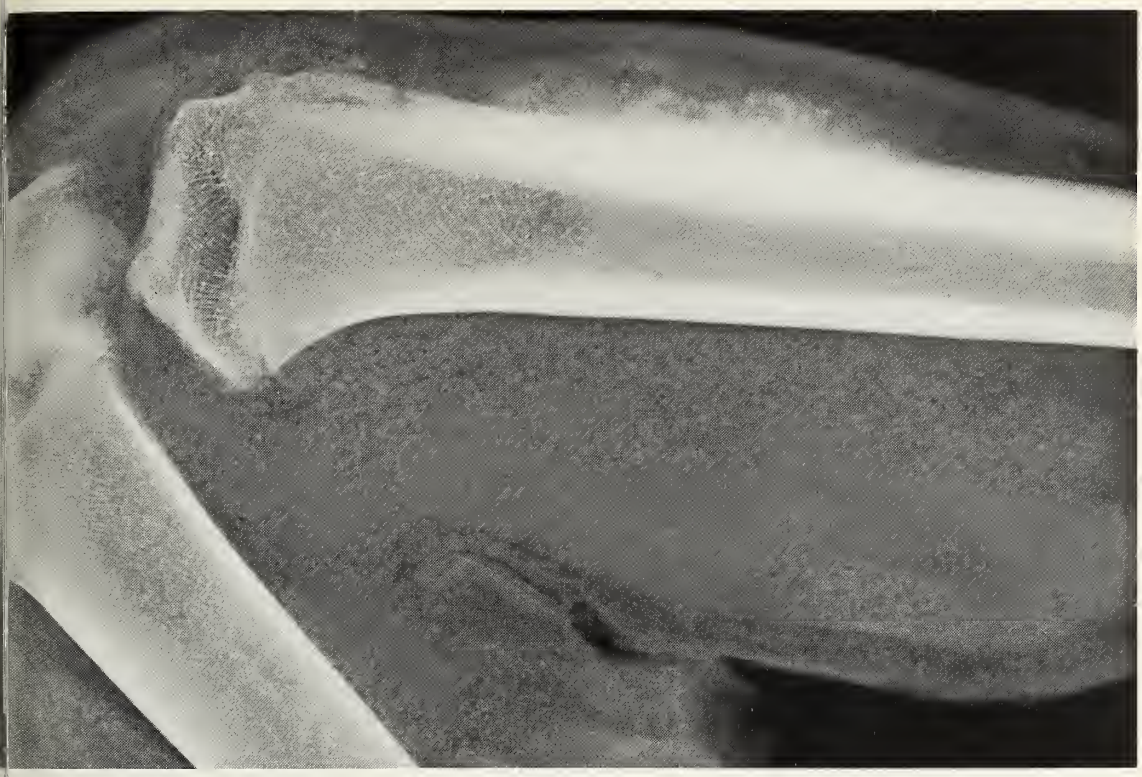

Fig. 101

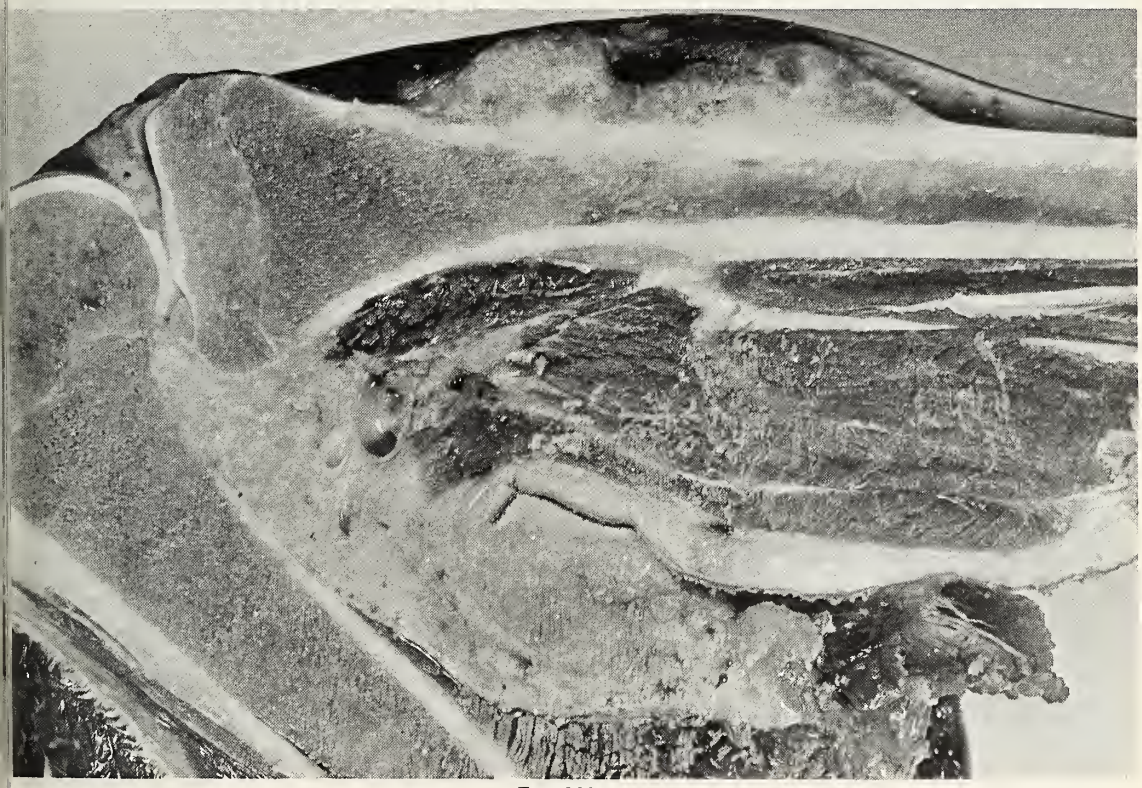

Fig. 102

OSTEOSARCOMA

(Figures 104 and 105 are from the same case)

Figure 103. Hemisection of an osteosarcoma from the proximal portion of the left humerus of a 22-year-old woman. The patient had had pain and swelling of the left upper arm for two years. Biopsy had been refused so radiation therapy had been administered.

Biopsy of the tumor, after reappearance of the swelling, proved it an osteosarcoma. The tumor was locally resected and the specimen represents a well differentiated sclerotic osteosarcoma. This showed evidence of destruction, calcification, heavy ossification in the medulla and cortex, and an extraosseous component.

Ten months after resection, the patient was readmitted to the hospital because of pulmonary metastases and local recurrence. Some of the metastases were locally resected, but the patient died a few months later. W.U. 53–4340; A. F. I. P. Acc. No. 218757–155.

Figure 104. Hemisection of an osteosarcoma of the distal portion of a humerus. The tumor occurred in a 57-year-old woman who had previously sustained a pathologic fracture at this site. Biopsy proved the tumor an osteosarcoma.

The gauze sponge seen in this gross specimen represents the biopsy site. Extensive hemorrhagic destruction of the humerus made it essentially unrecognizable.

Subsequent to this shoulder-girdle amputation, the patient had had evidence of pulmonary metastases on two occasions; on each occasion, lobectomy was done. The patient was alive 10½ years after amputation. W.U. 51–288; A. F. I. P. Acc. No. 218757–156.

Figure 105. The extremely bizarre cells of the tumor are seen in the photomicrograph of this poorly differentiated osteosarcoma. Areas of osteoid are present in other fields. Lung metastases occurred subsequently and had a similar histologic pattern. Hematoxylin and eosin stain. X 660. B.H. 50–5970; A. F. I. P. Acc. No. 218757–164.

Figure 106. The photomicrographic field of this poorly differentiated osteosarcoma represents cells that are less bizarre. A fine vascular network forms a background for them. The tumor occurred in the distal femur of a 15-year-old Negro boy. Hematoxylin and eosin stain. X 700. B.H. 48285; A. F. I. P. Acc. No. 218757–165.



Fig. 103

Fig. 104

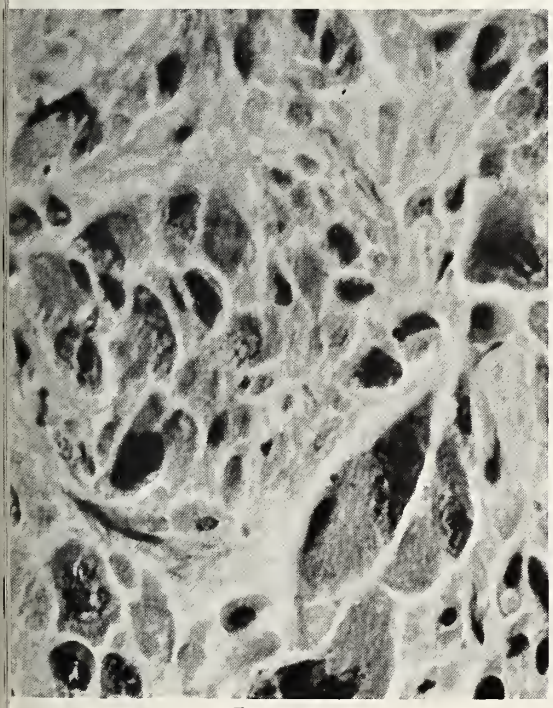

Fig. 105

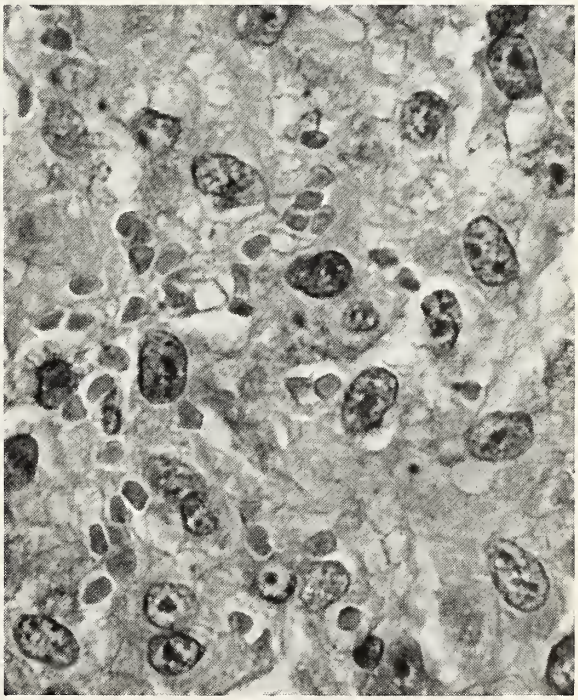

Fig. 106

Coley, W. B. Myositis ossificans traumatica. A report of three cases illustrating the difficulties of diagnosis from sarcoma. Ann. Surg., 57:305–337, 1913.

Coley, B. L., and Sharp, G. S. Paget's disease. A predisposing factor to osteogenic sarcoma. Arch. Surg., 23:918–936, 1931.

Collins, D. H. Paget's disease of bone. Incidence and subclinical forms. Lancet, 2:51–57, 1956.

Coventry, M. B., and Dahlin, D. C. Osteogenic sarcoma. A critical analysis of 430 cases. J. Bone & Joint Surg., 39–A:741–758, 1957.

Cowie, R. S., Barr, J. S., and Dudley, H. R., Jr. Bone sarcoma in Paget's disease. Report of a case with long survival. J. Bone & Joint Surg., 40–B:730–734, 1958.

Cruz, M., Coley, B. L., and Stewart, F. W. Postradiation bone sarcoma. Report of eleven cases. Cancer, 10:72–88, 1957.

Dahlin, D. C. Bone Tumors. Osteoid Osteoma, pp. 50–57; Giant Osteoid Osteoma (Osteogenic Fibroma, Benign Osteoblastoma), pp. 58–65. Springfield, Ill.: Charles C Thomas, 1957.

_____, and Johnson, E. W., Jr. Giant osteoid osteoma. J. Bone & Joint Surg., 36–A:559–572, 1954.

Dockerty, M. B., Ghormley, R. K., and Jackson, A. E. Osteoid osteoma. A clinicopathologic study of 20 cases. Ann. Surg., 133:77–89, 1951.

Dunlap, C. E., Aub, J. C., Evans, R. D., and Harris, R. S. Transplantable osteogenic sarcomas induced in rats by feeding radium. Am. J. Path., 20:1–21, 1944.

Dwinnell, L. A., Dahlin, D. C., and Ghormley, R. K. Parosteal (juxtacortical) osteogenic sarcoma. J. Bone & Joint Surg., 36–A:732–744, 1954.

Fine, G., and Stout, A. P. Osteogenic sarcoma of the extraskeletal soft tissues. Cancer, 9:1027–1043, 1956.

Finlayson, R. Osteogenic sarcoma with multiple skeletal tumours. J. Path. & Bact., 66:223–229, 1953.

Flaherty, R. A., Pugh, D. G., and Dockerty, M. B. Osteoid osteoma. Am. J. Roentgenol., 76:1041–1051, 1956.

Freiberger, R. H., Loitman, B. S., Helpern, M., and Thompson, T. C. Osteoid osteoma. A report on 80 cases. Am. J. Roentgenol., 82:194–205, 1959.

Geschickter, C. F., and Copeland, M. M. Parosteal osteoma of bone: a new entity. Ann. Surg., 133:790–807, 1951.

Goidanich, I. F. I Tumori Primitivi dell'Osso. Bologna, Italy, Societa per Azioni Poligrafici Il Resto del Carlino, 1957.

_____, and Zanasi, R. Osteoma osteoide ed Osteomielite sclerosante: due entità cliniche definite e distinte. Chir. org. movim., 43:427–460, 1956.

Goldenberg, R. R. The skeleton in Paget's disease. Bull. Hosp. Joint Dis., 12:229–255, 1951.

Golding, J. S. R. The natural history of osteoid osteoma. With a report of twenty cases. J. Bone & Joint Surg., 36–B:218–229, 1954.

_____, and Sissons, H. A. Osteogenic fibroma of bone. A report of two cases. J. Bone & Joint Surg., 36–B:428–435, 1954.

Gricouroff, G. Fréquence des ostéosarcomes à la suite d'injections intraveineuses de mésothorium chez le lapin. Compt. rend. Soc. de biol., 139:558–560, 1945.

Gschnitzer, F., and de Gennaro, P. F. Das Osteoid-Osteom. Klinik, Pathomorphologie und Gedanken zur Ätiologie. Ztschr. f. Orthop., 86:1–14, 1955.

Hatcher, C. H. The development of sarcoma in bone subjected to roentgen or radium irradiation. J. Bone & Joint Surg., 27:179–195, 1945.

Jaffe, H. L. Paget's disease of bone. Arch. Path., 15:83–131, 1933.

_____. "Osteoid-osteoma." A benign osteoblastic tumor composed of osteoid and atypical bone. Arch. Surg., 31:709–728, 1935.

_____. Osteoid-osteoma of bone. Radiology, 45:319–334, 1945.

_____. Osteoid osteoma. Proc. Roy. Soc. Med., 46:1007–1012, 1953.

Fig. 107

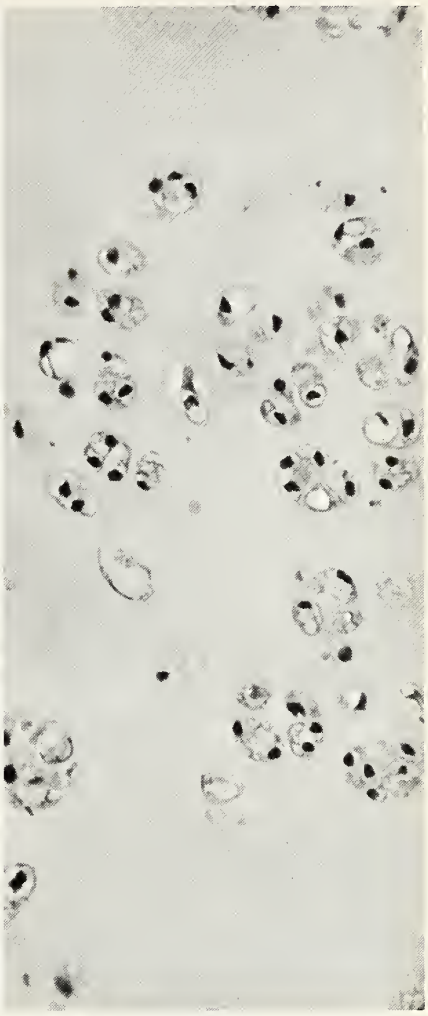

Fig. 108

OSTEOSARCOMA

Figure 107. This roentgenogram is of an osteosarcoma of the distal end of a femur of a 20-year-old man who had had pain in the left knee for six months. It demonstrates periosteal reaction and ossification in an extraosseous component. There is also sclerotic change in the medulla. Diagnosis was confirmed by biopsy, but the patient refused amputation. W.U. 57–3309; A. F. I. P. Acc. No. 218757–159.

Figure 108. This histologic section shows malignant characteristics of cartilage from an osteosarcoma from the distal portion of a femur of a 31-year-old man. Other photomicrographic fields also demonstrated these characteristic features of the osteosarcoma. A generous incisional biopsy revealed the major component of the tumor as cartilage. Hematoxylin and eosin stain. X 375. W.U. 58–4221; A. F. I. P. Acc. No. 218757–173.

OSTEOSARCOMA

Figure 109. Hemorrhagic lytic sarcoma involving the proximal portion of a tibia of an 11-year-old boy. Sections show cortical and medullary destruction. The epiphysial plate was breached by the sarcoma. W.U. 54–492; A. F. I. P. Acc. No. 218757–157.

Figure 110. Section from another case also illustrates extension of osteosarcoma through the epiphysial plate. This finding is uncommon in osteosarcoma. W.U. 54–3100; A. F. I. P. Acc. No. 218757–158.

Fig. 109



Fig. 110

OSTEOSARCOMA

(Figures 111 and 112 are from the same case. Figures 113 and 114 are from the same case)

Figure 111. Histologic section of osteosarcoma illustrating surviving normal bone, osteoid formation, and sarcomatous stroma; other areas revealed cartilaginous formation. The tumor occurred in a 15-year-old boy, who had had pain in the left knee for 2½ months. Hematoxylin and eosin stain. X 120. B.H. 56–8591; A. F. I. P. Acc. No. 218757–160.

Figure 112. Another microscopic field of this tumor shows relationship of sarcomatous stroma and malignant osteoid to surrounding adjacent nonmalignant connective tissue. Demonstration of malignant stroma with malignant osteoid is important in diagnosis of osteosarcoma. Hematoxylin and eosin stain. X 180. B.H. 56–8591; A. F. I. P. Acc. No. 218757–161.

Figure 113. Osteosarcoma of a tibia of a 10-year-old boy. Such poorly differentiated areas may be confused with metastatic cancer. Careful search of the slide frequently must be made before evidence of osteoid formation is found. Hematoxylin and eosin stain. X 705. B.H. 47740; A. F. I. P. Acc. No. 218757–163.

Figure 114. The vascular pattern and bizarre stromal cells which comprise the tumor are seen in another photomicrographic field. Hematoxylin and eosin stain. X 705. B.H. 47740; A. F. I. P. Acc. No. 218757–166.

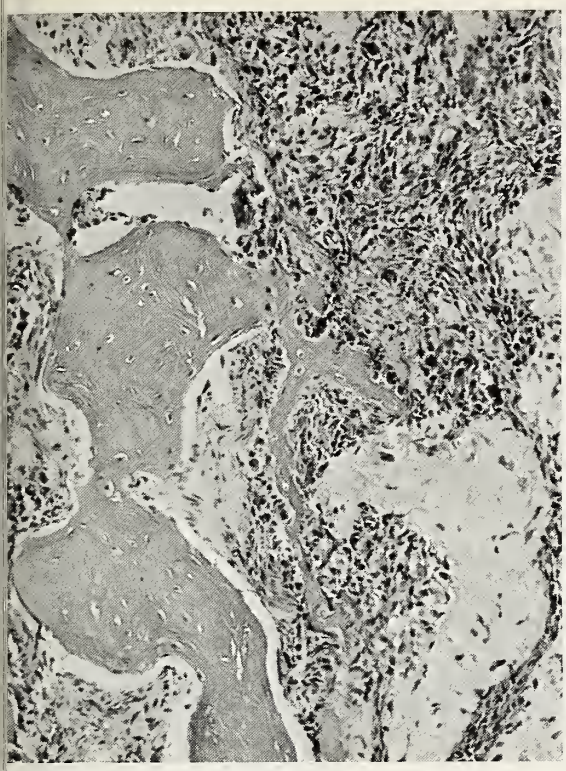

Fig. 111

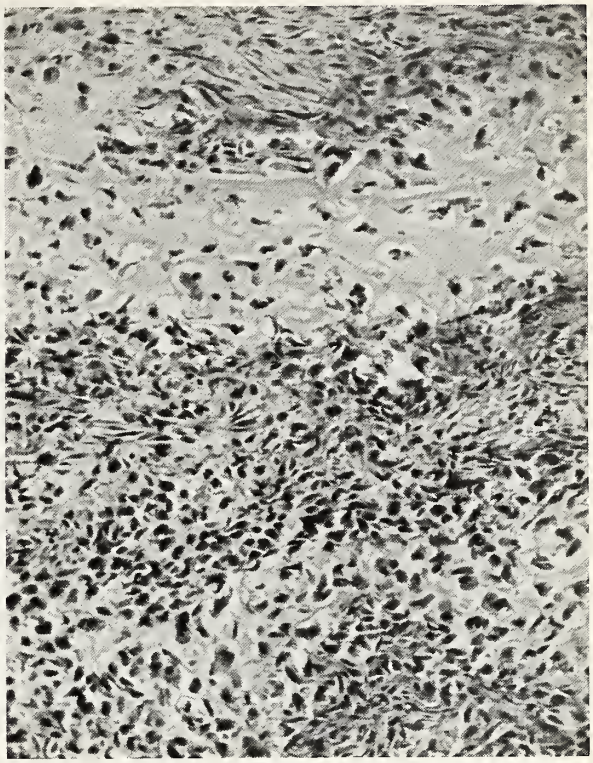

Fig. 112

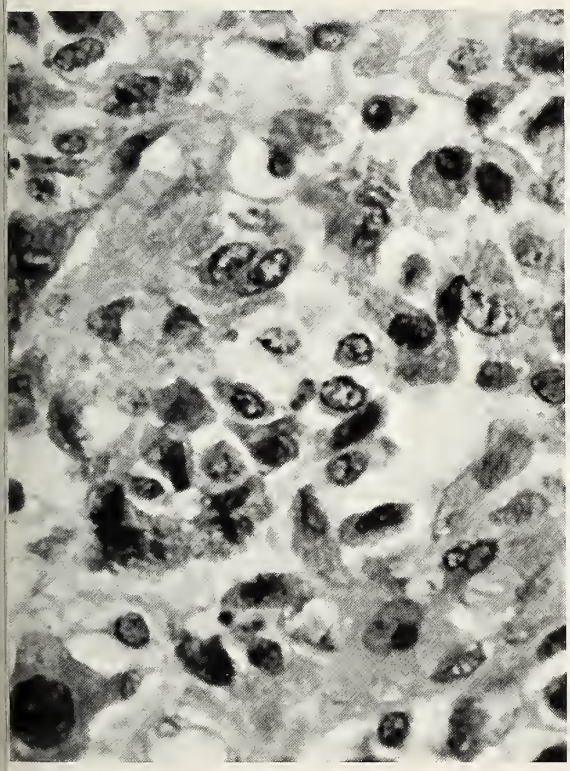

Fig. 113

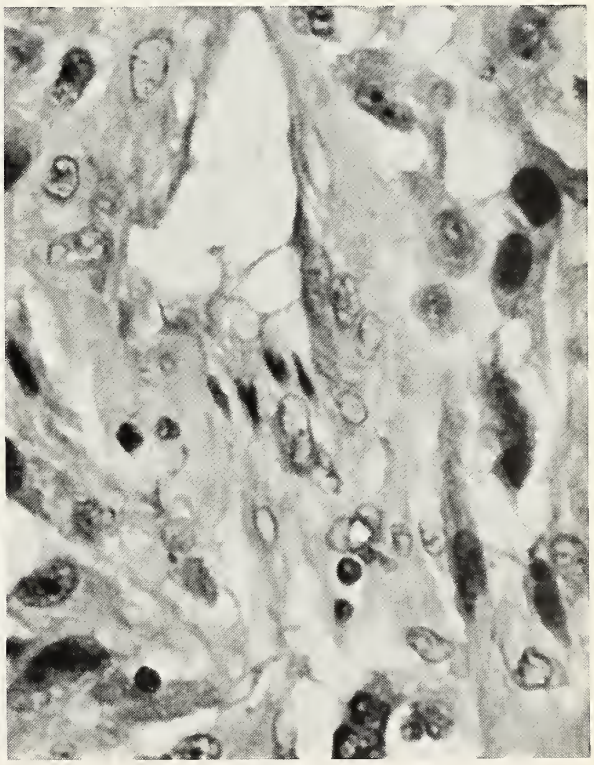

Fig. 114

OSTEOSARCOMA

Figure 115. Extensive osteoid formation is seen in this photomicrographic section of an osteosarcoma. Cells having characteristics of malignant neoplasm are present, apparently forming the osteoid. The lesion occurred in the mandible. Hematoxylin and eosin stain. X 165. B.H. 35130; A. F. I. P. Acc. No. 218757–399.

Figure 116. This poorly differentiated osteosarcoma of an ilium of a 31-year-old man shows irregularly eroded remnants of surviving non-neoplastic bone. The photomicrograph also shows osteoid formation within the tumor. Background cells forming the osteoid have the malignant characteristics. Numerous vascular channels are also present. Hematoxylin and eosin stain. X 165. B.H. 53–4480; A. F. I. P. Acc. No. 218757–162.

Figure 117. Osteosarcoma arising in a patella of a 16-year-old girl shows a cellular pattern with nestlike conglomerate masses. In the photomicrograph, note calcified bony matrix and osteoid formation; cells forming the osteoid apparently have malignant characteristics similar to cells forming the stromal background. Hematoxylin and eosin stain. X 165. B.H. 56–2354; A. F. I. P. Acc. No. 218757–167.

Figure 118. This histologic pattern for osteosarcoma is a variation from the usual in that it presents glandular formation, perhaps due to the cell having characteristics of malignant neoplasm and being arranged around small blood vessels. This lesion appeared in the distal femur of a 16-year-old boy. Hematoxylin and eosin stain. X 660. B.H. 54–7422; A. F. I. P. Acc. No. 218757–168.

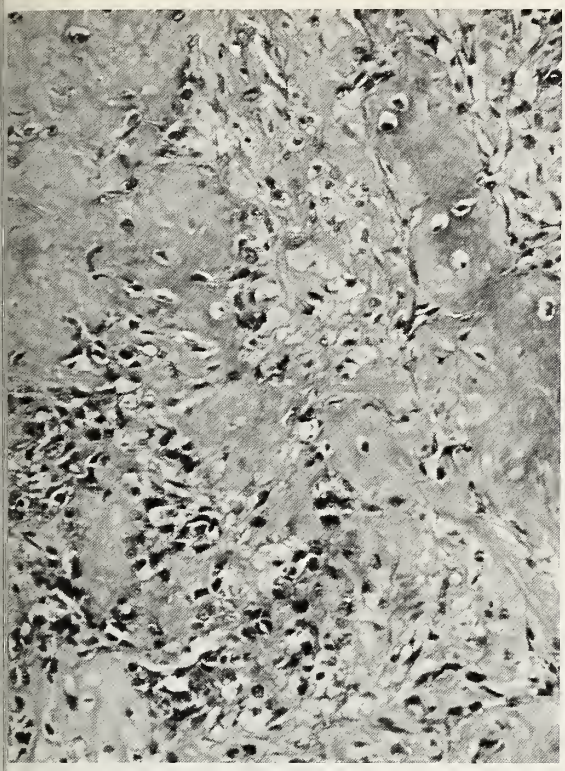

Fig. 115

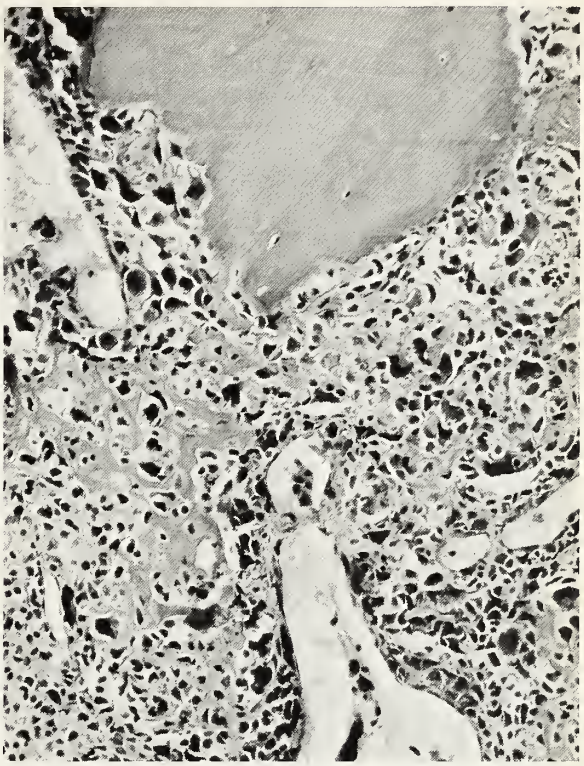

Fig. 116

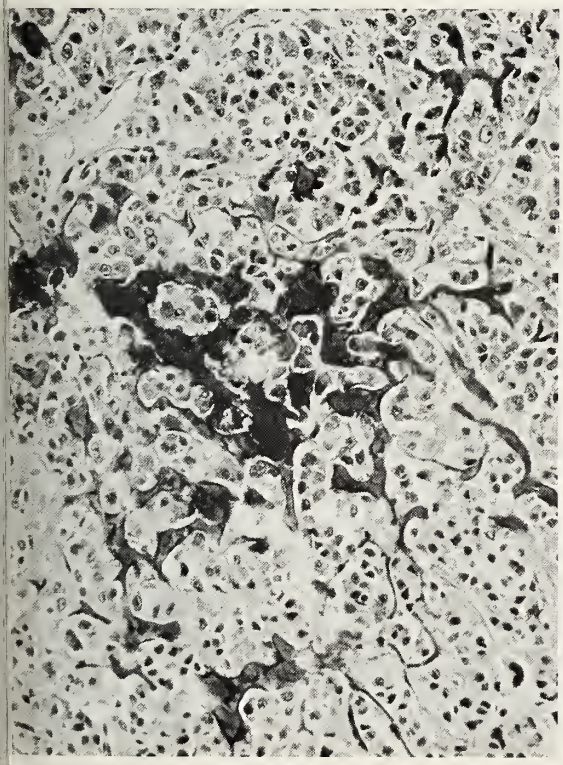

Fig. 117

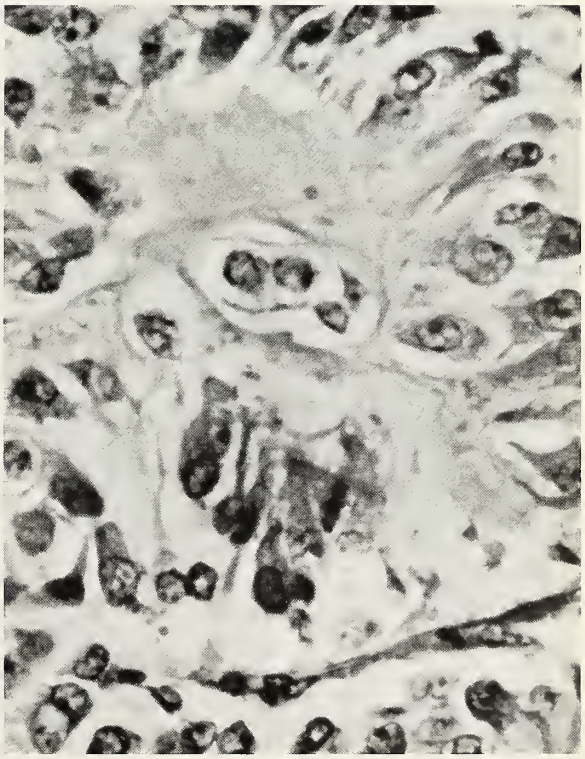

Fig. 118

OSTEOSARCOMA

(Figures 120 and 121 are from the same case)

Figure 119. Combinations of lesions such as fibrosarcoma or chondrosarcoma are occasionally seen in osteosarcomas. This photomicrograph represents a sarcomatous portion of an osteosarcoma which has the appearance of a fairly well differentiated fibrosarcoma in this field. Hematoxylin and eosin stain. X 615. B.H. 47140; A. F. I. P. Acc. No. 218757–169.

Figure 120. This photomicrographic field illustrates an interlacing bundle of spindle cells and lack of osteoid in an osteosarcoma. Part of its pattern is similar to that of a fibrosarcoma. This tumor occurred in the distal femur of a 12-year-old boy. Hematoxylin and eosin stain. X 112. B.H. 52–5833; A. F. I. P. Acc. No. 218757–170.

Figure 121. Higher power microscopic view of this field. Other fields demonstrated partly calcified immature bone and osteoid. Hematoxylin and eosin stain. X 660. B.H. 52–5833; A. F. I. P. Acc. No. 218757–171.



Fig. 119

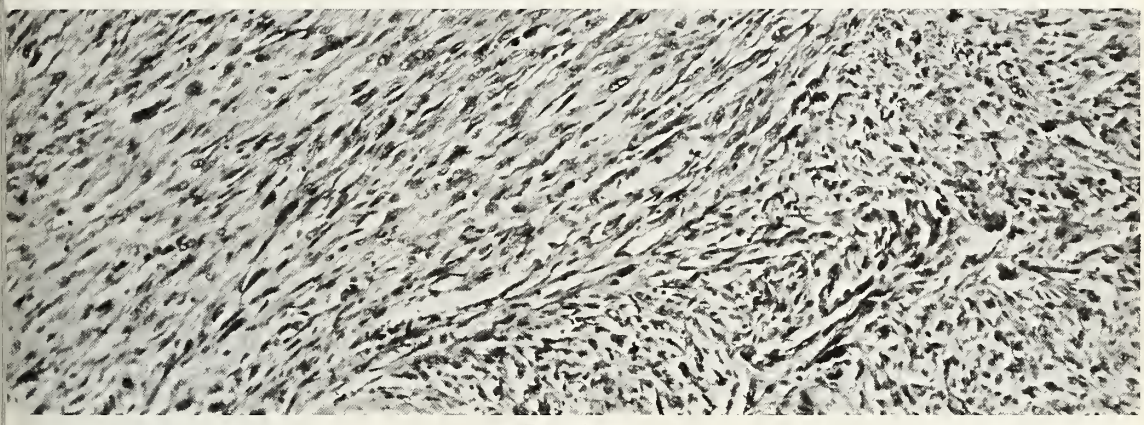

Fig. 120

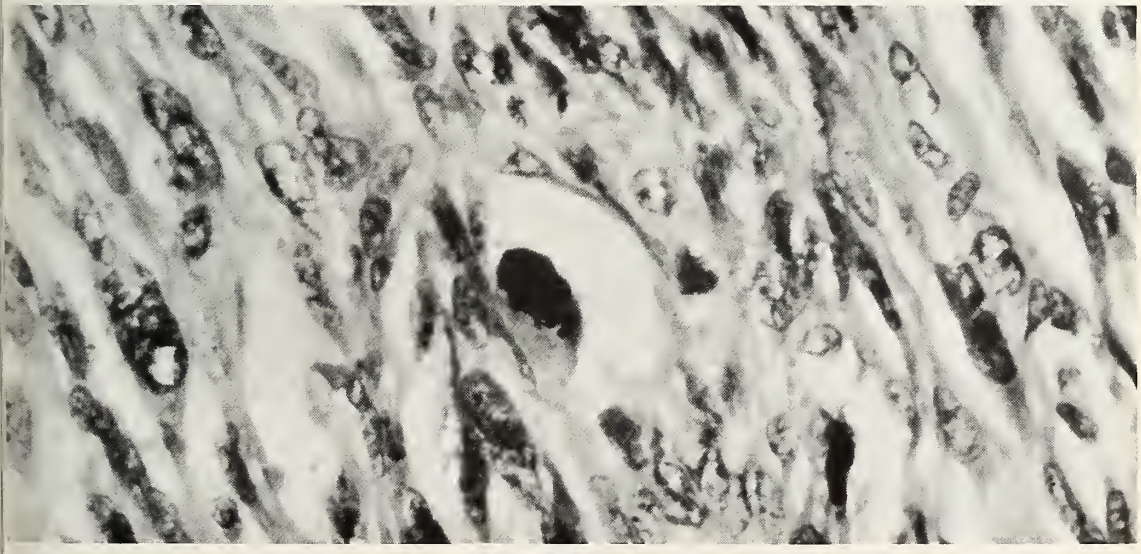

Fig. 121

OSTEOSARCOMA

(Figures 122 and 123 are from the same case*)

Figure 122. Photomicrograph showing metastatic osteoblastic osteosarcoma in a popliteal lymph node. The primary tumor was in the proximal portion of the tibia of the 20-year-old man. Hematoxylin and eosin stain. X 15. W.U. 60-793-A; A. F. I. P. Acc. No. 218757-394.

Figure 123. The section viewed under higher power. Hematoxylin and eosin stain. X 300. W.U. 60-788-A; A. F. I. P. Acc. No. 218757-395.

---

*Courtesy of Dr. G. Söderberg, Stockholm, Sweden.

Fig. 122

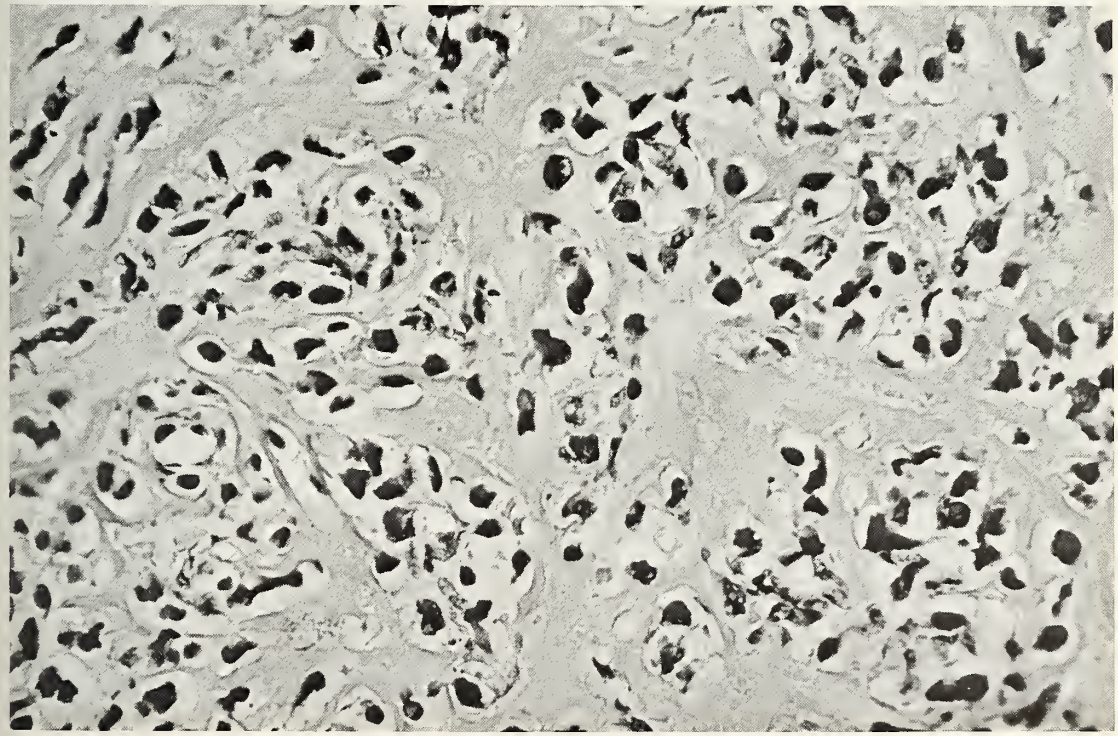

Fig. 123

PAROSTEAL SARCOMA

(Figures 124–127 are from the same case)

Figure 124.* A preoperative radiograph showing characteristic extracortical location of the tumor, dense sclerosis therein, and an apparently intramedullary portion. The latter, however, corresponds grossly to envelopment of the bone by the tumor rather than medullary involvement. A. F. I. P. Acc. No. 218757–175.

Figure 125.* Hemisection of gross specimen of this parosteal osteosarcoma. The lesion seems to involve extraosseous portions rather than extending into the medullary cavity. This impression was confirmed by microscopic examination. One of the gross features of this tumor is that it can be seen to envelop the bone. The tumor had been present for seven years. A. F. I. P. Acc. No. 218757–174.

Figure 126. This photomicrographic field illustrates the relationship of parosteal osteosarcoma to surrounding skeletal muscle. Bone formation and malignant stroma are present. Hematoxylin and eosin stain. X 150. W.U. 58–3093; A. F. I. P. Acc. No. 218757–177.

Figure 127. Higher power microscopic view of this lesion. The stroma has characteristics of a fibrosarcoma. Hematoxylin and eosin stain. X 310. W.U. 58–3094; A. F. I. P. Acc. No. 218757–178.

---

*From Dwinnell, L. A., Dahlin, D. C., and Ghormley, R. K. Parosteal (juxtacortical osteogenic sarcoma). J. Bone & Joint Surg., 36–A:732–744, 1954. Figures 1–C and 2–A are fascicle figures 124 and 125.

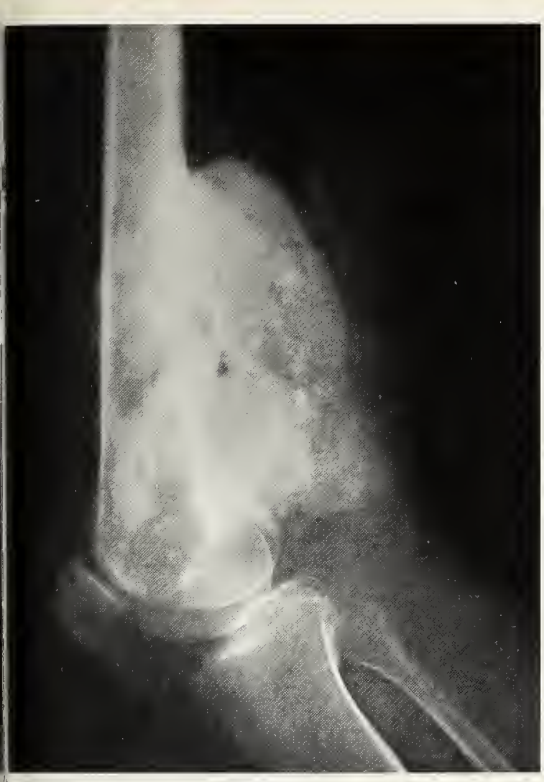

Fig. 124

Fig. 125

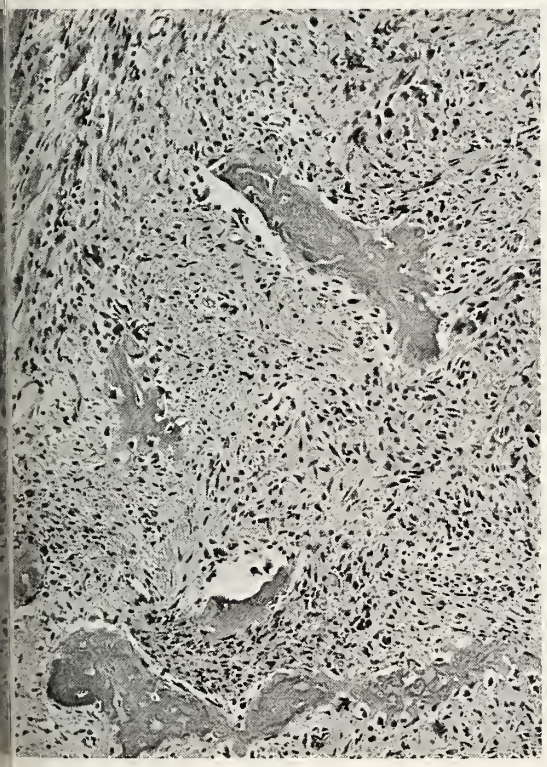

Fig. 126

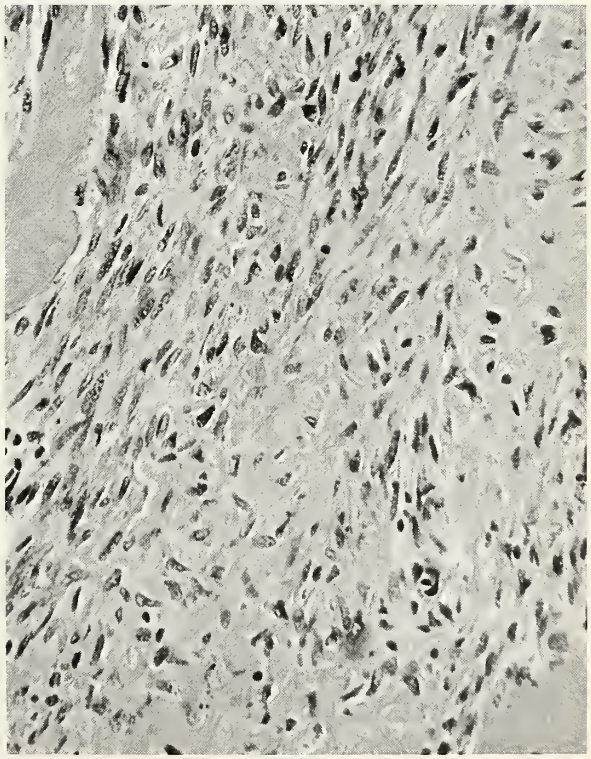

Fig. 127

Jaffe, H. L. Benign osteoblastoma. Bull. Hosp. Joint Dis., 17:141–151, 1956.

_____. Tumors and Tumorous Conditions of the Bones and Joints. Benign Osteoblastoma, pp. 107–116. Philadelphia: Lea & Febiger, 1958.

_____, and Selin, G. Tumors of bones and joints. Bull. New York Acad. Med., 27:165–174, 1951.

Kuzma, J. F., and Zander, G. Cancerogenic effects of Ca^{45} and Sr^{89} in Sprague-Dawley rats. A.M.A. Arch. Path., 63:198–206, 1957.

Lansche, W. E. Unpublished data, Barnes Hospital, St. Louis, Mo., 1959.

Lichtenstein, L. Benign osteoblastoma. A category of osteoid- and bone-forming tumors other than classical osteoid osteoma, which may be mistaken for giant-cell tumor or osteogenic sarcoma. Cancer, 9:1044–1052, 1956.

_____. Bone Tumors. Benign Osteoblastoma, pp. 97–108; Osteogenic Sarcoma of Bone, pp. 191–214. 2nd ed. St. Louis: C. V. Mosby Co., 1959.

Lindbom, Å., Lindvall, N., Söderberg, G., and Spjut, H. J. Angiography in osteoid osteoma. Acta radiol., 54:327–333, 1960.

_____, Söderberg, G., and Spjut, H. J. Osteosarcoma. A review of 96 cases. Acta radiol., 56:1–19, 1961.

Looney, W. B. I. Late effects (twenty-five to forty years) of the early medical and industrial use of radio-active materials. Their relation to the more accurate establishment of maximum permissible amounts of radio-active elements in the body. J. Bone & Joint Surg., 37–A:1169–1187, 1955.

_____. II and III. Late effects (twenty-five to forty years) of the early medical and industrial use of radioactive materials. Their relation to the more accurate establishment of maximum permissible amounts of radioactive elements in the body. J. Bone & Joint Surg., 38–A:175–218; 392–406, 1956.

_____. The Basis for the Present Maximum Permissible Concentration for Radium and Its Relation to the Maximum Permissible Concentration for Strontium 90. In: The Nature of Radioactive Fallout and Its Effects on Man, pp. 1160–1191. Pt. 2. Joint Committee on Atomic Energy, Congress of the United States. Washington, D.C.: Government Printing Office, 1957.

_____, and Woodruff, L. A. Investigation of radium deposition in human skeleton by gross and detailed autoradiography. A.M.A. Arch. Path., 56:1–12, 1953.

_____, Hasterlik, R. J., Brues, A. M., and Skirmont, E. A clinical investigation of the chronic effects of radium salts administered therapeutically (1915–1931). Am. J. Roentgenol., 73:1006–1037, 1955.

Martland, H. S. The occurrence of malignancy in radioactive persons. A general review of data gathered in the study of the radium dial painters, with special reference to the occurrence of osteogenic sarcoma and the inter-relationship of certain blood diseases. Am. J. Cancer, 15:2435–2516, 1931.

_____, and Humphries, R. E. Osteogenic sarcoma in dial painters using luminous paint. Arch. Path., 7:406–417, 1929.

Moberg, E. The natural course of osteoid osteoma. J. Bone & Joint Surg., 33–A:166–170, 1951.

_____. Further observations on "corticalisosteoide" or "osteoid osteoma." Acta radiol., 38:279–293, 1952.

Paul, J. R. A study of an unusual case of myositis ossificans. Arch. Surg., 10:185–195, 1925.

Ponseti, I., and Barta, C. K. Osteoid osteoma. J. Bone & Joint Surg., 29:767–776, 1947.

Porretta, C. A., Dahlin, D. C., and Janes, J. M. Sarcoma in Paget's disease of bone. J. Bone & Joint Surg., 39–A:1314–1329, 1957.

Price, C. H. G. The grading of osteogenic sarcoma. Brit. J. Cancer, 6:46–68, 1952.

Rosenkrantz, J. A., Wolf, J., and Kaicher, J. J. Paget's disease (osteitis deformans). Review of one hundred eleven cases. A.M.A. Arch. Int. Med., 90:610–633, 1952.

Fig. 128

PAROSTEAL SARCOMA

Figure 128. Roentgenogram of a resected specimen of parosteal osteosarcoma. This illustrates well the cortical and extracortical nature of the tumor. Tumor is seen on both sides of the bone, thus indicating the enveloping character of the lesion. The medullary cavity appears uninvolved. (From the Armed Forces Institute of Pathology.) A. F. I. P. Acc. No. 166140 (26101).

PAROSTEAL SARCOMA

(Figures 129–132 are from the same case*)

Figure 129. Roentgenogram of a parosteal sarcoma of the proximal portion of a tibia in a 54-year-old woman. W.U. 57–5273; A. F. I. P. Acc. No. 218757–176.

Figure 130. Roentgenogram 10 months later revealed a more densely sclerotic tumor. W.U. 57–5274; A. F. I. P. Acc. No. 218757–389.

Figure 131. Histologic section from a biopsy of this lesion. The fibrous stroma and well formed bone of this portion of the section are benign in appearance. Hematoxylin and eosin stain. X 200. A. F. I. P. Acc. No. 218757–63.

Figure 132. In another portion of the section, the stroma has characteristics of a malignant neoplasm. Formation of bone, seemingly arising from the stroma, is seen. It is apparent that from some biopsies of this lesion misinterpretation could lead to a diagnosis of benign bone tumor. Hematoxylin and eosin stain. X 195. A. F. I. P. Acc. No. 218757–65.

---

*Courtesy of Dr. A. E. Lubchenco, Denver, Colo.

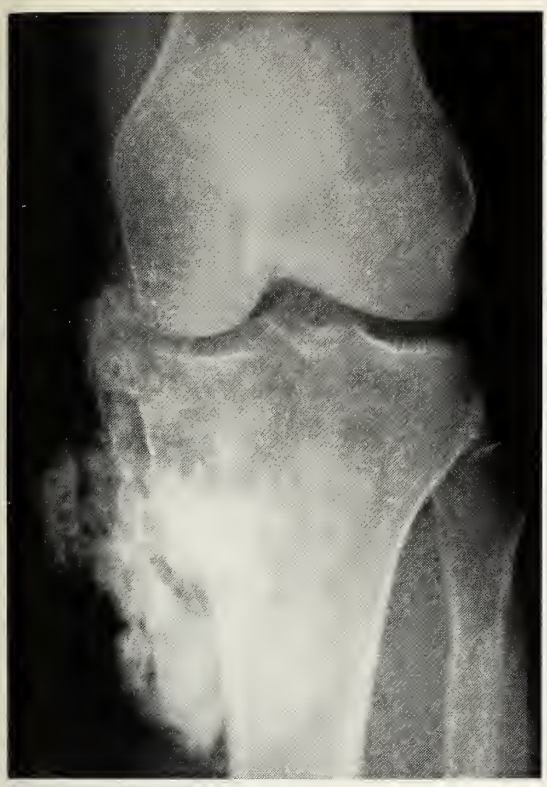

Fig. 129

Fig. 130

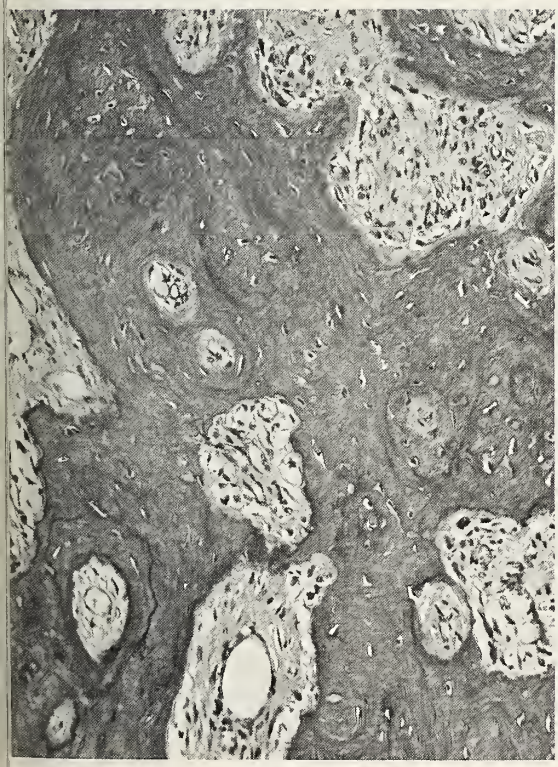

Fig. 131

Fig. 132

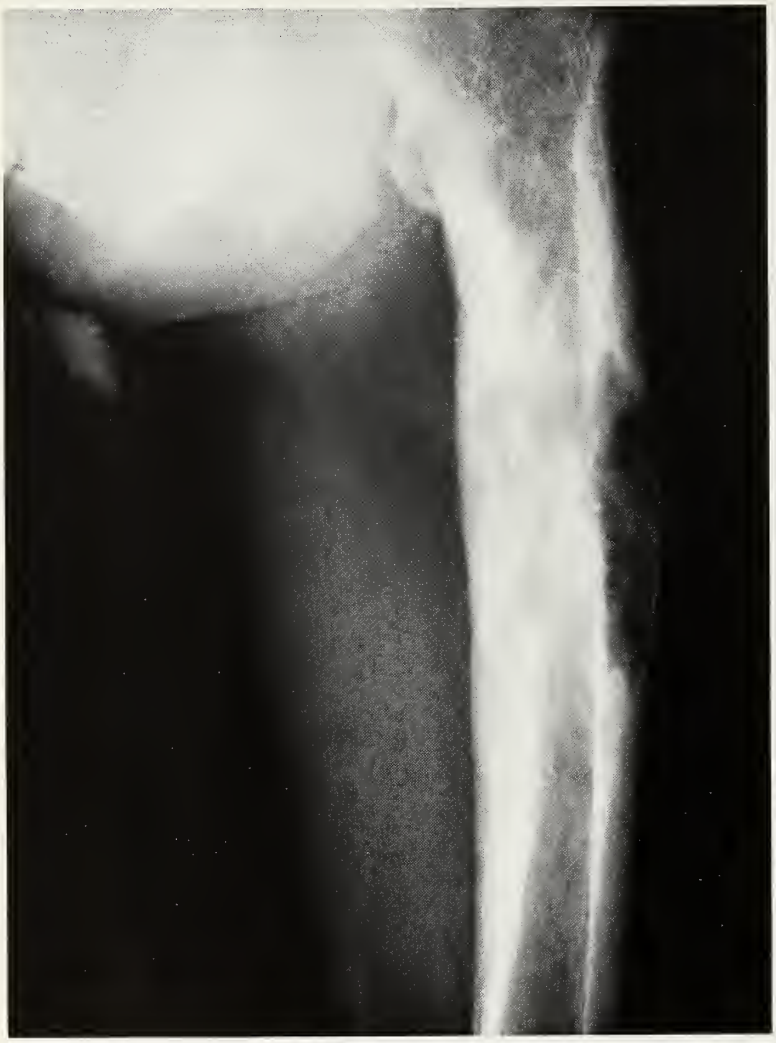

Fig. 133

Fig. 134

SARCOMA ARISING IN PAGET'S DISEASE

Figure 133. Roentgenogram of an osteosarcoma arising in Paget's disease of a femur. Cortices are remarkably thickened, and the medullary portion of the bone exhibits marked sclerosis. W.U. 57–6450; A. F. I. P. Acc. No. 218757–179.

Figure 134. Roentgenogram illustrating Paget's disease of a tibia in a 62-year-old man. The patient had had deformity of the lower leg for 20 years. During the year prior to biopsy, there had been pain. This lesion apparently was monostotic. W.U. 51–3657; A. F. I. P. Acc. No. 218757–180.

Fig. 135

Fig. 136

SARCOMA ARISING IN PAGET'S DISEASE

(Figures 135 and 136 are from the same case)

Figure 135. Sagittal section of Paget's disease of a tibia. A greatly thickened cortex and sclerosis of the medullary cavity are evident. W.U. 55-6406; A. F. I. P. Acc. No. 218757-181.

Figure 136. This specimen, when magnified approximately three times, shows the thickened bony trabeculae of cortical and medullary bone characteristic of Paget's disease. W.U. 55-6405; A. F. I. P. Acc. No. 218757-182.

SARCOMA ARISING IN PAGET'S DISEASE

(Figures 137 and 138 are from the same case*)

Figure 137. Macerated specimen of the third lumbar vertebra of a 77-year-old man demonstrates coarse bony trabeculae of an advanced Paget's disease. Many other bones were involved by the disease. A. F. I. P. Acc. No. 218757–183.

Figure 138. Sagittal section of the body and manubrium of a sternum. The manubrium in the right portion of the photograph is normal. However, the left half illustrates the thickened bony trabeculae and mosaic pattern characteristic of Paget's disease. A. F. I. P. Acc. No. 218757–184.

---

*From Collins, D. G. Paget's disease of bone. Lancet, 2:51–57, 1956. Figures 5 and 12 are fascicle figures 137 and 138.

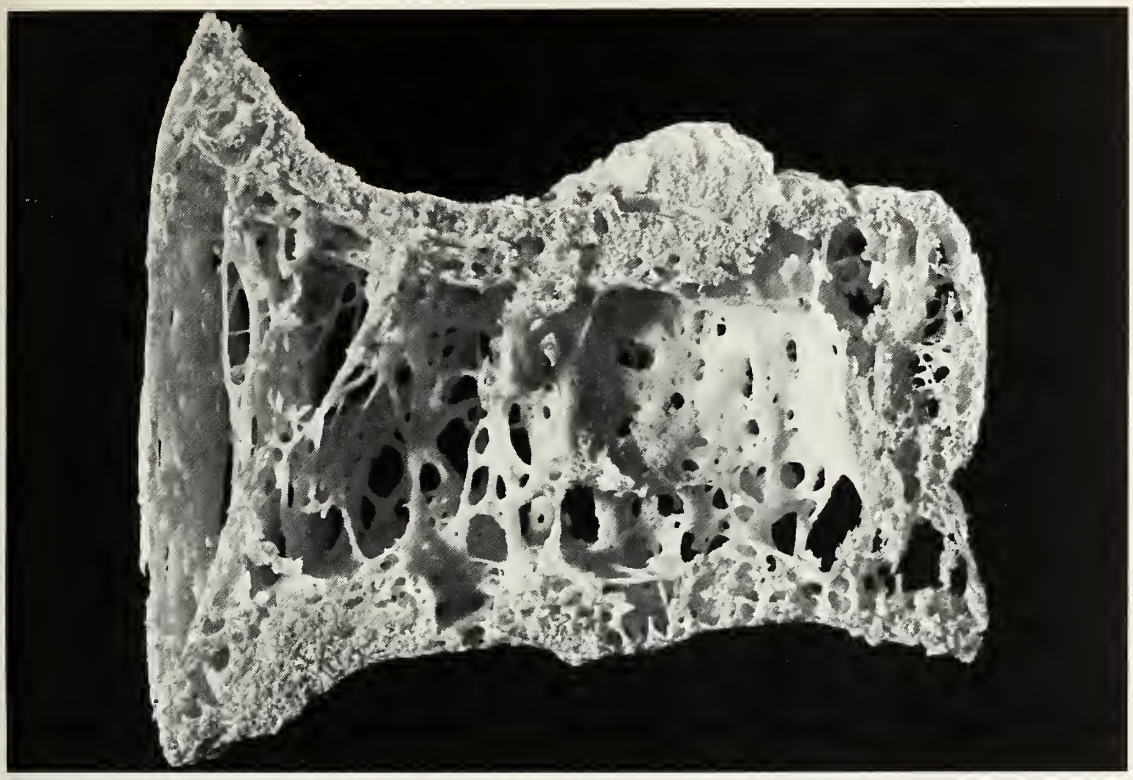

Fig. 137

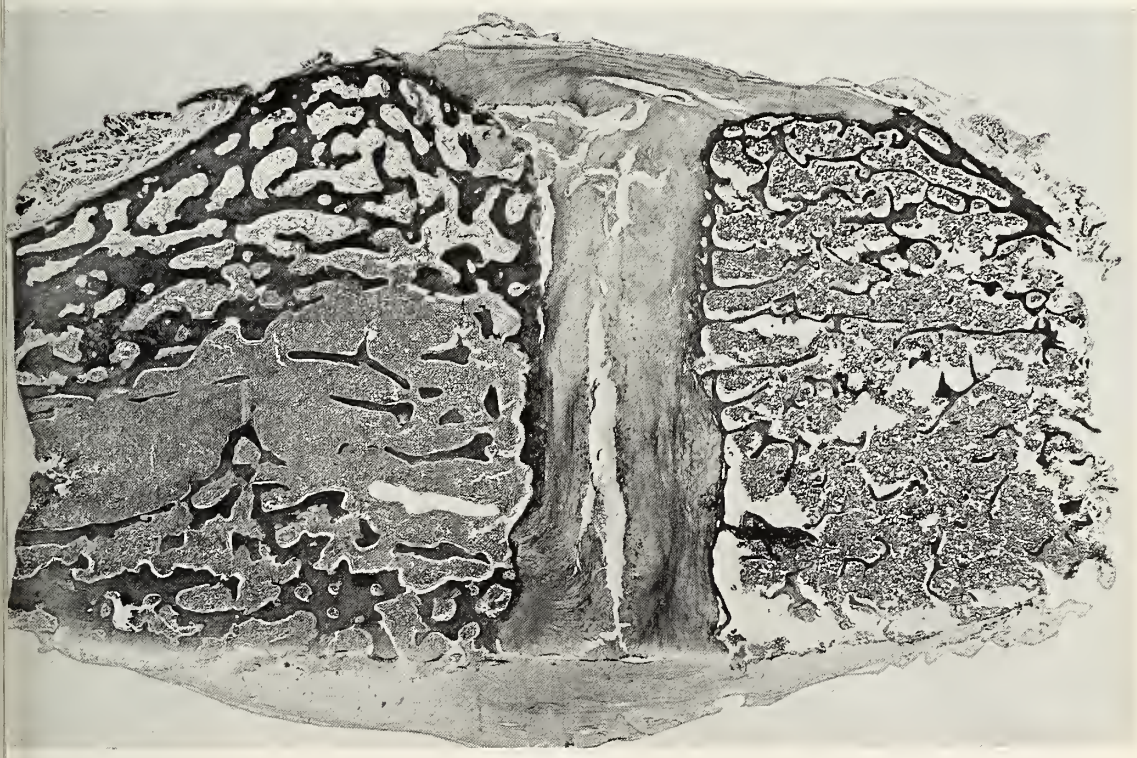

Fig. 138

Sabanas, A. O., Dahlin, D. C., Childs, D. S., Jr., and Ivins, J. C. Postradiation sarcoma of bone. Cancer, 9:528–542, 1956.

Sherman, M. S. Osteoid osteoma. Review of the literature and report of thirty cases. J. Bone & Joint Surg., 29:918–930, 1947.

Sherman, R. S., and Soong, K. Y. A roentgen study of osteogenic sarcoma developing in Paget's disease. Radiology, 63:48–58, 1954.

Snapper, I. Medical Clinics on Bone Diseases. 2nd ed. New York: Interscience Publishers, Inc., 1949.

Stauffer, H. M. Osteoid-osteoma of the head of the radius. Case report. Am. J. Roentgenol., 52:200–202, 1944.

Stevens, J., and Lennox, B. Long survival after amputation for Paget's sarcoma of bone. J. Bone & Joint Surg., 40–B:735–739, 1958.

Summey, T. J., and Pressly, C. L. Sarcoma complicating Paget's disease of bone. Ann. Surg., 123:135–153, 1946.

Tudway, R. C. The place of external irradiation in the treatment of osteogenic sarcoma. J. Bone & Joint Surg., 35–B:9–21, 1953.

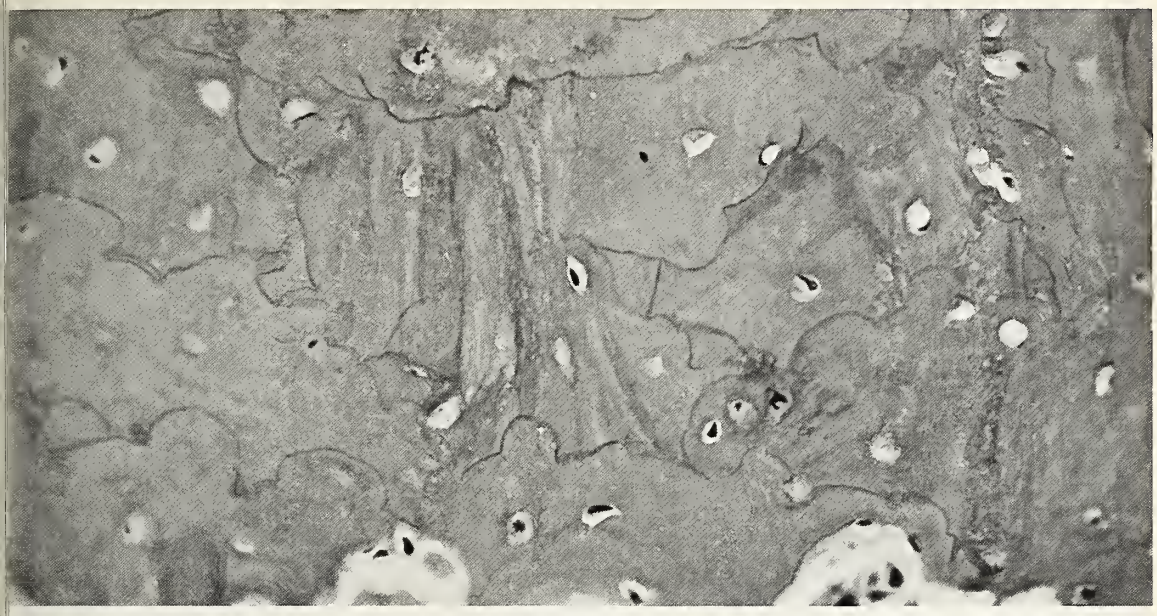

Fig. 139

Fig. 140

SARCOMA ARISING IN PAGET'S DISEASE

Figure 139. Histologic section showing the typical mosaic pattern of bone diagnostic of Paget's disease. Hematoxylin and eosin stain. X 400. W.U. 50-3839A; A. F. I. P. Acc. No. 218757-185.

Figure 140. This section demonstrates the relationship of bone to the fibrous component in Paget's disease. Dissolution of bone appears to have occurred. Hematoxylin and eosin stain. X 250. A. F. I. P. Acc. No. 218757-35.

SARCOMA ARISING IN PAGET'S DISEASE

(Figures 141–143 are from the same case)

Figure 141. Thickened bony trabeculae lined by osteoblasts are shown in this histologic section from a femur of a 64-year-old man. Osteosarcoma is associated with the Paget's disease but is not demonstrated in this photomicrograph. Hematoxylin and eosin stain. X 119. B.H. 57–1823; A. F. I. P. Acc. No. 218757–186.

Figure 142. This photomicrographic field shows an undifferentiated sarcoma arising in Paget's disease. Areas of osteoid were noted in other blocks to augment the diagnosis of osteosarcoma. Hematoxylin and eosin stain. X 180. B.H. 57–1823; A. F. I. P. Acc. No. 218757–187.

Figure 143. Higher power microscopic view. Hematoxylin and eosin stain. X 660. B.H. 57–1823; A. F. I. P. Acc. No. 218757–188.

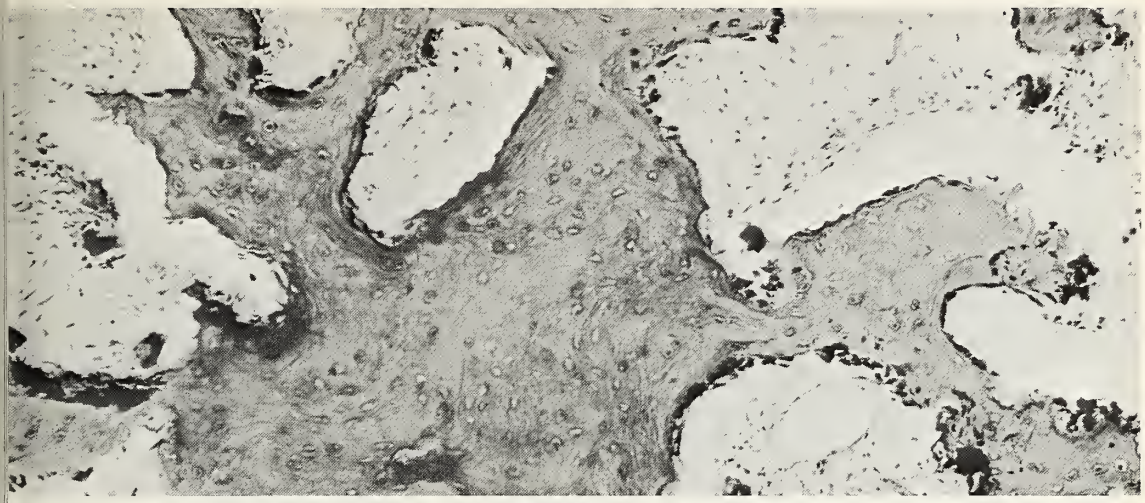

Fig. 141

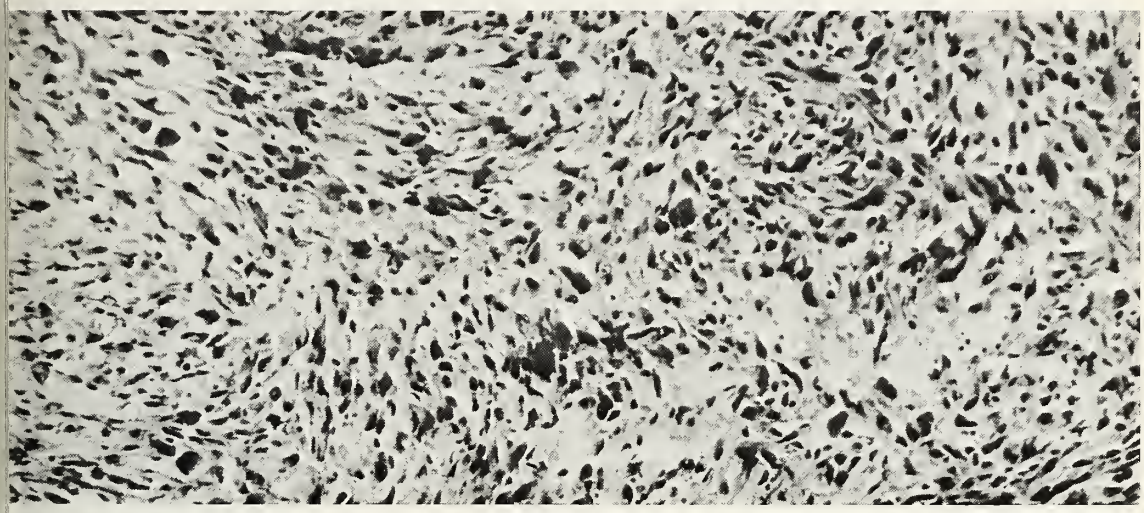

Fig. 142

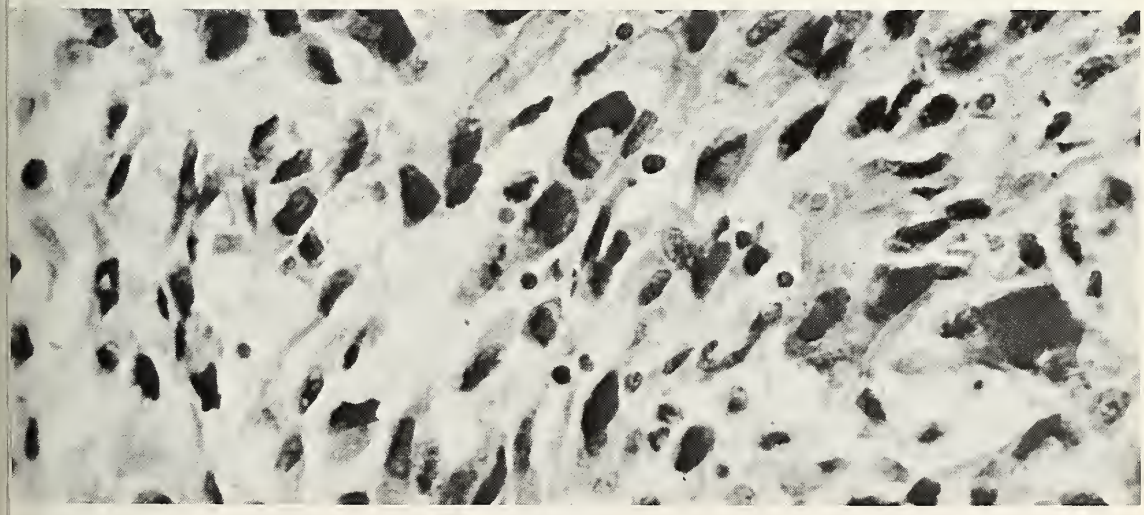

Fig. 143

SARCOMA ARISING IN PAGET'S DISEASE

(Figures 144–146 are from the same case*)

Figure 144. Hemisection of an osteosarcoma from the distal portion of a humerus of a 70-year-old man with Paget's disease. The shaft shown displays irregular cortical thickening. Cystic conformation and the extraosseous component are outstanding features in this tumor. A. F. I. P. Acc. No. 218757–343.

Figure 145. Multinucleated giant cells, osteoid, and a malignant stroma are the histologic features of osteosarcoma demonstrated in this section. Hematoxylin and eosin stain. X 275. W.U. 58–5017; A. F. I. P. Acc. No. 218757–344.

Figure 146. Another photomicrographic field of this lesion. Hematoxylin and eosin stain. X 275. W.U. 58–5018; A. F. I. P. Acc. No. 218757–345.

---

*Courtesy of Dr. E. Uehlinger, Zurich, Switzerland.

Fig. 144

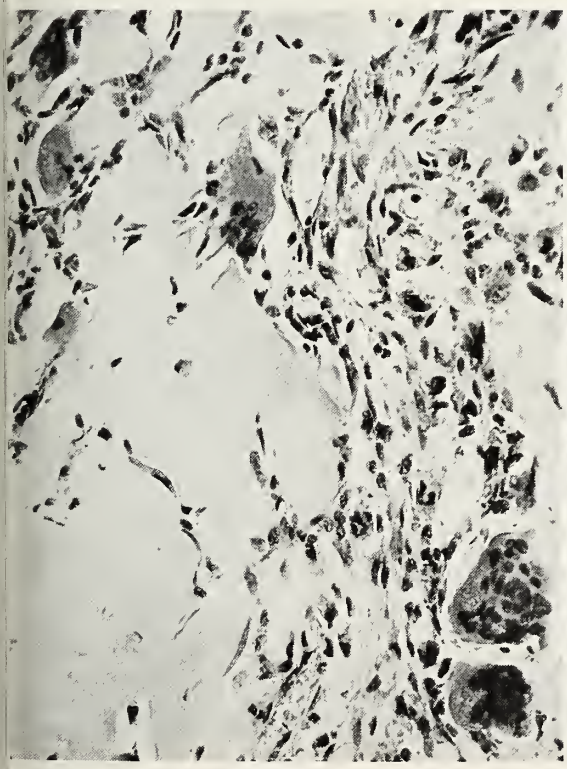

Fig. 145

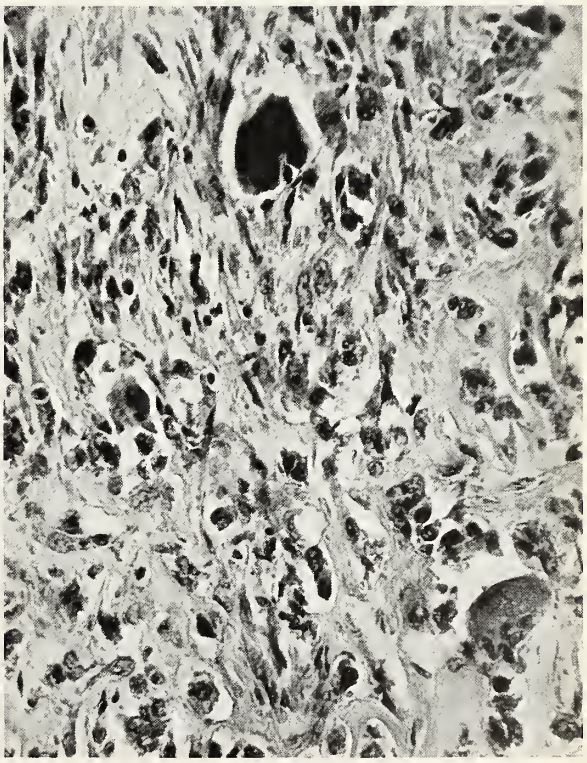

Fig. 146

SARCOMA ARISING IN IRRADIATED BONES

Figure 147.* Photomicrograph illustrating experimentally induced irradiation effect on the bone of an extremity of a rat that had received Ca^{45} for 10 consecutive days, 3.5 micrograms/gm. of body weight. The presence of nonviable bone is noted with associated atypical stroma and bone formation. The unusual fibrillar changes of the marrow connective tissue and fat are histologic features of radiation osteitis. Hematoxylin and eosin stain. X 115. W.U. 58–6385; A. F. I. P. Acc. No. 218757–346.

Figure 148.* The rat from whose bone this section was made had received 0.5 microgram/gm. of body weight of Sr^{89} for 10 consecutive days. The bone shows changes which we consider characteristic of irradiation effect. There is necrosis of bone and bone formation; at the periphery, the atypical osteoid and stromal proliferation suggest osteosarcoma. It is often difficult to ascertain whether atypical changes such as these should still be considered benign or malignant. Hematoxylin and eosin stain. X 130. W.U. 58–6386; A. F. I. P. Acc. No. 218757–347.

Figure 149.* The rat from whose bone this section was made had received 1 microgram/gm. of body weight of Sr^{89} for 10 consecutive days. The photomicrograph illustrates a typical osteosarcoma. Hematoxylin and eosin stain. X 170. W.U. 58–6387; A. F. I. P. Acc. No. 218757–348.

---

*Courtesy of Dr. J. F. Kuzma, Milwaukee, Wis.

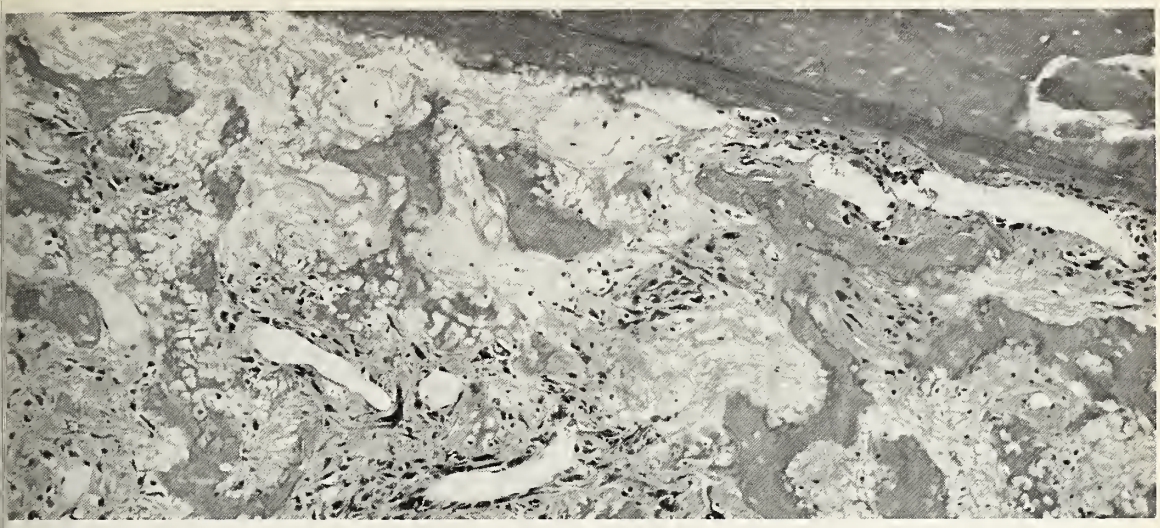

Fig. 147

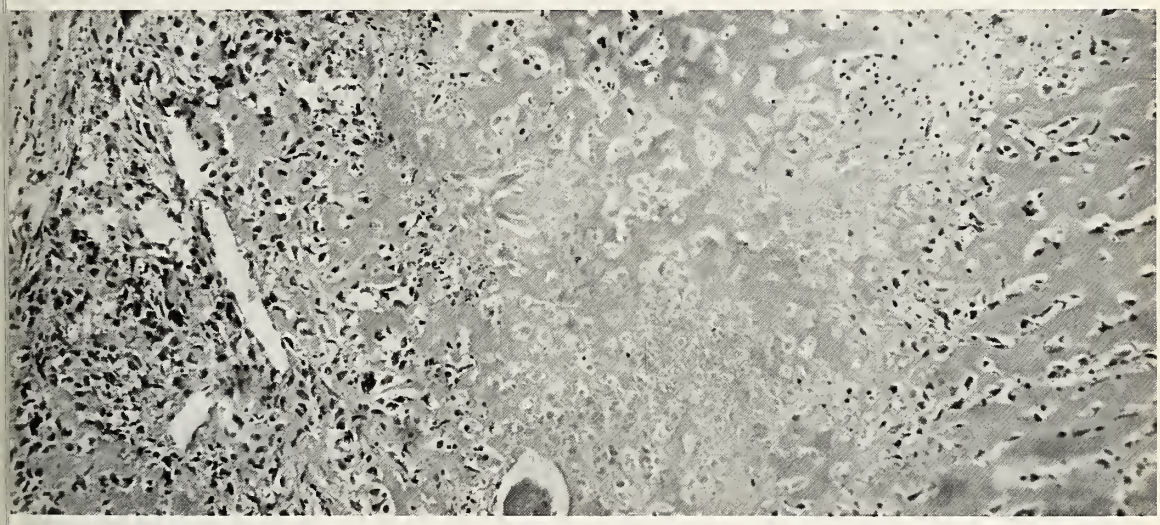

Fig. 148

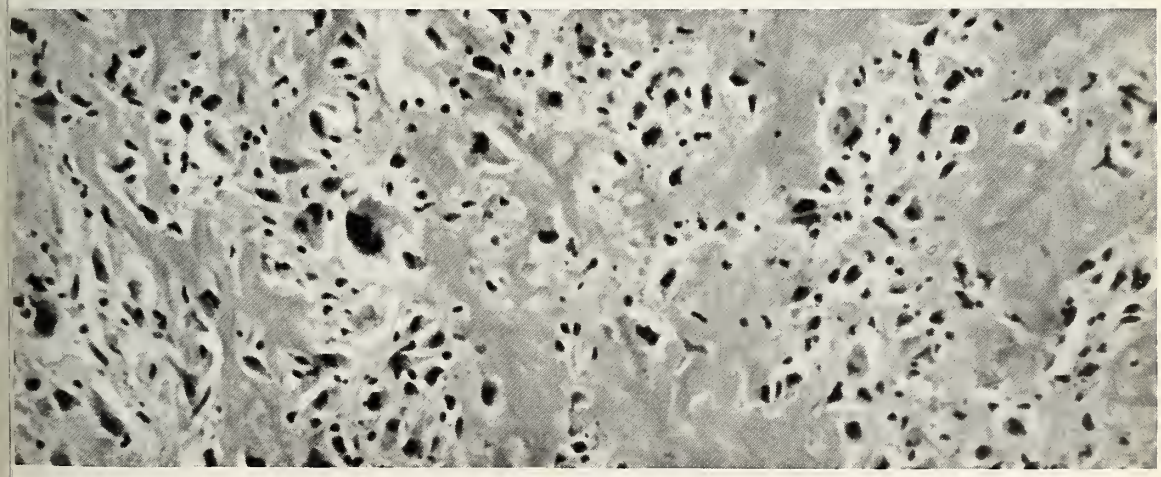

Fig. 149

SARCOMA ARISING IN IRRADIATED BONES

(Figures 150–153 are from the same case*)

Figure 150. Photomicrograph illustrating appositional bone formation, irregular bony trabeculae, and increase in number of fibroblasts in the marrow spaces of a bone; the patient had received radiation therapy to this bone several years previously. Hematoxylin and eosin stain. X 275. W.U. 58–6094; A. F. I. P. Acc. No. 218757–349.

Figure 151. Active bone formation, spiculation of bone, and a more cellular, but nonmalignant, fibrous stroma can be noted in another field of the section. Hematoxylin and eosin stain. X 250. W.U. 58–6095; A. F. I. P. Acc. No. 218757–350.

Figure 152. Vascular fibrous stroma is shown to contain scattered atypical hyperchromatic nuclei. Again (fig. 148), histologic malignancy cannot be dogmatically ascertained in experimentally and therapeutically irradiated bones. Perhaps areas such as these are transitions between the benign and malignant states. Hematoxylin and eosin stain. X 500. W.U. 58–6096; A. F. I. P. Acc. No. 218757–351.

Figure 153. Photomicrograph illustrating a richly cellular stroma, the cells of which have bizarre nuclei. Similar areas are compatible with a diagnosis of fibrosarcoma. Hematoxylin and eosin stain. X 650. W.U. 58–6093; A. F. I. P. Acc. No. 218757–352.

---

*Courtesy of Dr. F. W. Stewart, New York, N.Y.

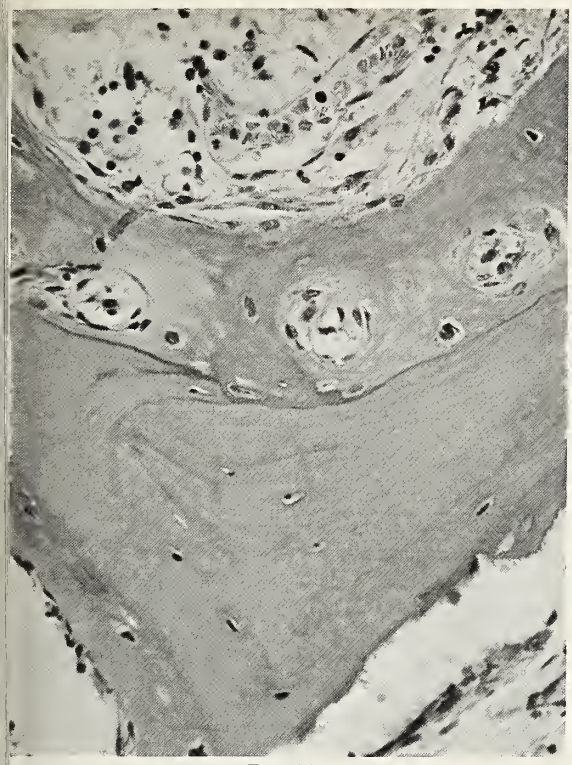

Fig. 150

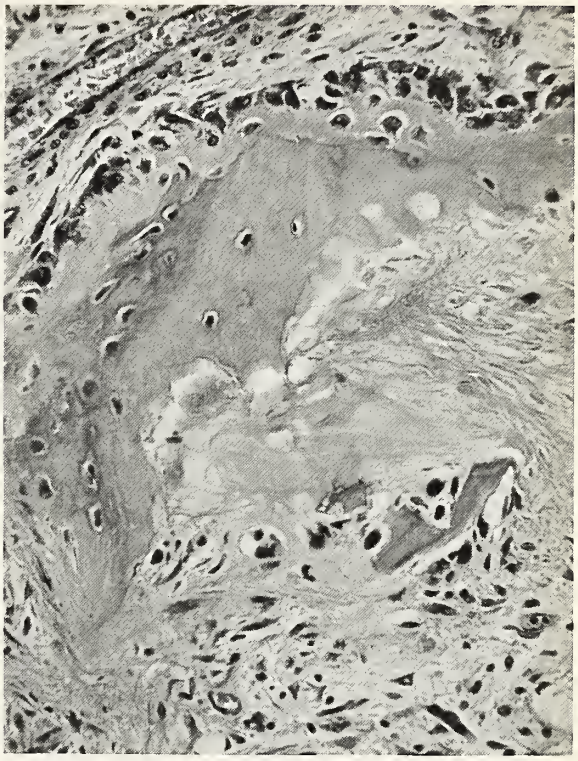

Fig. 151

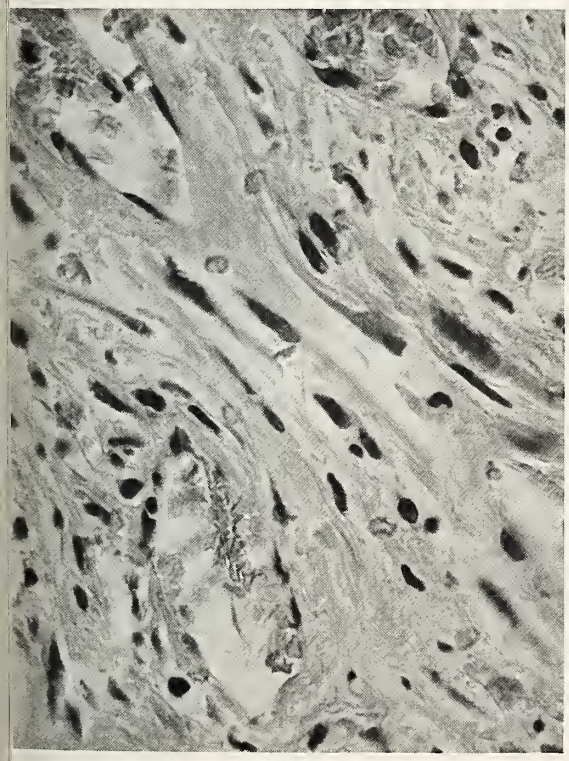

Fig. 152

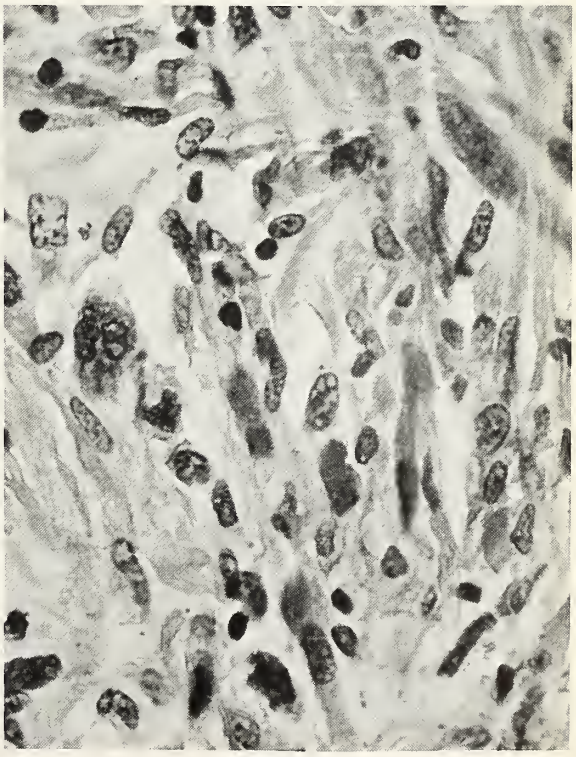

Fig. 153

SARCOMA ARISING IN IRRADIATED BONES

(Figures 154–156 are from the same case*)

Figure 154. Roentgenogram of the left hip and pelvis of a 48-year-old woman who had painted watch dials for nearly 30 years; she had tipped the paint brush with her lips during the first two years. It is of interest to note that the radiographic changes indicating radium deposition were seen not only in the head of the left femur shown here, but also in the left tibia, fibula, and metatarsals and the skull, radii, and ulnae.

The patient had had carcinoma of the cervix diagnosed. This was treated by radium implantation and pelvic roentgen ray therapy nine months prior to the roentgenogram. Therefore, the destructive lesion of the ischial tuberosity was initially treated as a metastasis. Upon re-evaluation, however, it was considered a primary sarcoma, and hemipelvectomy was performed. A. F. I. P. Acc. No. 218757–353.

Figure 155. Gross specimen of this tumor shows a fibrosarcoma. Total body burden of radium in this patient was calculated as 1.3 micrograms. A. F. I. P. Acc. No. 218757–354.

Figure 156. This field of a histologic section of the tumor shows a cellular fibrosarcoma similar to fibrosarcoma that might arise in patients who have not had radiation therapy. Hematoxylin and eosin stain. X 600. W.U. 58–6091; A. F. I. P. Acc. No. 218757–355.

---

*Courtesy of Dr. C. H. Hatcher, Palo Alto, Calif.

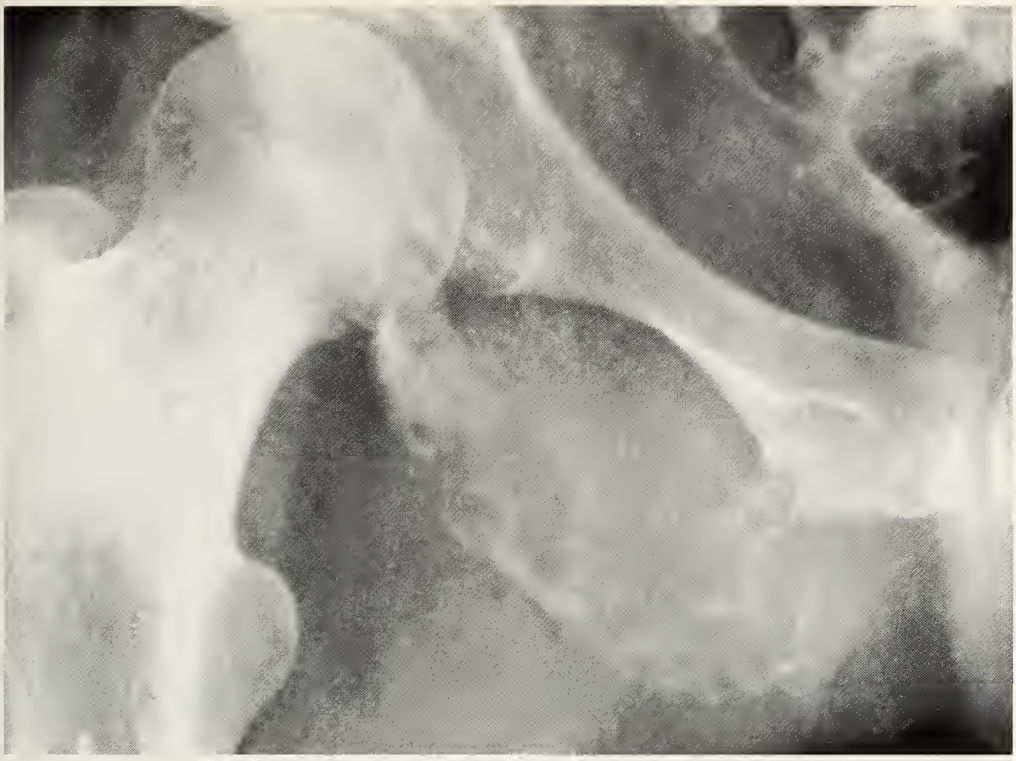

Fig. 154

Fig. 155

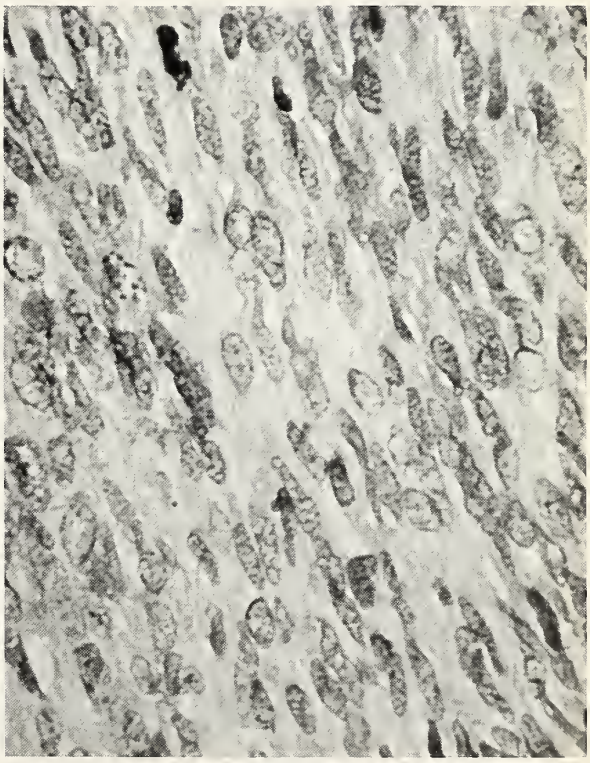

Fig. 156

SARCOMA ARISING IN IRRADIATED BONES

(Figures 157 and 158 are from the same case.* Figures 159 and 160 are from the same case*)

Figure 157. Roentgenogram of the left shoulder of a 9-year-old girl who, between the ages of 12 to 18 months, received radiation therapy for a cystic mass on the left side of the neck and thorax. Biopsy of this mass was interpreted as lymphangioma when the patient was nine years of age.

This radiograph was interpreted as showing retardation of growth of the bones by an osteochondroma of the upper end of the humerus. A. F. I. P. Acc. No. 218757–356.

Figure 158. Roentgenogram five years later illustrated an advanced inoperable osteosarcoma of the clavicle. Diagnosis was confirmed by aspiration biopsy. A. F. I. P. Acc. No. 218757–357.

Figure 159. Roentgenogram of the left knee of a 30-year-old man outlines a lesion interpreted as giant cell tumor. Biopsy was not performed, but radiation therapy was given. A. F. I. P. Acc. No. 218757–358.

Figure 160. Roentgenogram 21 years after radiation therapy shows alterations that were interpreted as consistent with postradiation sarcoma. Aspiration biopsy of the mass confirmed the diagnosis, and an above-the-knee amputation was carried out. A. F. I. P. Acc. No. 218757–359.

---

*From Cruz, M., Coley, B. L., and Stewart, F. W. Postradiation bone sarcoma. Report of eleven cases. Cancer, 10:72–88, 1957. Figures 9, 10, 5, and 7 are fascicle figures 157–160.

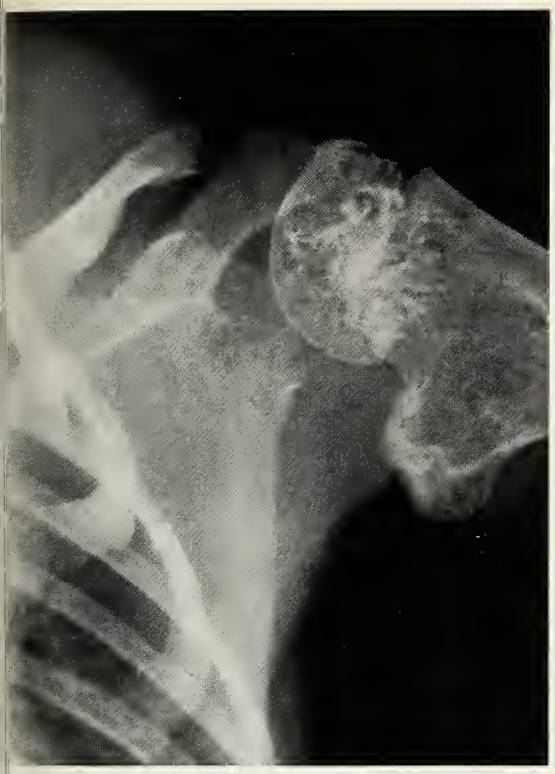

Fig. 157

Fig. 158

Fig. 159

Fig. 160

TUMORS OF MARROW ORIGIN—PRIMARY BENIGN AND MALIGNANT

TUMORS ARISING FROM HEMATOPOIETIC ELEMENTS

Plasma Cell Myeloma

SYNONYMS AND RELATED TERMS: Myeloma; plasmacytoma.

DEFINITION. A malignant process usually arising from plasma cells of the bone marrow, but which may arise in extraosseous sources.

CLINICAL DATA. A small percentage of plasma cell myelomas is first seen clinically as an extramedullary tumefaction. However, at the time of discovery of the lesion in such areas as the nasopharynx, soft palate, and nasal fossa, the disease may: already have been present within bones; not make itself manifest within the next two years; rarely lie dormant five or more years before the bone lesions appear (Jaeger; Stout and Kenney).

Distinction is made by Fruhling and Chadli between diffuse and nodular forms of the disease. They suggest that the nodular form is easily recognized radiographically from "punched-out" areas but that the diffuse form causes so little destruction of bone that its radiographic recognition is difficult. In instances when diagnosis is suggested radiographically, bone survey may show multiple areas of bone destruction involving vertebrae, skull, and ribs; such changes are difficult to distinguish from metastatic carcinoma. However, lesions which are apparently single and involve long bones may simulate not only metastatic carcinoma but also fibrous dysplasia or giant cell tumor. We doubt the existence of a single focus of myeloma in bone and believe that, in time, patients with such lesions develop a terminal disseminated disease.

When the patient seeks medical advice because of bone pain and an area of osteolytic destruction is observed as described, diagnosis can be made by biopsy. Plasma cell myeloma is one of few malignant lesions involving bone in which blood chemical abnormalities also may prove helpful in making the diagnosis.

Electrophoretic analysis of the serum of patients having plasma cell myeloma is a laboratory aid used in identifying hyperglobulinemia, the abnormal protein usually found in the gamma fraction. However, hyperglobulinemia frequently is not present in the apparently primary medullary tumor. Bence Jones protein and cryoglobulins may be found in the urine and reflect renal damage.

Plasma cell myeloma has male predominance; in our group of patients there were 60 men and 30 women. Usual age for the disease is 50 to 70 years; the youngest patient in our series was 25 years old. This tumor has rarely been reported as occurring in children or adolescents (Slavens).

PATHOGENESIS. We believe that the plasma cell has its origin in the reticuloendothelial system. Of the small percentage of plasma cell myelomas first seen clinically as extramedullary tumefactions, a high percentage arises

in the upper respiratory tract or oral cavity; they apparently may occur primarily in other locations (Carson et al.), however.

GROSS. Many patients with plasma cell myeloma are first seen in orthopedic surgery with apparent involvement of only one, or perhaps more than one, bone. The involved bones usually show lytic lesions, more than 50 percent associated with pathologic fracture (figs. 163, 164). Most commonly in order of frequency these involved bones are: vertebra, rib, skull, pelvis, femur, clavicle, and scapula (table I).

Table I

PRINCIPAL SITES OF BONY INVOLVEMENT IN 78 PATIENTS WITH MYELOMA AND PRIMARY BONY INVOLVEMENT

Bone Involved	Cases		No. with Pathologic Fractures
	Number	Percent	
Vertebral Column	52	66	32
Rib	35	44	8
Skull	32	41	.....
Pelvis	22	28	1
Femur	19	24	2
Clavicle	11	14	.....
Scapula	10	12	.....
Humerus	9	11	2
Sternum	5	6	1
Mandible	3	3	.....
Tibia, fibula, radius (1 each)	3	3	.....

This table is adapted from table I in Carson, C. P., Ackerman, L. V., and Maltby, J. D. Plasma cell myeloma. Am. J. Clin. Path., 25:849–888, 1955.

Since resection of bones replaced by myeloma is done infrequently, tissue submitted to the surgical pathologist usually is from biopsy or curettement of a mass; these specimens consist of reddish gray and obviously highly cellular material. In rare instances, however, apparent solitary lesions of bone have been resected, particularly when the bone involved showed a localized process and resection would result in no disability. In such cases, the bone may have been expanded but with a thin cortex which demonstrated a fracture.

Many of the patients with plasma cell myeloma are autopsied, and gross descriptions of the lesions are made at that time (fig. 161). Involvement of most bones of the axial skeleton may be noted (fig. 162), particularly a homogeneous thinning of some or all of the vertebrae. Extensive replacement of ribs by the disease process and multiple fractures of these and long bones may be present

(figs. 163–165). Sections of these easily cut bones show diffuse grayish red and hemorrhagic tumorous replacement. However, renal insufficiency or bronchopneumonia may be determined as the immediate cause of death.

MICROSCOPIC. The more mature and predominant myeloma cell appears similar to the normal plasma cell (figs. 167–170). Its most prominent characteristic is the eccentric position of its nucleus. This is usually round, but occasionally oval, and possesses a well defined limiting membrane. Its chromatin stains dark with hematoxylin and eosin and is clumped into small particles which are scattered through all parts of the nucleus. The "wheel-spoke" arrangement is not usually present, but sometimes one or more nucleoli may be seen. Cytoplasm in the stained smears of aspirated marrow is basophilic; in tissue sections stained with hematoxylin and eosin, it is eosinophilic or palely basophilic. Fine granulation of the cytoplasm is sometimes noted.

Less mature cells tend to show an absolute increase in cytoplasmic and nuclear bulk, although the ratio of cytoplasm to nucleus is often decreased (fig. 166). Scattered throughout some of the tumors are cells similar to, but larger than, those described in the preceding paragraph.

Still younger cells exhibit more prominent changes, notably an increase in size of the nucleus and loss of its eccentric position. They are round, oval, or bean shaped. Chromatin becomes less clumped and, in the youngest cellular forms, may be seen as a fine meshlike network. Nucleoli are sometimes present, occasionally quite large, and have been seen to occupy almost the entire nucleus (Bayrd). Paranuclear clear zones, or demilunes, occasionally form a partial arc around the nucleus.

The presence of double or triple nuclei in some cells is helpful in establishing the diagnosis of plasma cell myeloma, although these are not the only lesions in which multinucleated plasma cells have been seen. Even though more than three nuclei are rare, Herbut and Erf recorded a case in which the cells contained as many as 20 nuclei. Mitotic figures also are rare and, as others have noted (Erf and Herbut; Newman et al.), their presence is usually of ominous significance. Cytoplasm is eosinophilic or lightly basophilic in sections stained with hematoxylin and eosin, while the deeply basophilic staining reaction seen in plasma cells involved in some chronic inflammatory processes is not noted. Vacuolization of the cytoplasm is more prominent in the less mature cells, although it is sometimes also seen in the mature cells. Cytoplasmic inclusions of apparently protein nature have been seen chiefly in the less mature cells (Lichtenstein and Jaffe, 2nd reference) but also in others. Russell bodies, or these intracytoplasmic eosinophilic hyaline inclusions, are found not only in the plasma cells, myeloma cells, and reticulum cells about margins of malignant tumors, but also in some chronic inflammatory reactions, and in intestinal tracts of certain animals (Lisco). We have not found them helpful in establishing a diagnosis of plasma cell myeloma.

In 1948 Pearse, using periodic acid—Schiff stain, studied these inclusions and noted (p. 85): "The substance of which the bodies are composed is unaffected by ribonuclease, diastase, or hyaluronidase, fails to bind methylene blue at pH6, and is devoid of metachromatic properties." He concluded that these were mucoproteins and suggested that they were polysaccharides containing globulins (glycoglobulins and mucoglobulins). He believed that Russell bodies, as well as Kurloff bodies found in guinea pig lymphocytes, are secretion products of the parent cell. Dark basophilic granules have also been seen in the cytoplasm after stilbamidine therapy (Snapper, 1947; Snapper et al.). Snapper and associates have shown that these granules apparently represented stilbamidine conjugated with ribose nucleic acid in the cytoplasm of the myeloma cell.

TREATMENT. In patients in whom this malignant process apparently begins in an extramedullary site or in whom there is an apparent single focus of tumor in bone, clinical duration may be long and local radiation therapy may be temporarily successful. Our study of lesions of plasma cell myeloma which have been locally irradiated has demonstrated that such foci can be completely destroyed by radiation therapy (figs. 165, 166).

Myeloma also may present as a plasma cell leukemia, an entity described in detail by Rappaport (see Fascile 8, "Tumors of the Hematopoietic System"). When possible, this process is also treated by local radiation therapy. In disseminated lesions, irradiation may be satisfactorily palliative. Of the drugs, urethane has proved the most effective in treatment of patients with disseminated plasma cell myeloma.

PROGNOSIS. This malignant process progresses gradually to involve many bones and different organs, eventually causing death of the patient. Time required for progression is short when measured from diagnosis of multiple lesions, for in 60 patients, only 7 survived two years (Carson et al.).

"Pseudo-plasma cell myeloma" (plasma cell granuloma) is one of many lesions containing large masses of plasma cells which has been designated as benign solitary myeloma (Johnson). This is a rare lesion of bone and should not be mistaken for plasma cell myeloma. When patients treated by varieties of methods have been cited in the literature as cured of plasma cell myelomas, it is likely that they did not have true plasma cell myelomas. We have seen these granulomas in innumerable locations including conjunctiva, oral cavity, mediastinum, lung, stomach, kidney, thyroid, and bone. However, since conjunctival lesions have long been described erroneously as single focus plasma cell myelomas when they are granulomas, we feel that a true plasma cell myeloma arising from the conjunctiva has not been reported. In the stomach, liver, or kidney, a chronic process of relatively long duration may form such pseudotumor-like masses that also may be diagnosed incorrectly on microscopic examination as plasma cell myeloma.

In chronic inflammatory processes in the oral cavity, plasma cell response is often present and may take the form of a small nodule or mass. A form of chronic osteomyelitis designated as osteomyelitis albuminosa has been reported (Schinz et al.); in this, an extremely prominent plasma cell infiltration was seen by microscopic examination.

Microscopic differentiation between the pseudotumors and true neoplasms may be somewhat difficult. However, the pathologist can suspect the possibility of plasma cell granuloma when the focus is localized and clinical signs and primary location are atypical. Microscopic sections show numerous and invariably uniform plasma cells which frequently contain Russell bodies in the cytoplasm. Most importantly, however, there will be a mingling of plasma cells with the other cells, such as reticulum cells and lymphocytes, frequently seen in a chronic inflammatory process.

Ewing's Sarcoma

SYNONYMS AND RELATED TERMS: Diffuse endothelioma of bone; endothelial myeloma; endothelial sarcoma; Ewing's endothelioma; Ewing's tumor; hemangioendothelioma; omoblastom; primary intracortical and subperiosteal lymphangioendothelioma; solitary diffuse endothelioma.

DEFINITION. A relatively rare tumor arising in the medullary portion of bone.

INCIDENCE. Ewing's sarcoma has been reported as occurring in almost all bones of the body, including small bones of hands and feet and the patella; however these latter locations are rare. Except for extremities, the skull, ribs, and pelvis are the bones most frequently involved.

Bethge has found that over one half (56 percent) of the lesions occur in long tubular bones of the upper and lower extremities. He states that in long bones, the proximal and midportions of the shaft are the commonest sites of the tumor; he further found that when pathologic fractures occur (2 to 5 percent), they also are most frequent in the humerus and femur.

This sarcoma occurs predominantly in the metaphysis or near the midshaft of long bones. However, there also may be wide variations from these locations (Sherman and Soong). For instance, the diaphysis and metaphysis may be involved centrally or eccentrically. Six cases of Sherman and Soong showed extensive involvement of the epiphysis and metaphysis. There were no cases of pure epiphysial localization of Ewing's sarcoma.

CLINICAL DATA. The majority of patients with Ewing's sarcoma complain of pain and swelling in the area of the tumor. Compromised function of the affected part, fever, tenderness, and local heat are other complaints and physical findings. Anemia and increased sedimentation rate may be present. Symptoms have usually been noted for nine months to one year prior to hospital admission. Lichtenstein and Jaffe (1st reference) have observed that patients having no fever, no anemia, and no increase in sedi-

mentation rate at the time of hospital admission tended to have better chance for survival.

Ewing's sarcoma is a disease of childhood and adolescence, occurring most commonly in patients between the ages of 10 and 20 years. Two thirds of the tumors occur before 20 years of age and 88 percent before 30 years. Age range is 5 months to 79 years; however, these age extremes are rare; the youngest patient in our experience was 2 years of age. Women are affected less commonly than men; the ratio is roughly 1:2.

Uehlinger believes that Ewing's sarcoma simulates osteomyelitis clinically but roentgenographically most often suggests sarcoma. He further believes that, by contrast, reticulum cell sarcoma of bone clinically suggests sarcoma but roentgenographically simulates osteomyelitis.

Roentgenographically, Ewing's sarcoma has been well described by Swenson and by Sherman and Soong. While Ewing had felt that roentgenographic studies of the lesion were quite specific, the accumulation of many cases and comparison of them with other bone lesions has made Ewing's sarcoma less specific as a radiographic entity.

Radiographically detectable "onion-skin" pattern of subperiosteal bone formation has been cited as a characteristic, but not specific, feature of Ewing's sarcoma. It results from the reactive bone production secondary to penetration of periosteum by the tumor. Sherman and Soong observed this phenomenon in all Ewing's sarcomas of long bones which they had classified as central diaphysial. Perpendicular bone spiculation also was noted in 50 percent of this same group of cases. However, these periosteal changes are less common in Ewing's sarcoma of other bony sites.

From the roentgenographic standpoint, Ewing's sarcoma of the flat bones has no specific characteristics; some may be osteolytic, others sclerotic, and still others a mixture of the two.

Major portions of a bone may be permeated by Ewings' sarcoma, and the bone is frequently expanded by the tumor. Studies of roentgenograms and intact gross specimens reveal destructive areas as well as foci of bone production. From marrow spaces, the lesion permeates the haversian system of cortical bone, periosteum, and surrounding soft tissues (fig. 175); at least by roentgenographic evidence, the soft tissues are invariably involved (Sherman and Soong). Since it is common for the extent of involvement, as determined by pathologic examination, to be greater than that suspected by roentgenogram (Lichtenstein and Jaffe, 1st reference), these observations have important therapeutic implications.

PATHOGENESIS. Ewing (1921) originally described the tumor as of endothelial origin. Although this concept was restated in his later writings, histogenesis of the tumor still is not well defined. The reticular cell, or primitive form of connective tissue (Stout; Oberling; Lichtenstein and Jaffe, 1st reference), has been suggested as an alternate cell of genesis. However,

regardless of controversy concerning the cell of origin, we believe that Ewing's sarcoma is an entity, for it can be delineated clinically and pathologically from lesions that may be confused with it such as reticulum cell sarcoma, plasma cell myeloma, osteosarcoma, metastatic neuroblastoma, metastatic undifferentiated carcinoma of the lung, and eosinophilic granuloma.

The tumor seems to arise in the marrow cavity (pl. V–C; figs. 173, 174), or at least to have its earliest manifestations there, according to roentgenographic studies and dissections of intact specimens. In fact, we have seen a case of Ewing's sarcoma with a very small bony component and an extremely large soft tissue mass.

GROSS. Though the actual tumor is soft, or may sometimes be liquid, a fibrous or bony constituent often gives it substance. It is gray to gray-white or gray-red and glistens with areas of hemorrhagic necrosis which often are seen. Extensive necrosis is thought to perhaps account for sudden rapid growth of the tumor and occasional cysts noted in this lesion. One case that we have seen (fig. 174) was only a hemorrhagic cavity, according to the surgeon. By curetting the wall of the cavity, he secured material for the biopsy which was microscopically characteristic of Ewing's sarcoma.

There is similarity of the pathology of the primary lesion to metastases of Ewing's sarcoma, except that neither bone nor cartilage has been encountered in the latter either by gross or microscopic examination.

MICROSCOPIC. Interpretation of a biopsy from Ewing's sarcoma may be difficult because of (1) histologic similarity of the lesion to other neoplastic and non-neoplastic diseases; (2) the tendency of the tumor to undergo necrosis and hemorrhagic destruction; biopsies from such areas, containing only a few viable cells, are unsatisfactory for confident diagnoses.

However, diagnosis often can be based partly upon exclusion of other lesions (such as neuroblastoma, reticulum cell sarcoma, or metastatic undifferentiated carcinomas) by use of pertinent histologic features, roentgenographic findings, and clinical data.

Ewing's sarcoma is composed of small, rounded, closely packed cells which are 2 to 3 times the size of lymphocytes (figs. 181, 182). They form dense sheets, or sometimes cords or nests (fig. 179). Nests of tumor cells with intervening fibrous septa are quite characteristic (fig. 176). Mitoses are present but not abundant. The cell membrane, although described as distinct by Ewing, is indistinct according to most observers and in our experience (fig. 180). The amount of cytoplasm varies but in general is scant. Nuclei are moderately basophilic with distinct nuclear membranes. Nuclear outlines conform to cell outlines; few nucleoli are seen (figs. 171, 172).

The tumor has a rich vascular background; tumor cells tend to congregate about vessels to impart a rosette-like pattern. Stout is not convinced

that these pseudorosettes are formed on the basis of tumor surviving in areas of degeneration, as many pathologists have suggested; to him they remain unexplained.

Reticulin is not demonstrable in zones of actual tumor, although it may be seen around blood vessels or in fibrous trabeculae (fig. 180). Bone and cartilage may form in the tumor but are uncommonly observed as products of the tumor cells (fig. 183). In Ewing's sarcoma, Johnson has occasionally observed transition from water-clear cells into cartilage, or a mixture of cartilage and osteoid, via an extracellular mucoid material.

TREATMENT. Amputation, resection, radiation therapy, Coley's toxins, or combinations of any or all of these methods have been used as treatment. All methods including radioactive phosphorus, however, have proved unsuccessful in terms of a five year survival. Poor results are undoubtedly due to a high rate of metastasis for the tumor either because of its multiple foci of origin or local permeation of the entire marrow cavity of a bone. The latter phenomenon makes it necessary to irradiate an entire bone in order to accomplish adequate coverage of a tumor-bearing area. Local sterilization by irradiation is rather common.

PROGNOSIS. Five year survival rate for this tumor has been reported as 0 to 12 percent. In the group of 435 cases of Ewing's sarcoma collected by Bethge, there was a five year survival rate of 8.5 percent.

METASTASES. Ewing's sarcoma has a striking tendency to involve other bones. Depending on the series reported, it is seen in as many as 43 to 75 percent of them. The skull is the most common site of first detectable bone metastases. Lymph nodes (20 percent; fig. 178) and lungs (45 to 65 percent) and other viscera are also sites of metastases.

DIFFERENTIAL DIAGNOSIS. Formerly, many cases were diagnosed as Ewing's sarcoma that Willis feels should not have been so classified, and we are in agreement. Neuroblastoma, reticulum cell sarcoma, and carcinoma metastatic to various sites in the body were the commonest of these. Differential diagnosis of neuroblastoma from Ewing's sarcoma may be aided by clinical demonstration of an adrenal mass, particularly with calcification, and histologic presence of rosettes in the neuroblastoma. Although differentiation from reticulum cell sarcoma is discussed in detail in that section of our fascicle, Schajowicz has described a staining difference between reticulum cell sarcoma and Ewing's sarcoma that may be helpful in distinguishing the two tumors. He has observed that there is demonstrable glycogen in tumor cells of Ewing's sarcoma but none in tumor cells of reticulum cell sarcoma.

Of metastatic carcinomas that may prove confusing, the so-called small cell or "oat cell" carcinoma of the lung is the most common; however, this occurs in age groups older than those of the majority of Ewing's sarcomas.

Reticulum Cell Sarcoma

SYNONYMS AND RELATED TERMS: Primary malignant lymphoma of bone; reticulosarcoma of bone.

DEFINITION. A rare malignant tumor, apparently arising from reticulum cells.

NATURAL HISTORY. The lesion was first defined by Parker and Jackson in 1939, although in 1928 Oberling described similar cases demonstrating that Ewing's sarcoma had its origin from reticulum cells.

INCIDENCE. Infrequent occurrence of the primary tumor is demonstrated by figures from the Mayo Clinic which show that, in a series of more than 1,200 malignant bone tumors, reticulum cell sarcoma of bone represented 4.2 percent (Dahlin).

CLINICAL DATA. Among the first symptoms and signs of primary reticulum cell sarcoma of bone are pain and swelling, with subsequent development of malfunction of the affected parts. As in most malignant bone lesions, the pain may be intermittent, may be worse at night, may become progressively worse, and is not relieved by rest. It is often referred to a nearby joint as evidence of inflammation of the synovium with joint effusion; while many cases have been described in which the synovium has been involved, actual extension by the neoplasm into the joint space is rare (Lichtenstein). The long interval of nine months to a year between the onset of symptoms and the patient's request for medical attention demonstrates the slow growth of the tumor. As the lesion progresses, there also may be some tenderness and local heat associated with the swelling. Fever is infrequent, in contrast to the frequency of this sign in Ewing's sarcoma. Pathologic fractures are fairly common accompaniments of the tumor (21 percent, Bethge). Three of the original 17 patients reported by Parker and Jackson had these complications. In support of these findings, one prominent clinical feature first observed by Parker and Jackson (p. 45) and then by subsequent writers is that, "In no other bone sarcoma is the contrast between the comparative well-being of the patient and the size of the lesion so marked."

Laboratory examinations are not rewarding: alkaline phosphatase, calcium, and phosphorus are usually within normal limits; on rare occasions, there have been associated secondary anemias and leukocytoses.

This is predominantly a tumor of young and middle-aged adults. A majority of the lesions are seen in patients between 20 and 40 years of age. However, ages noted in the literature have ranged from 8 to 71 years. The tumor is distinctly rare in patients under 10 years of age. It occurs in men twice as often as in women.

SITES OF TUMOR. Although this tumor has been reported as occurring in almost all bones of the body, it is most commonly seen in long tubular bones of the upper or lower extremities. Most often it occurs in lower extremities, approximately 45 percent in the femur or tibia (figs. 184–186); 17 to 18 percent of

the tumors are in bones of the upper extremities. According to Medill, 40 percent of the lesions are seen about the knee. An exception to occurrence of this tumor in long bones is the fact that we have been unable to find a report of a case involving the radius. The ulna is also a rare site for the lesion.

It is of interest to note that approximately 25 percent of primary reticulum cell sarcomas of bone involve multiple bones (McCormack et al., 2nd reference). Other sites of involvement reported are the skull, maxilla, mandible, clavicle, scapula, rib (fig. 187), sternum, vertebra, pelvis, and patella. There has been only one case reporting involvement of small bones of the ankle and foot, and none with involvement of small bones of the hand and wrist.

GROSS. No entirely distinctive features of the tumor set it apart from other bone lesions, e.g. Ewing's sarcoma, some metastatic carcinomas, or eosinophilic granuloma. However in cases which have been studied as intact specimens, primary reticulum cell sarcoma of bone is a soft, pink-white, or reddish gray tumor which commonly involves a major portion of the marrow cavity of a long bone. Areas of necrosis and hemorrhage are frequent, and any portion of a long bone may be involved. At the major focus of the tumor there is destruction of bone, with frequent extension of the sarcoma into surrounding soft tissues.

The soft tissue component of the tumor has an appearance that resembles a lymphoma, and is homogeneous, soft, tan-gray, or gray-red. Its boundaries are usually ill defined, and the tissues are diffusely involved. Calcification in the soft tissue component of the lesion is rare. The predominant feature of primary reticulum cell sarcoma of bone is that of destruction. However, reactive bone may form subperiosteally and within the tumor; radiographically this latter bone formation will impart a sclerotic configuration.

In the flat bones observed by roentgen examination, destruction by tumor is more diffuse than in long bones. There also is slight expansion of the bone which is usually ovoid or fusiform in configuration and similar to that in involvement of long bones.

Although bone and cartilage production is not a part of the tumor, specimens removed from patients following radiation therapy have shown evidence of bony replacement of the tumor. In a recent case, a destructive bone lesion was irradiated without benefit of biopsy. Proof that the tumor was reticulum cell sarcoma was obtained from a regional lymph node that was involved by reticulum cell sarcoma. Later, generous biopsies showed no evidence of tumor but did show reparative changes from bone. In contrast to Ewing's sarcoma of bone, periosteal bone reaction is less common. It has been seen radiographically in about half of the cases (Wilson and Pugh; Sherman and Snyder).

MICROSCOPIC. Histologically, reticulum cell sarcoma primary in bone resembles the more commonly seen reticulum cell sarcoma that predominantly involves lymph node and other components of the reticuloendothelial system.

The cells comprising the tumor also have the characteristics of reticulum cells (figs. 189, 190). Cell boundaries are indistinct in most instances. Cytoplasm is identifiable, but is faintly acidophilic or basophilic. In a hematoxylin and eosin preparation of a lesion, cytoplasmic processes may be seen adjoining the neighboring cells. The nucleus has varied shapes, but is usually lobular with fairly distinct indentation (fig. 192). Irregular masses of chromatin may be scattered throughout the nuclei. Commonly, nucleoli are seen and, in lesions considered more malignant, they may be quite large and acidophilic (fig. 191). Comparing similar microscopic fields, the cells may be of fairly uniform size and stainability, apparently reflecting differentiation of the lesion; however, variations from this pattern are seen. Great variation in size and stainability of nuclei also is observed; in what have been described as less well differentiated lesions, occasionally multinucleated cells suggestive of Sternberg-Reed cells are noted. Patterns formed by these cells may be varied. Variations are due to the amount of fibrous stroma associated with the lesion, necrosis, and areas of hemorrhage. In many lesions, a rather abundant fibrous stroma tends to partition the tumor cells into small nests, thus imparting a somewhat alveolar arrangement of the cells. Moreover, residual bony trabeculae will be present, for there seems to be no evidence that bone forms from the tumor cells.

TREATMENT. Types of treatment have varied over the years and have included amputation, wide local excision, radiation therapy, injection of Coley's toxins, and many other combinations of different methods. These many modes of therapy do not allow satisfactory interpretation of results. At present, it would seem that treatment by adequate radiation therapy gives the best results (Bethge). However, Francis and associates have reported that their favored method of treatment, radiation therapy followed by a course of Coley's toxins, has resulted in five year survival of 48 percent, and ten year survival of 33 percent of their patients. Wilson and Pugh had a 42 percent five year survival of 33 patients. One half of these had been treated surgically and one-half by radiotherapy, with no difference in results noted. In summarizing the results of all methods of treatment, Bethge gives the following five and ten year survival rates: five year survival rate for these varied methods of treatment is 32.9 percent; ten year survival rate is 16.9 percent. In each group, there was a similar number of cases: 85 in the five year survivors, 83 in the ten year survivors.

METASTASES. In an original report of 17 cases of primary reticulum cell sarcoma of bone, Parker and Jackson described a growth of tumor cells within small veins as a common feature of the histology of this lesion. This perhaps accounts for the widespread metastases and multiple bone involvement commonly seen.

Metastases involving other organs occur in approximately 47 percent of cases (Bethge): lymph node metastases are usually regional and occur in 22 percent of the cases, bone metastases occur in 15 percent, and lung metastases

occur in approximately 10 percent. Evidence of metastases has also been seen in other sites such as subcutaneous tissues, liver, and adrenal glands.

DIFFERENTIAL DIAGNOSIS. An alveolar arrangement of cells is commonly seen in Ewing's sarcoma and probably leads to difficulty in differentiating it from reticulum cell sarcoma. In contradistinction to Ewing's sarcoma, most of the primary reticulum cell sarcomas of bone occur in older age groups, the third and fourth decades.

Confusion with osteosarcoma is readily apparent when the less well differentiated reticulum cell sarcomas are encountered. Bizarre nuclei and bone formation in the stroma account for this misinterpretation.

In reviewing a group of bone tumors from the Registry of Bone Sarcoma of the American College of Surgeons, cases of primary reticulum cell sarcomas were extracted from among cases designated as Ewing's sarcoma, Hodgkin's disease, lymphosarcoma, osteosarcoma, leukosarcoma, and inflammatory lesions of bone (Parker and Jackson). It is with this group of lesions that the primary reticulum cell sarcoma of bone is still confused.

It has been noted that foci of lymphocytes often occur in reticulum cell sarcomas. Thus, if biopsies are obtained in which there are mixtures of reticulum cells and lymphocytes, it is possible that misinterpretation as an inflammatory lesion could be made on the basis of finding abundant lymphocytes. Since reticulin stains reveal abundant reticulin in the stroma and fewer fibers among the tumor cells (fig. 188), it can be stated that the histology of primary reticulum cell sarcoma of bone is indistinguishable from primary reticulum cell sarcoma of other organs of the body.

TUMORS ARISING FROM FAT CELLS

Lipoma

DEFINITION. A tumor of fatty tissue arising within the marrow cavity.

INCIDENCE. Lipomas of bone are rare tumors; however, they have been seen in the skull, mandible, ulna, rib, fibula, tibia, and os calcis. We have observed a lipoma in the distal phalanx of the thumb of a 70-year-old Negro woman (fig. 195). We have also seen a lipoma of the rib in a 53-year-old woman which was diagnosed radiographically as probable fibrous dysplasia (fig. 196). Lipomas of bone also have been reported which were diagnosed radiographically as "solitary bone cyst," "bone cyst or giant cell tumor," and "osteoclastoma" (figs. 193, 194). One of these was considered neoplastic or possibly malignant. Because cortical bone is sometimes destroyed, radiologists occasionally may designate this lesion as a malignant neoplasm. Lipomas apparently arising in the periosteum have also been described; in these cases, the capsule of the lipoma and the periosteum generally could not be separated, but in one case the periosteum was intact (Fairbank). Relatively little bony change has been noted radiographically, except bowing of the tibia in one case and periosteal proliferation in another.

GROSS. Mature lesions appear as yellow, lobulated masses of fat.

MICROSCOPIC. This generally confirms the gross appearance. However, a few spicules of bone may be isolated in the fat (fig. 194).

TREATMENT. Conservative treatment is indicated.

ASSOCIATED LESIONS. Lipomas of the tendon sheath have been reported. Sullivan and associates reviewed literature on this subject; including their two cases, 45 cases have been described.

Liposarcoma

SYNONYMS AND RELATED TERMS: Lipoblastic sarcoma; lipofibrosarcoma; lipomyxosarcoma.

DEFINITION. A malignant tumor arising from fat within the bone marrow cavity.

PATHOGENESIS. This malignant tumor arises from fat within the bone marrow cavity (figs. 197, 198). Dawson's review of cases previously reported, however, stated that some of the cases were difficult to accept as liposarcomas because of unconvincing pathologic or clinical data. One case of possible liposarcoma seen by us, occurring in the upper third of a femur, proved to be metastatic from a renal cell carcinoma. Liposarcoma with multiple foci of origin in fatty tissues of the body and in bone also has been observed.

GROSS. This neoplasm is soft and yellow; in Dawson's case, it formed whitish, encephaloid masses adherent externally to the bone.

MICROSCOPIC. The pattern of this tumor is similar to that of liposarcoma in soft tissues (see Fascicle 5, "Tumors of the Soft Tissues"). Lobulation, prominent capillary vascularity, numerous "signet-ring" cells, and occasionally a fibrosarcomatous appearance (figs. 199–202) were apparent in the case of Dawson.

References

Ackerman, L. V. Multiple primary liposarcomas. Am. J. Path., 20:789–797, 1944.

Bartlett, E. I. Periosteal lipoma. Report of two cases. Arch. Surg., 21:1015–1022, 1930.

Bayrd, E. D. The bone marrow on sternal aspiration in multiple myeloma. Blood, 3:987–1018, 1948.

Bethge, J. F. J. Die Ewingtumoren oder Omoblastome des Knochens. Differentialdiagnostiche und kritische Erörterungen. Erg. Chir. Orthop., 39:327–425, 1955.

Carson, C. P., Ackerman, L. V., and Maltby, J. D. Plasma cell myeloma. A clinical, pathologic and roentgenologic review of 90 cases. Am. J. Clin. Path., 25:849–888, 1955.

Child, P. L. Lipoma of the os calcis. Report of a case. Am. J. Clin. Path., 25:1050–1052, 1955.

Christopherson, W. M., and Miller, A. J. A re-evaluation of solitary plasma-cell myeloma of bone. Cancer, 3:240–252, 1950.

Cowdell, R. H. Intra-osseous lipoma of rib. Brit. J. Surg., 41 : 664–665, 1954.

Dahlin, D. C. Bone Tumors. Lipoma and Liposarcoma, pp. 90–93; Reticulum Cell Sarcoma (Primary Malignant Lymphoma of Bone), pp. 104–113; Ewing's Tumor, pp. 156–163. Springfield, Ill.: Charles C Thomas, 1957.

Dawson, E. K. Liposarcoma of bone. J. Path. & Bact., 70:513–520, 1955.

Diamond, H. D., Craver, L. F., and Woodard, H. Q. Radioactive phosphorus. III. In the treatment of malignant lymphomas, plasma-cell myeloma, Ewing's sarcoma, and osteogenic sarcoma. Cancer, 10:143–150, 1957.

Dickson, A. B., Ayres, W. W., Mason, M. W., and Miller, W. R. Lipoma of bone of intra-osseous origin. J. Bone & Joint Surg., 33–A:257–259, 1951.

Erf, L. A., and Herbut, P. A. Comparative cytology of Wright's stained smears and histologic sections in multiple myeloma. Am. J. Clin. Path., 16:1–12, 1946.

Ewing, J. Diffuse endothelioma of bone. Proc. New York Path. Soc., 21:17–24, 1921.

_____. Further report on endothelial myeloma of bone. Proc. New York Path. Soc., 24:93–101, 1924.

Fairbank, H. A. T. A parosteal lipoma. J. Bone & Joint Surg., 35–B:589, 1953.

Francis, K. C., Higinbotham, N. L., and Coley, B. L. Primary reticulum cell sarcoma of bone. Report of 44 cases. Surg., Gynec. & Obst., 99:142–146, 1954.

Fruhling, L., and Chadli, A. Les tumerus malignes primitives de la moelle osseuse à evolution hématopoiétique: les sarcomes médullaires. II. Les sarcomes plasmocytaires du squelette. Ann. d'anat. path., 2:325–401, 1957.

Hellwig, C. A. Extramedullary plasma cell tumors as observed in various locations. Arch. Path., 36:95–111, 1943.

Herbut, P. A., and Erf, L. A. Lipoblastic and megakaryocytoid multiple myeloma. Am. J. Clin. Path., 16:13–21, 1946.

Hummel, J. A., and Danh, T. T. Un cas de lipome périostique. J. radiol. électr., 35:737–738, 1954.

Jaeger, E. Das extramedulläre Plasmocytom. Ztschr. f. Krebsforsch., 52:349–383, 1941.

Johnson, L. C. A general theory of bone tumors. Bull. New York Acad. Med., 29:164–171, 1953.

_____, and Meador, G. E. The nature of benign "solitary myeloma" of bone. Bull. Hosp. Joint Dis., 12:298–313, 1951.

Lichtenstein, L. Bone Tumors. Primary Reticulum-Cell Sarcoma of Bone, pp. 296–302. St. Louis: C. V. Mosby Co., 1959.

_____, and Jaffe, H. L. Ewing's sarcoma of bone. Am. J. Path., 23:43–77, 1947.

_____, and Jaffe, H. L. Multiple myeloma. A survey based on thirty-five cases, eighteen of which came to autopsy. Arch. Path., 44:207–246, 1947.

Lisco, H. Russell bodies occurring in the lymph follicles of the intestinal tract of pigs. Anat. Rec., 82:59–66, 1942.

Magnus, H. A., and Wood, H. L. C. Primary reticulo-sarcoma of bone. J. Bone & Joint Surg., 38–B: 258–278, 1956.

McCormack, L. J., Dockerty, M. B., and Ghormley, R. K. Ewing's sarcoma. Cancer, 5:85–99, 1952.

_____, Ivins, J. C., Dahlin, D. C., and Johnson, E. W., Jr. Primary reticulum-cell sarcoma of bone. Cancer, 5:1182–1192, 1952.

Medill, E. V. Primary reticulum-cell sarcoma of bone. J. Fac. Radiologists, Lond., 8:102–117, 1956.

Moss, W. T., and Ackerman, L. V. Plasma cell leukemia. Blood, 1:396–406, 1946.

Newman, C. W. Fibrolipoma of the mandible: report of case. J. Oral Surg., 15:251–252, 1957.

Newman, W., Diefenbach, W. C. L., Quinn, M., and Meyer, L. M. A case of acute plasma-cell leukemia supporting the concept of unity of plasmacellular neoplasia. Cancer, 5:514–520, 1952.

Oberling, C. Les réticulosarcomes et les réticulo-endothéliosarcomes de la moelle osseuse (sarcomes d'Ewing). Bull. Assoc. franç. p. l'étude du cancer, 17:259–296, 1928.

Parker, F., Jr., and Jackson, H., Jr. Primary reticulum cell sarcoma of bone. Surg., Gynec. & Obst., 68:45–53, 1939.

Pearse, A. G. E. The nature of Russell bodies and Kurloff bodies. Observations on the cytochemistry of plasma cells and reticulum cells. J. Clin. Path., 2:81–90, 1949.

Schajowicz, F. Ewing's sarcoma and reticulum-cell sarcoma of bone. With special reference to the histochemical demonstration of glycogen as an aid to differential diagnosis. J. Bone & Joint Surg., 41–A:349–356, 1959.

Schinz, H. R., Baensch, W. E., Friedl, E., and Uehlinger, E. Lehrbuch der Röentgendiagnostik. Vol. 2. Stuttgart: George Thieme Verlag, 1950.

PLASMA CELL MYELOMA

Figure 161. Hemisection of vertebrae showing extensive replacement of cancellous bone by tumor. The larger masses of tumor, diagnosed by prior biopsy as plasma cell myeloma, were centrally necrotic. The intervertebral disk was partly eroded, as seen in the right lower portion of the photograph. In many areas the cortex was thin and perforated. Roentgenograms had shown destruction also of the 6th and 10th ribs.

The patient's complaints had been those of stiffness and pain in the upper cervical region. Nineteen months later this 64-year-old Negro man died because of widely disseminated myeloma and epidermoid carcinoma of the esophagus. (From the Armed Forces Institute of Pathology.) A. F. I. P. Acc. No. 288723 (20091).

Figure 162. This roentgenogram of the skull of a woman with disseminated plasma cell myeloma demonstrates the multiple, "punched-out," radiolucent areas so characteristic of this tumor. W.U. 57–4389; A. F. I. P. Acc. No. 218757–225.



Fig. 161

Fig. 162

PLASMA CELL MYELOMA

(Figures 165 and 166 are from the same case)

Figure 163. Roentgenogram of a plasma cell myeloma of the right clavicle showing callus formation about a pathologic fracture. The 53-year-old patient had had a plasma cell myeloma removed from the right inferior turbinate eight months previously, but no clinical or laboratory evidence of disseminated disease had been apparent at that time. W.U. 57–3007; A. F. I. P. Acc. No. 218757–226.

Figure 164. In this roentgenogram, a destructive lesion of the head of the right femur is illustrated in which cortex and medullary bone have been destroyed. This patient was a 64-year-old man who had sustained a pathologic fracture of the right femur. Biopsy taken from the area of fracture confirmed diagnosis of plasma cell myeloma. W.U. 54–5408; A. F. I. P. Acc. No. 218757–227.

Figure 165. Roentgenogram illustrating a destructive lesion in the proximal portion of the tibia of a 52-year-old man. This represents a solitary bone manifestation of plasma cell myeloma first diagnosed by biopsy of a mass of the epiglottis. The lesion in the bone was then biopsied, irradiated, and curetted and packed with bone chips. The curetted material was thoroughly studied, but there was no evidence of myeloma. These findings indicate that radiation can sterilize myeloma in focal zones. The patient was living at least eight years later without further evidence of bone involvement. W.U. 50–417; A. F. I. P. Acc. No. 218757–228.

Fig. 163

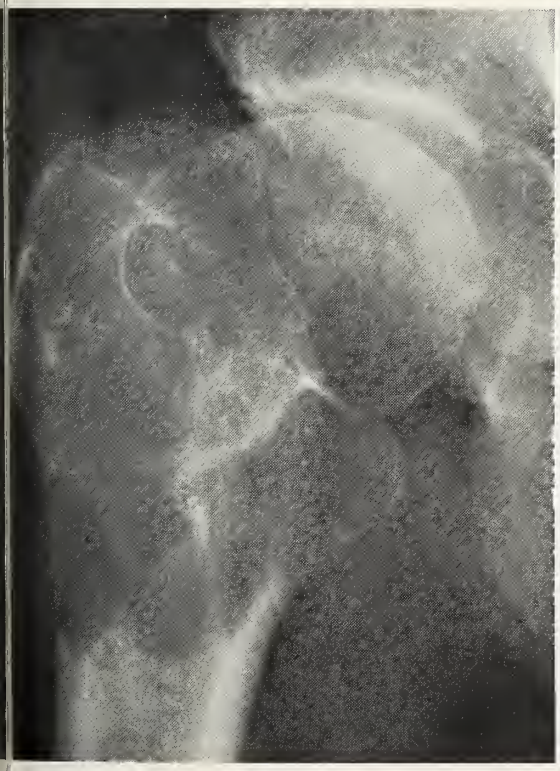

Fig. 164

Fig. 165

PLASMA CELL MYELOMA

(Figures 165 and 166 are from the same case. Figures 167 and 168 are from the same case*)

Figure 166. Photomicrograph of this tumor from the larynx shows numerous plasma cells. Some were bizarre but others were more easily identifiable as plasma cells. Plasma cell myelomas in this stage of differentiation may be difficult to distinguish histologically from undifferentiated carcinomas. Hematoxylin and eosin stain. X 600. W.U. 50–3224; A. F. I. P. Acc. No. 218757–233.

Figure 167. Photomicrograph illustrating an initial lesion of plasma cell myeloma in a 60-year-old woman. This section of a biopsy was misinterpreted by us in 1954 as plasma cell granuloma because of abundant fibrous stroma, excellent differentiation of plasma cells, and gross appearance of the lesion as a cyst with a small reddish gray mass at its periphery. Roentgenographically also, the lesion had been interpreted as a cyst in the midshaft of the humerus.

One year later there was evidence of dissemination to the clavicle, skull, mandible, and several ribs. The patient was treated with urethane and was reportedly in excellent health in 1958. Hematoxylin and eosin stain. X 200. B.H. 54–6354; A. F. I. P. Acc. No. 218757–229.

Figure 168. Higher power photomicrograph of the lesion. Hematoxylin and eosin stain. X 660. B.H. 54–6354; A. F. I. P. Acc. No. 218757–230.

---

*Courtesy of Dr. J. M. Dell, Gainesville, Fla.

Fig. 166

Fig. 167

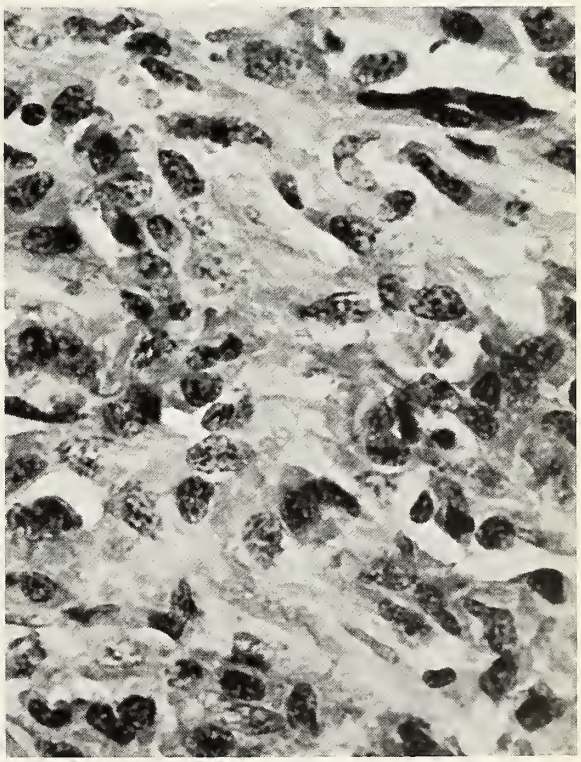

Fig. 168

PLASMA CELL MYELOMA

(Figures 169 and 170 are from the same case)

Figure 169. Histologic section showing a mass of plasma cells. This biopsy was from the 7th and 8th ribs of a 50-year-old man. Most of the cells in this photomicrograph are recognizable as nearly normal plasma cells, several being larger than normal. Others have irregular atypical or even centrally situated nuclei. The patient had evidence of dissemination of the myeloma. Hematoxylin and eosin stain. X 1170. B.H. 52-4422; A. F. I. P. Acc. No. 218757-231.

Figure 170. Abnormal plasma cells are noted in this photomicrograph, as are a few binucleate plasma cells. Hematoxylin and eosin stain. X 660. B.H. 52-4422; A. F. I. P. Acc. No. 218757-232.

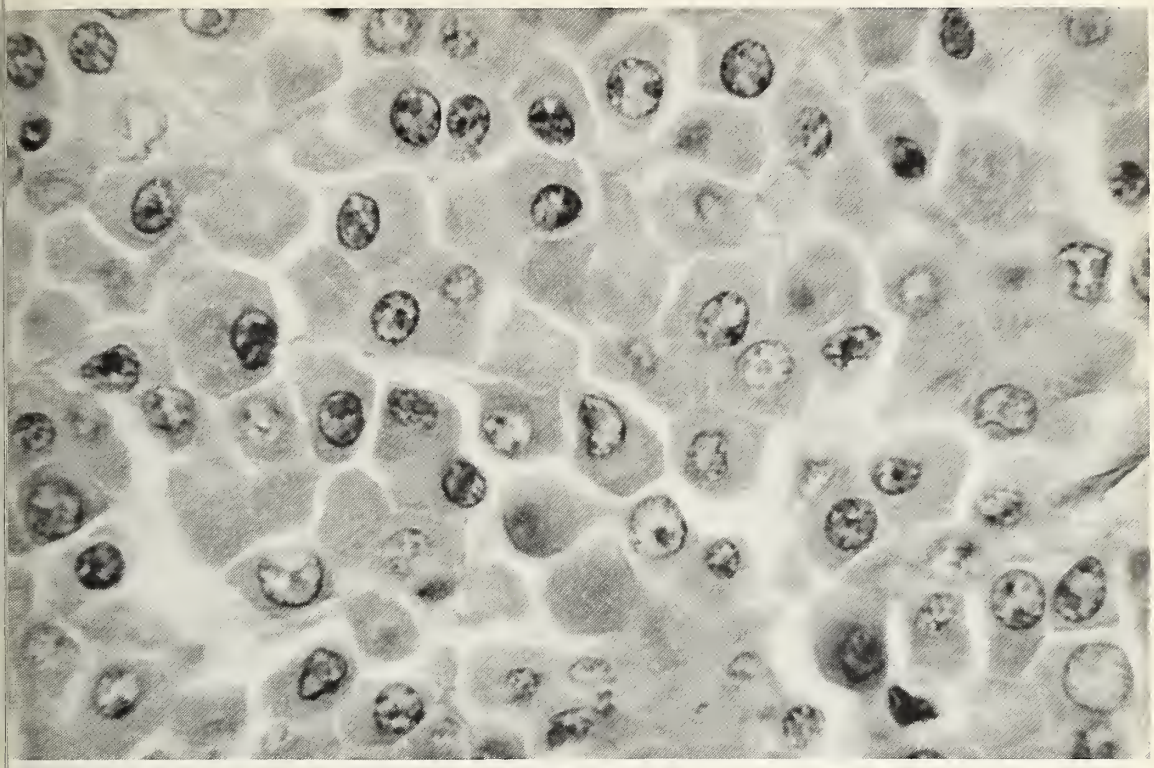

Fig. 169

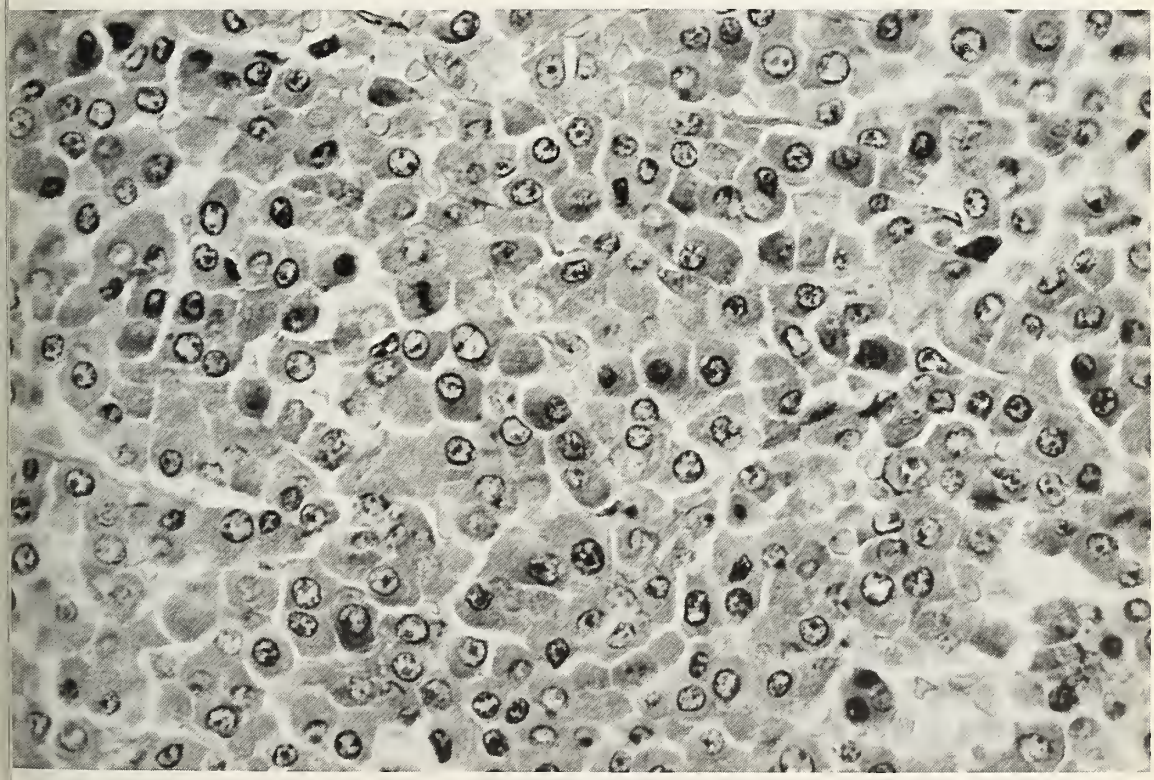

Fig. 170

EWING'S SARCOMA

(Figures 171 and 172 are from the same case)

Figure 171. Typical cells of Ewing's sarcoma are illustrated in this microsection. Nuclei are fairly uniform in size and staining. Cytoplasm and cytoplasmic boundaries are indistinct. Small blood vessels form part of the background stroma. Hematoxylin and eosin stain. X 550. W.U. 58–3699; A. F. I. P. Acc. No. 218757–234.

Figure 172. An imprint of the biopsy from which the microsection was made. Characteristics of Ewing's sarcoma cells are well demonstrated: cytoplasm is scanty to practically nonexistent, few cells have discernible boundaries, and nucleoli are present. Hematoxylin and eosin stain. X 1100. W.U. 58–2333; A. F. I. P. Acc. No. 218757–235.

Figure 173. Characteristic roentgenogram of Ewing's sarcoma of the proximal portion of a femur. Widening of the medullary cavity, irregular thickening of the cortex, and periosteal bone proliferation can be noted.

This 18-year-old girl had had intermittent episodes of pain in the upper thigh. When earlier roentgenographic examinations had been suggestive of an infectious process, she had been given a 10-day trial of penicillin therapy, after which symptoms were completely relieved. With recurrence of symptoms, roentgenographic examinations were repeated and interpreted as a suspected neoplastic lesion. Therefore, a biopsy was done; following diagnosis of Ewing's sarcoma, the tumor was irradiated. Recurrent lesions were treated with Coley's toxins and the betatron, but the patient died with multiple metastases to the viscera and bones six years after the first radiation therapy. W.U. 57–4387; A. F. I. P. Acc. No. 218757–236.

Figure 174. This radiograph illustrates an atypical form of Ewing's sarcoma involving the left humerus, atypical in that the epiphysial area seems involved. The bone is largely destroyed but expanded and has a honeycombed pattern which was interpreted as a possible hemangioma. At operation a large, hemorrhagic, cystic cavity was encountered. Curettings of the wall of the cavity revealed tumor compatible with the diagnosis of Ewing's sarcoma. The patient was a 2-year-old boy. W.U. 58–204; A. F. I. P. Acc. No. 218757–237.

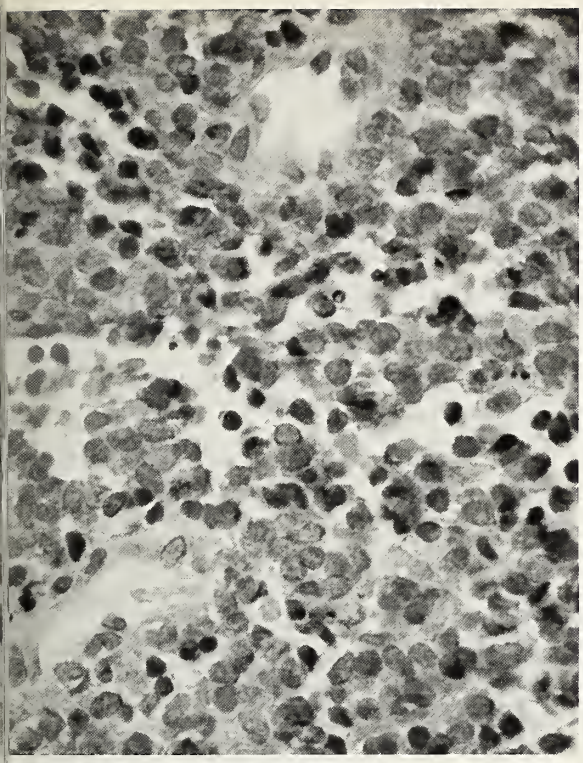

Fig. 171

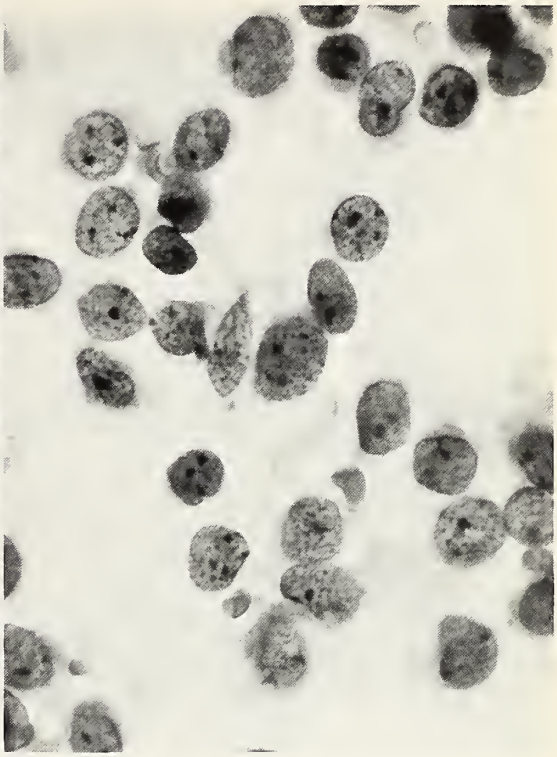

Fig. 172

Fig. 173

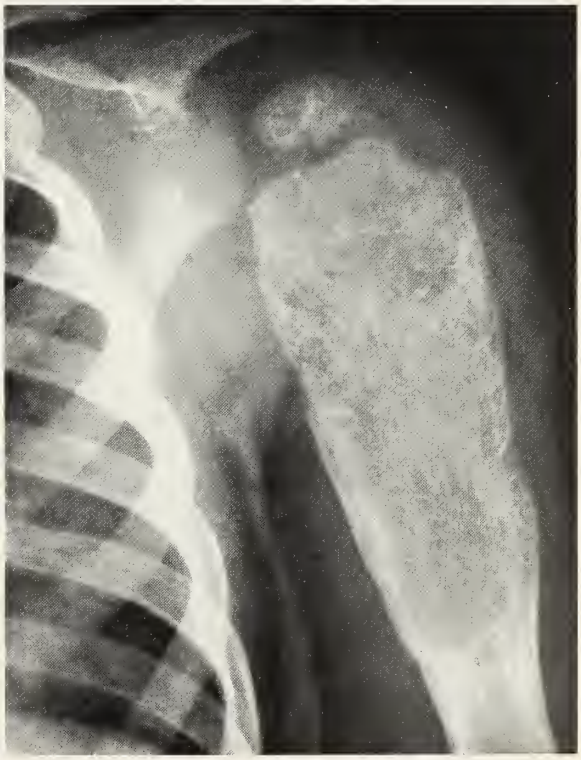

Fig. 174

EWING'S SARCOMA

(Figures 175 and 176 are from the same case*)

Figure 175. Radiograph of the left fibula from a 12-year-old girl. The soft tissue component of Ewing's sarcoma and destruction of bone and periosteal bone formation are well seen. Spiculation is noted in the periosteal area of the bone of this specimen. A. F. I. P. Acc. No. 704565–1.

Figure 176. The photomicrograph illustrates the nestlike pattern of Ewing's sarcoma in which nests are distinctly outlined by an intervening fibrovascular stroma. Association of the tumor with subperiosteal bone formation and the relation of the tumor to periosteum and adjacent soft tissues are also demonstrated. Hematoxylin and eosin stain. X 98. A. F. I. P. Acc. No. 704565–2.

*From the Armed Forces Institute of Pathology.

Fig. 175

Fig. 176

EWING'S SARCOMA

Figure 177. Subperiosteal bone formation without evidence of Ewing's sarcoma is seen in this photomicrograph, in contrast to the periosteal bone reaction associated with invasion by Ewing's sarcoma seen in figure 173. The tumor was removed from the left femoral shaft of a 4-year-old boy. Hematoxylin and eosin stain. X 105. B.H. 57–2856; A. F. I. P. Acc. No. 218757–238.

Figure 178. Photomicrograph illustrating Ewing's sarcoma metastatic to a paravertebral lymph node in a 22-year-old man. The primary lesion of this patient was in the midshaft of the fibula. Hematoxylin and eosin stain. X 165. (From the Armed Forces Institute of Pathology.) A. F. I. P. Acc. No. 617968.

Figure 179. Photomicrograph showing a collection of tumor cells around a blood vessel in a Ewing's sarcoma. At the periphery, degeneration of the tumor is seen. Hematoxylin and eosin stain. X 220. A. F. I. P. Acc. No. 218757–43.

Figure 180. This photomicrograph lacks reticulin in the Ewing's sarcoma cells grouped about a blood vessel. Wilder's reticulin stain. X 615. A. F. I. P. Acc. No. 218757–44.

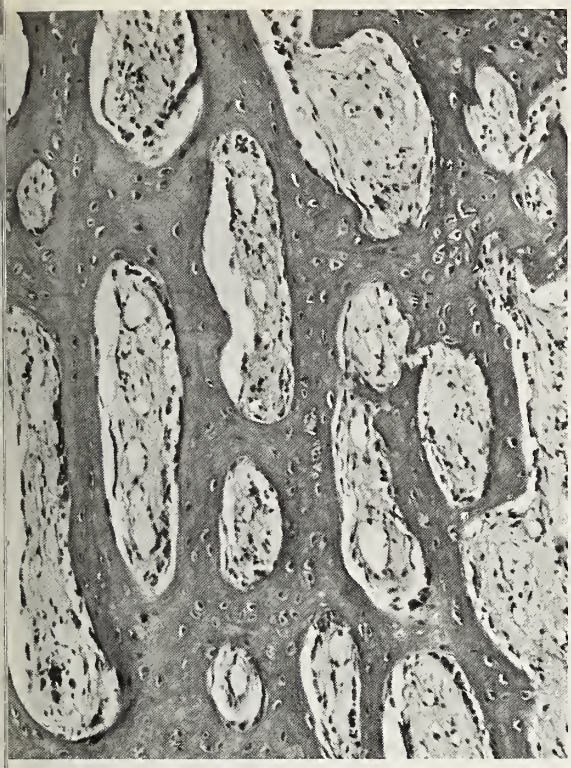

Fig. 177

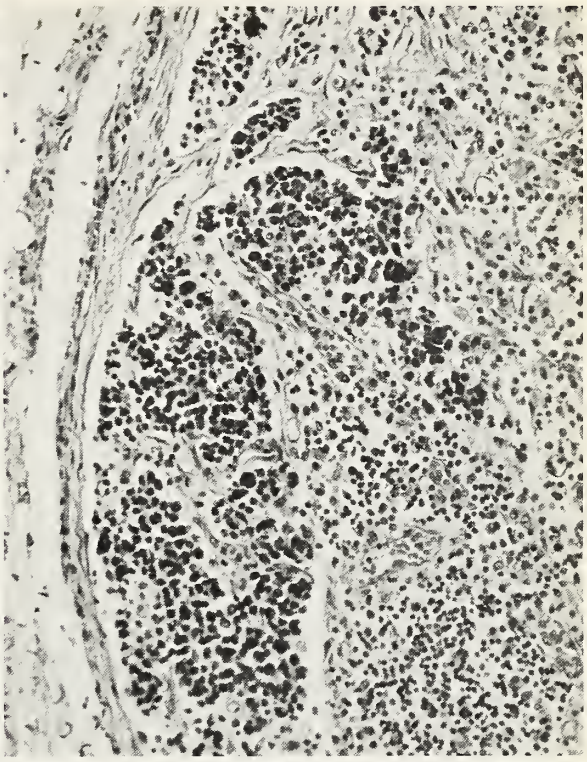

Fig. 178

Fig. 179

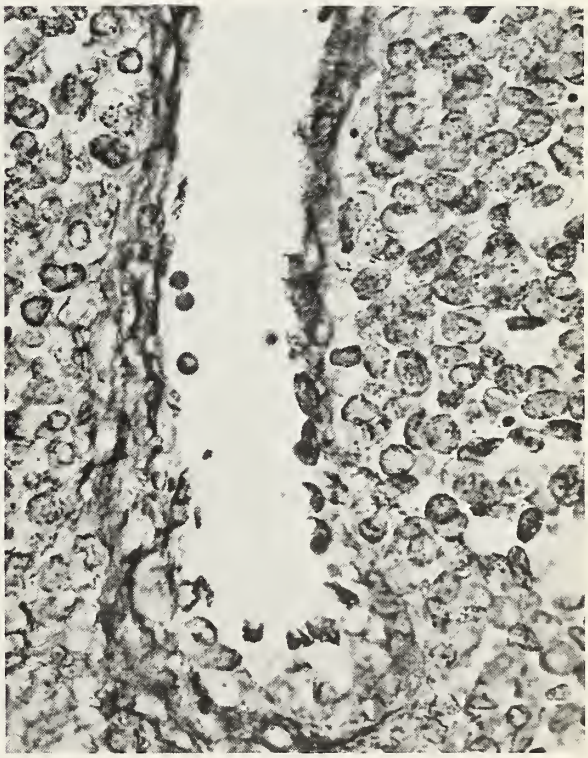

Fig. 180

Sherman, R. S., and Snyder, R. E., The roentgen appearance of primary reticulum cell sarcoma of bone. Am. J. Roentgenol., 58:291–306, 1947.

_____, and Soong, K. Y. Ewing's sarcoma: its roentgen classification and diagnosis. Radiology, 66:529–539, 1956.

Slavens, J. J. Multiple myeloma in a child. Am. J. Dis. Child., 47:821–835, 1934.

Smith, W. E., and Fienberg, R. Intraosseous lipoma of bone. Cancer, 10:1151–1152, 1957.

Snapper, I. Stilbamidine and pentamidine in multiple myeloma. J.A.M.A., 133:157–161, 1947.

_____. Rare Manifestations of Metabolic Bone Disease. Their Practical Importance. Springfield, Ill.: Charles C Thomas, 1952.

_____, Turner, L. B., and Moscovitz, H. L. Multiple Myeloma. New York: Grune & Stratton, 1953.

Stout, A. P. A discussion of the pathology and histogenesis of Ewing's tumor of bone marrow. Am. J. Roentgenol., 50:334–342, 1943.

_____, and Kenney, F. R. Primary plasma-cell tumors of the upper air passages and oral cavity. Cancer, 2:261–278, 1949.

Strange, V. M., and de Lorimier, A. A. Reticulum cell sarcoma primary in the skull. Report of three cases. Am. J. Roentgenol., 71:40–50, 1954.

Sullivan, C. R., Dahlin, D. C., and Bryan, R. S. Lipoma of tendon sheath. J. Bone & Joint Surg., 38–A:1275–1280, 1956.

Swenson, P. C. The roentgenologic aspects of Ewing's tumor of bone marrow. Am. J. Roentgenol., 50:343–354, 1943.

Uehlinger, E. Personal communication, 1959.

Valls, J., Muscolo, D., and Schajowicz, F. Reticulum-cell sarcoma of bone. J. Bone & Joint Surg., 34–B:588–598, 1952.

Wehrsig, D. Lipom des Knochenmarks. Zentralbl. f. allg. Path. u. path. Anat., 21:243–247, 1910.

Willis, R. A. Pathology of Tumours. Reticulum Cell Sarcoma of Bone; "Ewing's Tumour," pp. 686–687. London: Butterworth & Co., Ltd.; St. Louis: C. V. Mosby Co., 1948.

Wilson, T. W., and Pugh, D. G. Primary reticulum-cell sarcoma of bone, with emphasis on roentgen aspects. Radiology, 65:343–351, 1955.

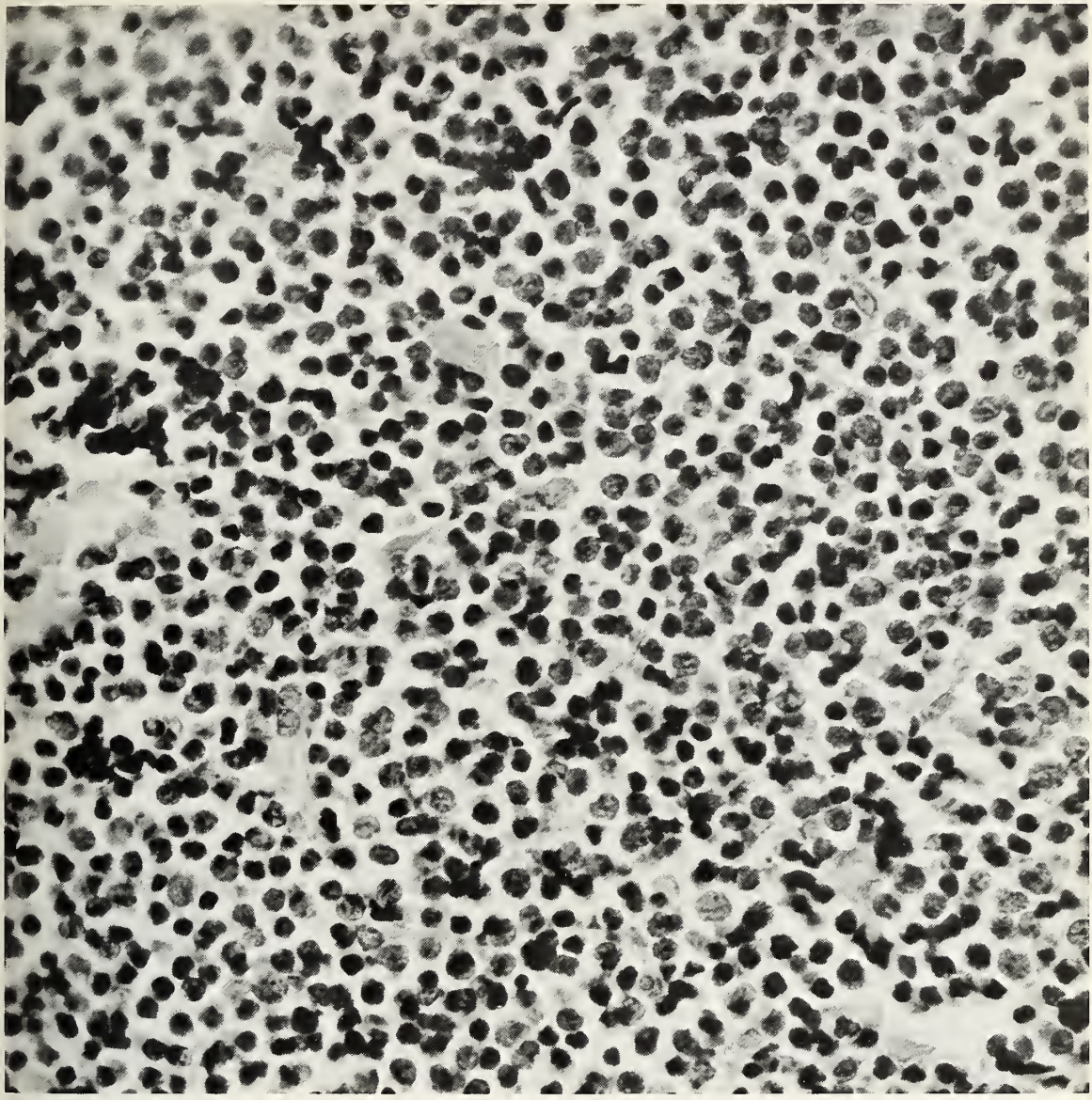

Fig. 181

EWING'S SARCOMA

Figure 181. Photomicrograph showing uniformity of cell types in a Ewing's sarcoma. The cells are small, having scanty indistinct cytoplasm. Many of the nuclei in this field are hyperchromatic, and some are pyknotic. In the background are cells with lighter staining nuclei. Few nucleoli are discernible in the lighter staining cells. Hematoxylin and eosin stain. X 615. A. F. I. P. Acc. No. 218757–46.

EWING'S SARCOMA

Figure 182. Cellular details characteristic of a Ewing's sarcoma are seen in the photomicrograph. Nuclei are of fairly uniform size, but a few are pyknotic. Occasional mitotic figures and nucleoli can be noted, and cytoplasm is indistinct. The tumor was in the humerus of a 5-year-old boy. Hematoxylin and eosin stain. X 770. B.H. 57–3546; A. F. I. P. Acc. No. 218757–239.

Figure 183. This photomicrograph shows a section of a Ewing's sarcoma of the ilium. It illustrates a rare finding, gradual transition from tumor cells to what appears to be cartilage. Hematoxylin and eosin stain. X 440. (From the Armed Forces Institute of Pathology.) A. F. I. P. Acc. No. 716743.

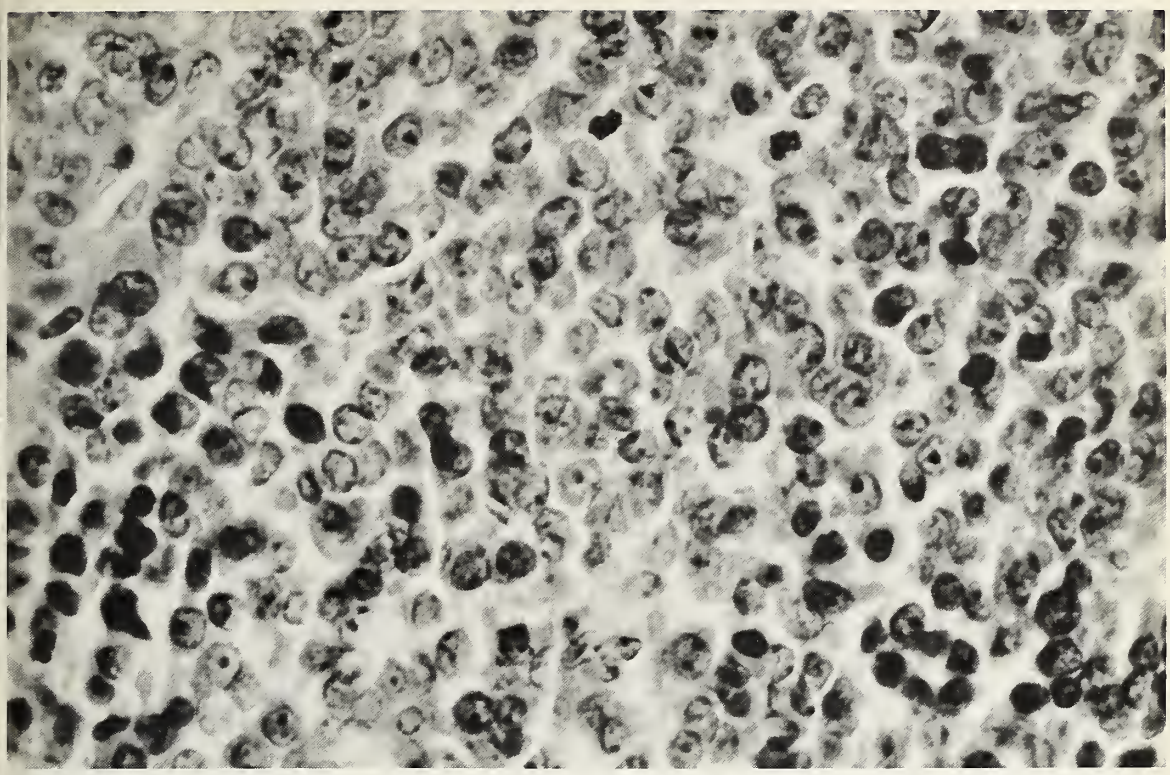

Fig. 182

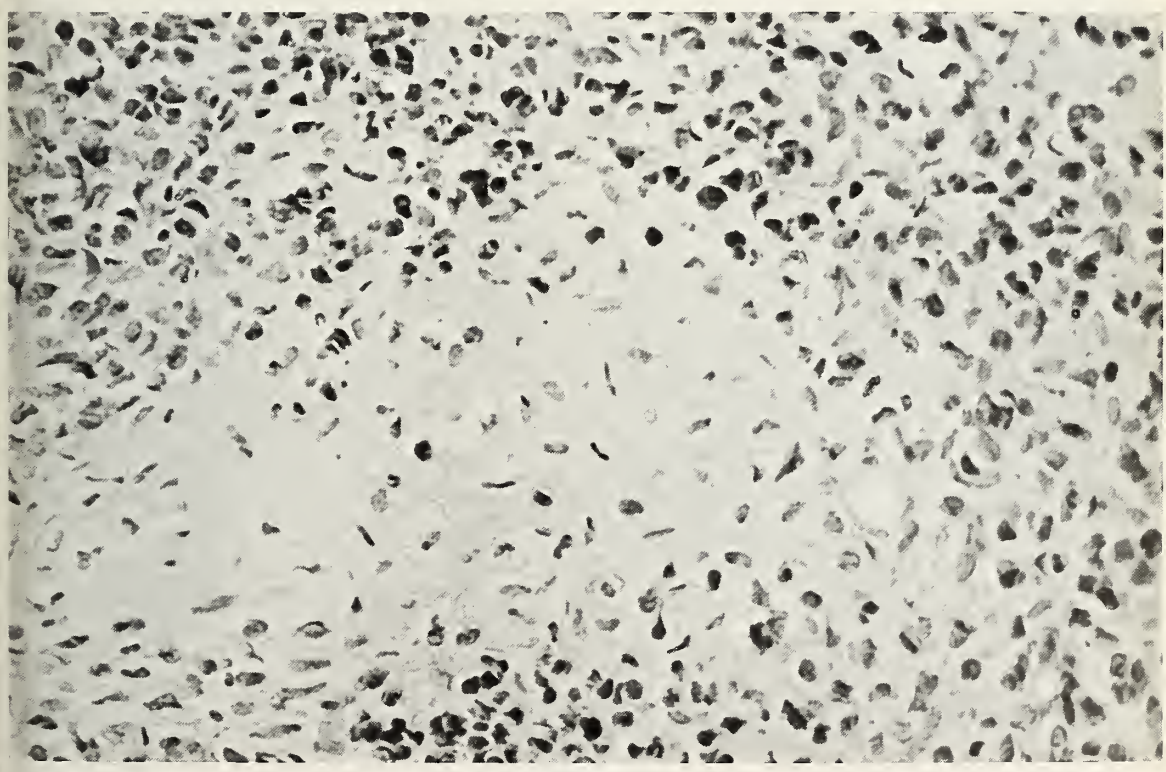

Fig. 183

RETICULUM CELL SARCOMA

(Figures 185 and 186 are from the same case)

Figure 184. Roentgenogram shows a pathologic fracture through the shaft of a femur of a 60-year-old man. Irregular destruction of the medullary cavity and cortex is present. Callus formation surrounds the incompletely healed fracture. (Courtesy of Dr. J. M. Burnett, St. Louis, Mo.) W.U. 58–1088; A. F. I. P. Acc. No. 218757–240.

Figure 185. Roentgenogram of a reticulum cell sarcoma of the right tibia of a 70-year-old man. He had had pain for two weeks prior to hospital admission. The pathologic fracture is evident in this film. W.U. 57–6921; A. F. I. P. Acc. No. 218757–241.

Figure 186. Roentgenogram shows this tibia five years after radiation therapy. The patient now has a useful limb. W.U. 57–6922; A. F. I. P. Acc. No. 218757–242.

Fig. 184

Fig. 185

Fig. 186

RETICULUM CELL SARCOMA

Figure 187. Longitudinal section through a reticulum cell sarcoma involving the rib. Extensive destruction of marrow and cortical bone can be noted in the photograph, the major portion of the tumor being extraosseous. A. F. I. P. Acc. No. 218757–243.

Figure 188. Dense reticulin fibers dividing cell groups and the more delicate fibers coursing between the cells are seen in this photomicrograph of a primary reticulum cell sarcoma. Wilder's reticulin stain. X 200. A. F. I. P. Acc. No. 218757–244.

Fig. 187

Fig. 188

RETICULUM CELL SARCOMA

(Figures 189 and 190 are from the same case)

Figure 189. The uniform pattern of a primary reticulum cell sarcoma is shown in this photomicrograph. The cells have indistinct cytoplasm and appear to have protoplasmic extensions from one to another. The patient died one year after radiation therapy with multiple metastases to the skull. Hematoxylin and eosin stain. X 130. B.H. 52–1346; A. F. I. P. Acc. No. 218757–73.

Figure 190. Higher power photomicrograph illustrates cell detail of this tumor. Nuclei are chiefly uniform in size, and cytoplasmic boundaries are indistinct. Many of the nuclei are hyperchromatic, while others are light staining and contain nucleoli. Hematoxylin and eosin stain. X 530. B.H. 52–1346; A. F. I. P. Acc. No. 218757–72.

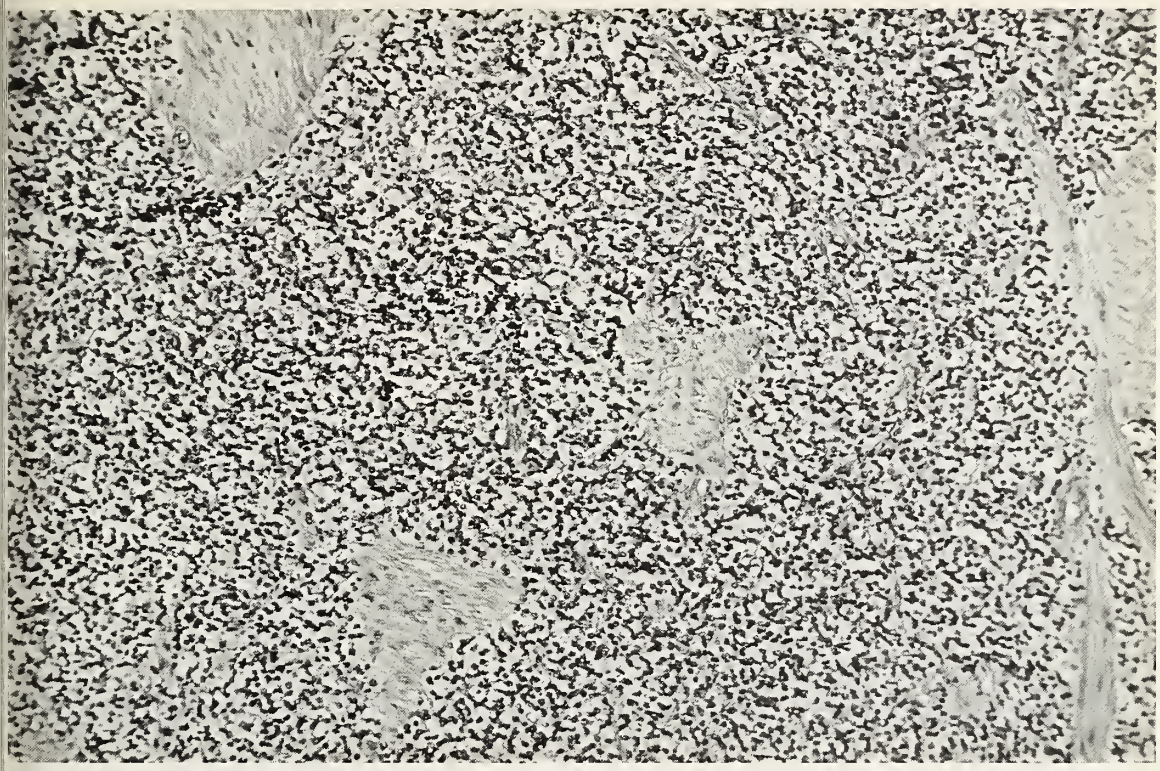

Fig. 189

Fig. 190

RETICULUM CELL SARCOMA

(Figures 191 and 192 are from the same case)

Figure 191. Histologic section showing typical primary reticulum cell sarcoma of bone. Cells in this section are monotonous in their characteristics. Nucleoli are fairly commonly seen. Hematoxylin and eosin stain. X 225. B.H. 53–2505; A. F. I. P. Acc. No. 218757–41.

Figure 192. This photomicrograph shows characteristic nuclei and indistinct cytoplasm of reticulum cell sarcoma at higher magnification. Hematoxylin and eosin stain. X 615. B.H. 53–2505; A. F. I. P. Acc. No. 218757–42.

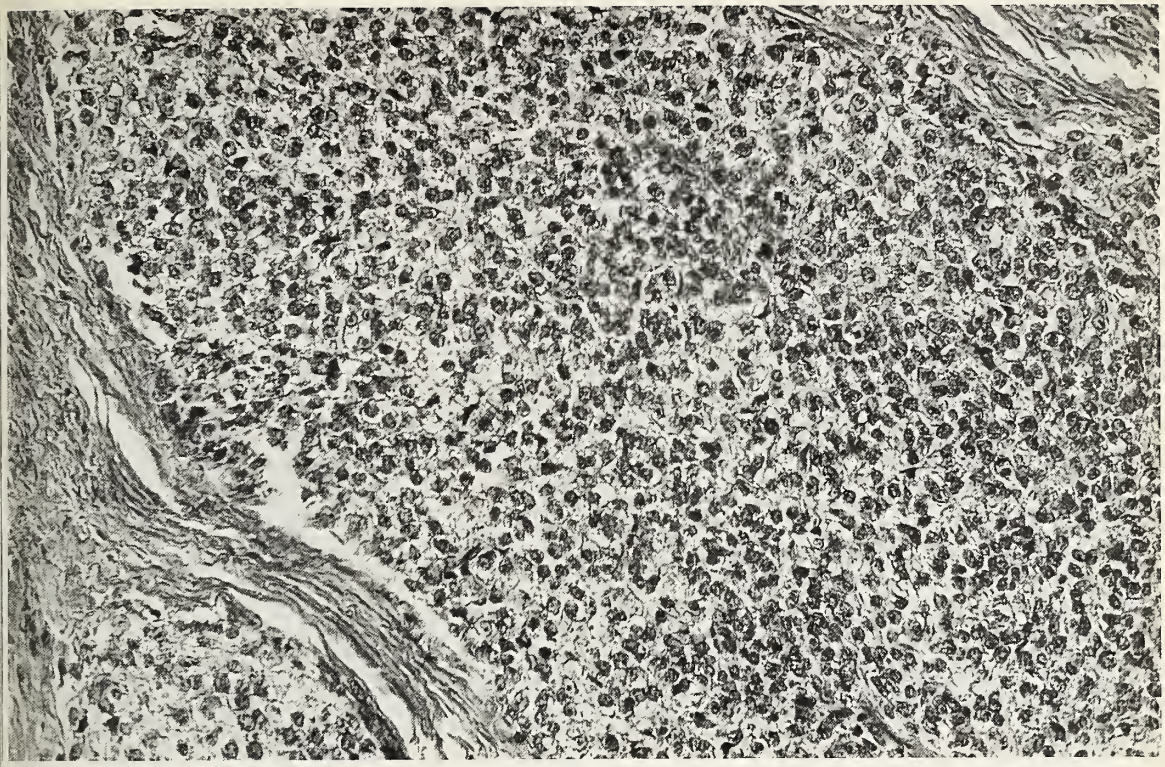

Fig. 191

Fig. 192

LIPOMA

(Figures 193 and 194 are from the same case)

Figure 193. Roentgenogram of an expanding cystic lesion of the fibula caused by a lipoma. (This is figure 2 [right] in Smith, W. E., and Fienberg, R. Intraosseous lipoma of bone. Cancer, 10:1151–1152, 1957.) A. F. I. P. Acc. No. 218757–251.

Figure 194. Histologic section through adult fat replacing marrow in this lipoma. Hematoxylin and eosin stain. X 615. (Courtesy of Dr. Robert Fienberg, Beverly, Mass.) A. F. I. P. Acc. No. 218757–254.

Figure 195. Antero-posterior and lateral radiographs of a distal phalanx of a thumb of a 70-year-old Negro woman show rarefaction and destruction of part of the marrow space and cortex. W.U. 57–6898, 99; A. F. I. P. Acc. No. 218757–252.

Figure 196. Photograph of a lipoma specimen from the right 6th rib in a young adult. Complete replacement of marrow cavity and destruction of cortical bone are seen. W.U. 58–887; A. F. I. P. Acc. No. 218757–253.

Fig. 193

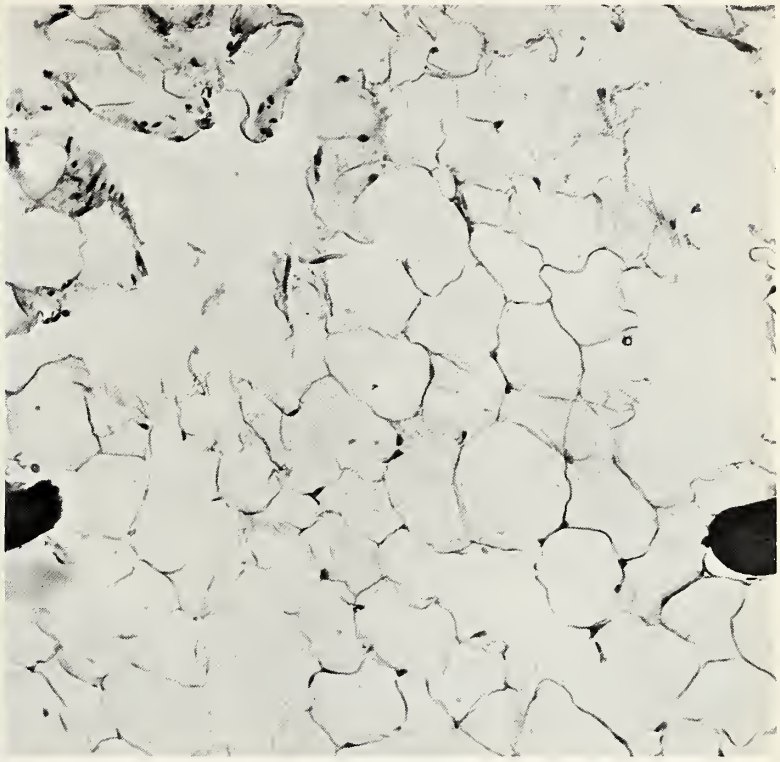

Fig. 194

Fig. 195

Fig. 196

LIPOSARCOMA

(Figures 197–202 are from the same case)

Figure 197.* This roentgenogram of a femur of a 28-year-old woman demonstrates destruction of medullary and cortical bone. A soft tissue component cannot be seen. A. F. I. P. Acc. No. 218757–255.

Figure 198.* Roentgenogram showing the distal portion of the bone. A. F. I. P. Acc. No. 218757–256.

Figure 199.* Mature and partially mature fat cells, some of which have a "signet-ring" cell appearance, are seen in the photomicrograph. Bizarre nuclei are present. Hematoxylin and eosin stain. X 300. A. F. I. P. Acc. No. 218757–21.

Figure 200.* Less well differentiated area of the tumor. In the photomicrograph, fat globules and bizarre nuclei are evident. Hematoxylin and eosin stain. X 410. A. F. I. P. Acc. No. 218757–24.

---

*Courtesy of Dr. E. K. Dawson, Edinburgh, Scotland.



Fig. 197



Fig. 198

Fig. 199

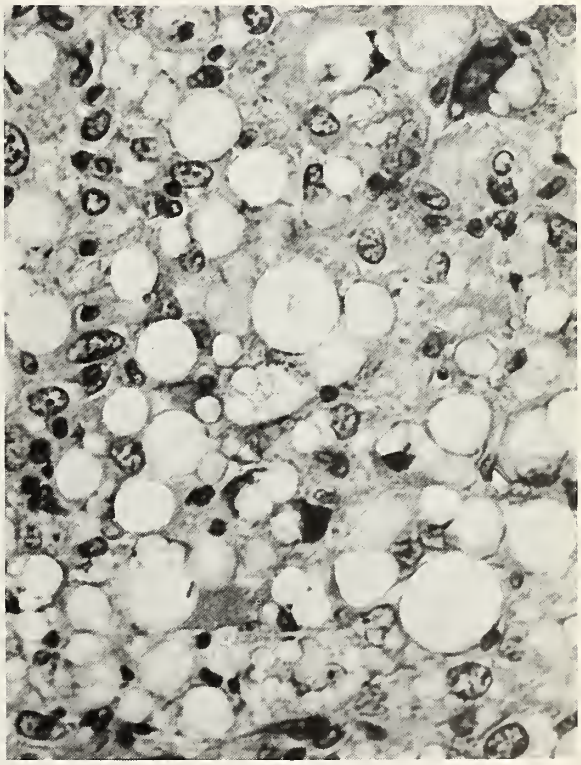

Fig. 200

LIPOSARCOMA

(Figures 197–202 are from the same case)

Figure 201.* Similar higher power microscopic field demonstrating "signet-ring" cells, fat globules, and bizarre nuclei. Hematoxylin and eosin stain. X 820. A. F. I. P. Acc. No. 218757–22.

Figure 202.* Undifferentiated area of the tumor. Hematoxylin and eosin stain. X 890. A. F. I. P. Acc. No. 218757–23.

*Courtesy of Dr. E. K. Dawson, Edinburgh, Scotland.

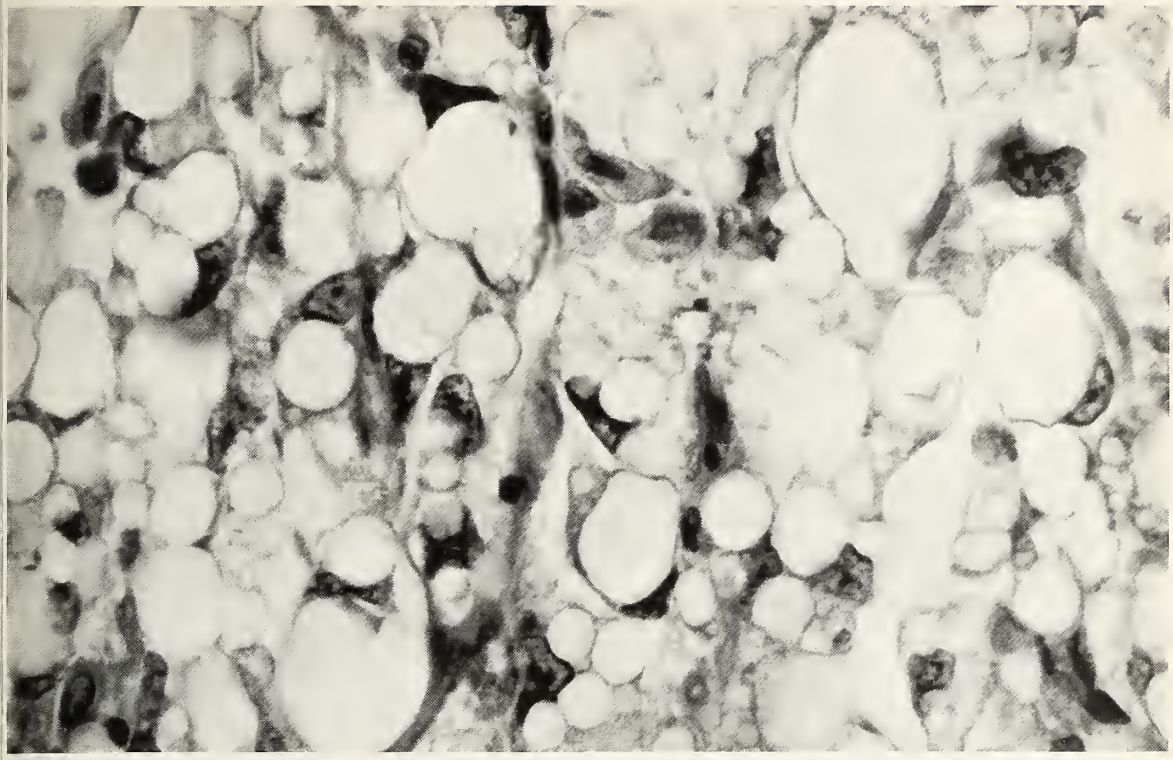

Fig. 201

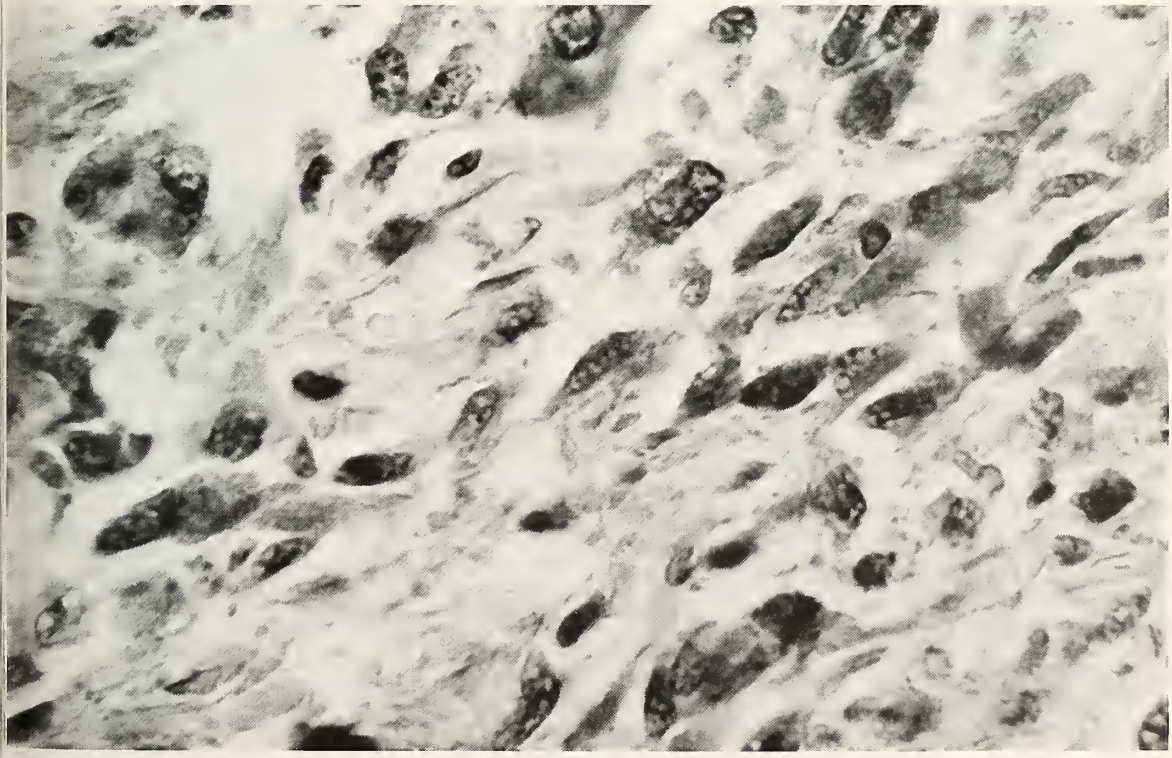

Fig. 202

TUMORS OF FIBROUS TISSUE ORIGIN—PRIMARY BENIGN AND MALIGNANT

Desmoplastic Fibroma

DEFINITION. An apparently benign fibrous tumor formed by collagen fibers and fibroblasts in an abundant intercellular substance.

INCIDENCE. Of 8 reported cases (Jaffe, 1958; Whitesides and Ackerman), 5 occurred in women and 3 in men; ages ranged from 8 to 40 years. In these, the following bones were involved: tibia 3, humerus 2, and femur, scapula, and ilium each 1.

CLINICAL DATA. Slight pain in the area of the tumor, swelling, and some restriction of motion of the affected part are common complaints noted by patients with desmoplastic fibroma.

PATHOGENESIS. Etiology and evolution of the tumor are not known.

GROSS. The lesion resembles soft tissue desmoids and periosteal desmoids. It may be confused with well differentiated fibrosarcomas. The appearance of a malignant tumor (figs. 203, 204) may be imparted when destruction of bone by expanding tumor is extensive, for bone is not re-formed by the tumor. Tumor tissue is resilient, firm, gray-white, or white and shiny. Cut surfaces may show small cystic foci.

MICROSCOPIC. Many collagen fibers and small benign-appearing fibroblasts with abundant intercellular substances compose the tumor (fig. 205). This cellularity and the collagen patterns not only vary in different tumors but from field to field in the same tumor. Mitotic figures, if present, are extremely rare. The bone formation which aids in distinguishing desmoplastic fibroma from fibrous dysplasia is not seen in uncomplicated cases.

TREATMENT. Adequate local resection of the tumor (fig. 206) is recommended, although thorough curettage may suffice in small lesions. Radiation therapy does not seem indicated. If treatment is inadequate, tumor may recur.

Fibrosarcoma

SYNONYMS AND RELATED TERMS: Central fibrosarcoma; endosteal fibrosarcoma; fibro spindle-cell sarcoma; medullary fibrosarcoma; osteofibrosarcoma.

DEFINITION. A malignant primary tumor having its origin from fibrous elements of the medullary spaces of bone.

INCIDENCE. This relatively rare malignant neoplasm comprises less than 4 percent of primary malignant bone tumors studied at Mayo Clinic (Dahlin). It has strong predilection for bones of the lower extremity, particularly the region of the knee, with approximately 80 percent of tumors occurring in the lower third of the femur and upper third of the tibia (Gilmer and MacEwen). Reportedly, it also occurs in the mandible, upper humerus, radius, ulna, rib, scapula, sacrum, ilium, proximal portion and shaft of the femur, and lower tibia.

In long bones the lesion is most likely to occur in the metaphysis, although in a few instances it has been observed in the shaft of a femur. There seems to be no such area of predilection for occurrence in the flat bones.

CLINICAL DATA. Symptoms and signs of fibrosarcoma of bone are not specific. Commonly, the patient complains of pain or a mass in the region of the tumor. The average duration of symptoms prior to the patient's seeking medical aid indicates a slow rate of growth. In the 22 cases studied by Gilmer and MacEwen, the average duration was eight months; however, 2 of these 22 patients had pulmonary metastases when admitted to the hospital (pl. IV; figs. 213–219). Pathologic fractures had occurred in five of them. The lesion tends to be solitary, except for the unusual case reported by Steiner in which there was multiple diffuse involvement of bones by fibrosarcoma. Tendency for local recrudescence is also known. Laboratory examinations are not rewarding.

Fibrosarcoma of bone occurs within an age range of 12 to 73 years, being most common in the second, third, and fourth decades. Late appearance of this lesion as compared to osteosarcoma is a point in favor of its being a primary lesion and not a variant of osteosarcoma. There is no evident sex predominance for distribution of the tumor.

Destructiveness of the lesion is one of its roentgen characteristics (figs. 207, 209) which makes it difficult to distinguish from an osteolytic osteosarcoma. With this osteolytic ability, it is not unusual for the tumor to erode through cortical bone and extend into soft tissues; this process was noted in a series of 50 cases studied by McLeod and associates. Periosteal bone reaction also may be seen. At the margins of the tumor there is usually slight sclerosis, said to be more distinct in better differentiated lesions. Patchy sclerosis occasionally may be seen throughout these tumors.

PATHOGENESIS. Some controversy exists as to the origin of fibrosarcoma. We and many other observers, including Jaffe (1947, 1958), Lichtenstein (1959), Dahlin, and Gilmer and MacEwen, believe that there is incontrovertible evidence clinically, grossly, and histologically to support the concept of primary fibrosarcoma of bone. Stout (1961) and Geschickter, however, deny existence of primary fibrosarcoma of bone; Stout believes that such tumors are really osteosarcomas which have failed to differentiate and are masquerading as true fibrosarcomas. While these latter two authors also believe that careful study of the lesion will uncover osteoid or cartilage, or that the lesion begins as a sarcoma of the periosteum or of adjacent soft tissues with secondary invasion of the underlying bone, we believe that fibrosarcomas arise from the supportive connective tissue of bone marrow and only rarely arise from periosteum. We further believe that the tumor is made up entirely of fibrous elements and that nowhere in a careful histologic examination will osteoid or cartilaginous formation be discerned as a component. If osteoid or cartilage should appear as

a part of the tumor, we feel that the lesion should be classified as an osteosarcoma. Often a surgeon seeking to biopsy a fibrosarcoma must incise an attenuated cortex in order to obtain a specimen. Supportive evidence thus is given to the impression that the tumor is a primary fibrosarcoma of the underlying bone.

Whether or not fibrosarcoma of bone arises from a precursive lesion is difficult to ascertain. Certainly fibrosarcoma can occur in Paget's disease of bone (Macdonald and Budd). Twelve of the 50 fibrosarcomas reported by McLeod and associates appeared to have originated in benign bone tumors; 10 occurred a long time after radiation therapy for a tumor, later proven a benign giant cell tumor of bone. Underlying benign lesions of the other two cases were not given.

GROSS. These tumors have a distinctive gross pattern (fig. 210). In totally excised specimens, pseudoencapsulation may occur in some areas of the tumor, so that it may be shelled out with relative ease. Areas of cystic degeneration, necrosis, and hemorrhage may be seen. Tumors may be irregular in shape, dependent on readily seen areas of bony destruction and extraosseous extensions. A few cases have been reported in which there has been a break through the adjacent joint surface. Some tumors are rounded, others ovoid. Appearance, when incised, is of a fleshy, soft, sometimes firm, grayish white to pink tumor (pl. III) which may be whorled and slightly lobulated. There is variance in size from 1 to 20 cm. in diameter (fig. 213).

MICROSCOPIC. The histologic pattern for this tumor is similar to that for fibrosarcoma of soft tissues (figs. 208, 211, 212); consequently, differentiation of these lesions may vary. McLeod and associates, for example, graded most of their fibrosarcomas as grades III and IV by Broder's classification. In the series of 22 cases studied and reported by Gilmer and MacEwen, 14 cases were grade II and 5 were grade III, with grade IV not being used. These series indicate that most of the lesions are only moderately well or poorly differentiated, a few being well differentiated. Well differentiated lesions (fig. 219) often contain mature-appearing collagen fibers, and such fibers may be difficult to differentiate from early osteoid formation.

At osseous edges of the tumors, bone destruction is apparent. In some areas in which degeneration has occurred, hemosiderin, macrophages, and occasionally multinucleated giant cells may be observed. However, over-all cellularity depends on the degree of differentiation (fig. 211). Nuclei, even in the most poorly differentiated cases, frequently are fairly uniform in outline (fig. 212). Multinucleated forms and bizarre nuclear forms may be seen but should be few in number (fig. 211), for histologic interpretation as to malignancy may hinge on only a few cellular aberrations and may be difficult. As Stout (1948) has pointed out, if numerous bizarre nuclear forms and multinucleated forms are seen, it is likely that the lesion is not fibrosarcoma but a sarcoma of some other origin.

TREATMENT. The most successful form of therapy seems to be ablative surgery, since radiation therapy has not been successful.

PROGNOSIS. Three of the patients in the series of Gilmer and MacEwen survived for long periods when treated with Coley's toxins and amputation. One died at five years and one month and two are still living. This five year survival rate seemed related to the degree of differentiation of the tumor. For instance, no patient with grade III fibrosarcoma survived five years, even though the over-all five year survival rate was 17.6 percent, or 26.3 percent if grade I tumors were included. This closely parallels reports of the Mayo Clinic group of a five year survival rate for this tumor, which is 26.8 percent. Of cases from the Registry of Bone Sarcoma studied by Macdonald and Budd, there was a 31.4 percent five year survival rate. From these three large series, it is apparent that the five year survival rate of fibrosarcoma is better than that of osteosarcoma. This again is evidence suggesting that this lesion is not an osteosarcoma.

TUMORS ARISING FROM FIBROUS TISSUE (UNCERTAIN)

Giant Cell Tumor

SYNONYMS AND RELATED TERMS: Giant cell sarcoma; osteoclastoma; tumeur à myèloplaxes.

DEFINITION. A neoplasm occurring within bone and apparently arising from its connective tissue framework.

INCIDENCE. These single lesions invariably stem from the epiphysis, with secondary involvement of the metaphysial area. If a lesion is located in the metaphysial area of a bone without involving the epiphysis, probability is high that it is not a giant cell tumor. However, Jaffe (3rd reference) stated that he had seen one case of giant cell tumor in which the lesion was solely in a metaphysis, and we have seen two examples in which the tumor was apparently limited to the metaphysial portion of a radius.

Occurrence of giant cell tumors is rare before the age of 20 or after the age of 55 years. Any series of cases in which there is a disproportionate number of patients below age 20 should be viewed with suspicion.

SITES OF TUMOR. Commonest locations for this neoplasm are the ends of long bones, particularly the lower third of a femur and a radius, or the upper third of a tibia (fig. 220). These sites comprise about 65 percent of cases; moreover, the percentage will be raised to 80 percent (Jaffe, 3rd reference), if other lesions in long bones are added.

Table II is a composite of three series of lesions studied; this indicates that bones other than long bones, such as flat bones of the pelvis, can be involved. Giant cell tumor involvement of the skull in association with Paget's disease also has been seen (Russell; Jaffe, 3rd reference). Like Jaffe, however, we believe true giant cell tumors of the vertebrae are rare. Most giant cell lesions in the maxilla and mandible are not true neoplasms and fall into a group designated by Jaffe as giant cell reparative granuloma.

Table II

BONES INVOLVED BY GIANT CELL TUMOR

Bone	Series		
	Murphy-Ackerman	Dahlin	Windeyer-Woodyatt
Upper Extremity:			
Humerus			
proximal	2	2	5
Radius			
proximal	.....	1	.....
distal	2	10	1
Ulna			
distal	1	4	.....
Hand—small bones	1	.....	.....
Rib	.....	1	.....
Scapula	.....	.....	1
Vertebrae	4	.....	5
Lower Extremity:			
Sacrum	.....	9	4
Ilium	.....	5	.....
Ischium	.....	.....	1
Femur			
proximal	1	1	5
distal	6	32	4
Patella	.....	.....	1
Tibia			
proximal	6	22	5
distal	1	3	3
Fibula			
proximal	.....	6	1
Foot—small bones	.....	1	.....

GROSS. Since these uncommon neoplasms are usually confined to small bones of the hands, gross examination of intact, untreated tumors is infrequent. They usually are eccentrically located in the epiphyses and the metaphyses and have sharp borders. They are composed of vascular, grayish red tissue, with perhaps zones of necrosis, flecks of yellow (pl. V–A, B), and areas of trabeculation extending across cystic cavities (fig. 225). Commonly the cortex is thinned; therefore, it is not rare to find evidence of tumor extending through the cortex into soft tissues (figs. 237, 238). If a tumor becomes larger, it extends

toward the joint and may even cross it. When crossing the joint to involve another bone, the tumor usually passes around an involved bone; this course was followed in the case of Windeyer and Woodyatt, where it spread from the head of the femur across the joint space into the ilium (figs. 224, 225).

Gross examination of specimens may be complicated by the facts that the lesion failed to respond to therapy and has persisted and that the bone chips of prior treatment remain. Fracture into larger tumors in weight-bearing bones is not uncommon, but periosteal reactive bone is uncommon.

MICROSCOPIC. Basic microscopic pattern of a giant cell tumor is that of a moderately vascularized stroma associated with rather plump spindle-shaped or ovoid-shaped cells regularly interspersed by giant cells. The latter have multiple nuclei, sometimes numbering 50 to 100 (figs. 226, 240), and areas of scarring; cyst formation, hemorrhage, and foam cells also may be present. Presence of osteoid is not rare (figs. 226, 236). Although we have found osteoid in 9 of 27 consecutive cases, we have never seen cartilage in a giant cell tumor.

Microscopic patterns may be complicated when sections are taken from an area of previous fracture. We have observed, with others, that adult reactive bone may be present around peripheral margins of the tumors as they extend into soft tissues (fig. 240). We have also seen reactive bone formation in the peripheral margins of metastases in the lungs.

Jaffe (3rd reference) emphasized the importance of histologic grading of these neoplasms, with particular emphasis on the stromal components of the tumors. He noted that the degree of malignancy increases (1) as stromal cells become more prominent, with an accompanying prominence of nuclei and increase of mitotic figures; and (2) giant cells decrease in number, with increased mitotic activity. Accordingly he divided giant cell tumors into grades I, II, and III. If a giant cell tumor shows zones of malignant change as in grade III, we have found this to be of significance, for these changes correlate with possibilities of local recrudescence and distant metastases. However, in well differentiated grade I tumors, a few neoplasms may behave in an unorthodox fashion. Here, it also must be emphasized that needle biopsy of such apparent grade I lesions may not show the most undifferentiated zone; if curettement is done, multiple sections must be taken to be certain that the most malignant areas are found. Since it is also often impossible to predict the outcome of grade II lesions, we are prone to find grading of limited value.

VARIANTS. There is no doubt that a malignant variant of giant cell tumor exists (figs. 230–232, 234, 235). With clarification of the entity, giant cell tumor of bone, various series reported now include only true giant cell tumors; therefore, in a given series of true giant cell tumors, probably as many as 15 to 20 percent of the cases will be malignant. Since it is known that perforation of the cortex by tumor has no clinical significance in determining benignancy versus malignancy, how then can status of the tumors be recognized?

It must be emphasized that there already have been numbers of cases in which metastasizing tumor has had a benign appearance (Murphy and Ackerman; Jaffe, 3rd reference; figs. 227–229) and yet may cause death of the patient. There are other instances in which, after a given period of time, the tumor has recurred and produced a microscopic picture obvious of recrudescence as a malignancy. The question therefore arises whether this tumor became malignant, or was malignant at the time of the first operation. In one of our cases, restudy by further sectioning of available material from the first operation indicated that the tumor was obviously malignant from its inception. However, cases with subtle progression from benign to malignant patterns have been reported in the literature. When attempting diagnosis of a tumor on its histologic pattern only, it may be assumed that if the stroma shows fibrosarcomatous changes (figs. 234, 235) the tumor will behave as a malignant neoplasm. It used to be considered that the giant cells are closely related to stromal cells in that their nuclei are similar. Furthermore, a giant cell tumor was grown in tissue culture and appeared to form from a fusion of the stromal cells (Morton). Evidence against the origin of giant cells from stromal cells is that the cytoplasm of the giant cells shows a strong acid phosphatase reaction. This reaction is negative for stromal cells (Pepler).

TREATMENT. If the tumor is well defined, it seems logical that local resection of lesions which can be excised without producing deformity is indicated; however, treatment of giant cell tumors is still not clarified. Well planned radiation therapy seems to give good results (Eyre-Brook et al.; figs. 222, 223), and in inaccessible areas such as bones of the pelvis it seems especially indicated (Johnson and Dahlin). We feel that in reported cases of development of osteosarcoma following irradiation of a giant cell tumor the sarcoma is directly related to the radiation therapy and probably is unrelated to the previously existing giant cell tumor. Curettage of the lesion with replacement of the specimen by bone chips has been done with good results for lesions in long bones.

It must be remembered that if the histologic diagnosis of giant cell tumor is accurate, this neoplasm represents a serious therapeutic problem. About one half of the cases will have a favorable outcome if properly treated. One-third are likely to recur after treatment (fig. 221), and a percentage of these may need amputation (fig. 233). About 15 percent will be neoplasms which most commonly metastasize to the lungs (Lichtenstein, 1951).

DIFFERENTIAL DIAGNOSIS. The presence of giant cells within many lesions of bone has obscured the differential diagnosis of giant cell tumor from such lesions as metaphysial fibrous defect, unicameral bone cyst, osteoid osteoma, chondroblastoma, chondromyxoid fibroma, osteitis fibrosa cystica, fibrous dysplasia, eosinophilic granuloma, and even osteosarcoma. Histochemical studies unfortunately are of no diagnostic aid in differentiating giant

cell tumor from its so-called variants (Schajowicz). When giant cell tumor of bone appears in a typical location and shows involvement of the epiphysis and metaphysis, however, radiographic diagnosis frequently will distinguish it from chondroblastoma, plasma cell myeloma, aneurysmal bone cyst, and fibrosarcoma which have all at times been confused with the tumor.

Jaffe (3rd reference) and Eyre-Brook and associates have reported patients without evidence of hyperparathyroidism in whom apparently there were typically located multiple giant cell tumors with typical microscopic patterns. In hyperparathyroidism, there is generalized disease of bones (see Fascicle 15, "Tumors of the Parathyroid Gland"); therefore, it is rare for an apparently single manifestation of this disease to present as a clinical problem. When it occurs, however, it presents in either the metaphysis or diaphysis, but does not involve the epiphysis. Histologically, it should not be confused with giant cell tumor of bone because its tremendous bone activity gives a varied histologic pattern. "Brown tumors" also aid in this distinction, as do alterations which are invariably present in serum chemistries. Further discussions of the differential diagnosis of these various lesions from giant cell tumor are included in appropriate fascicle sections.

References

Batts, M., Jr. Periosteal fibrosarcoma. Arch. Surg., 42:566–576, 1941.

Burton, M. E. Well-differentiated fibrosarcoma of the scapula. A case report. Bull. Hosp. Joint Dis., 15:85–89, 1954.

Buschke, F., and Cantril, S. T. Roentgentherapy of benign giant-cell tumor of bone. Cancer, 2:293–315, 1949.

Cahan, W. G., Woodard, H. Q., Higinbotham, N. L., Stewart, F. H., and Coley, B. L. Sarcoma arising in irradiated bone. Report of eleven cases. Cancer, 1:3–29, 1948.

Dahlin, D. C. Bone Tumors. Benign Giant Cell Tumor (Osteoclastoma), pp. 66–75; Malignant Giant Cell Tumor, pp. 164–171; Fibrosarcoma, pp. 178–183. Springfield, Ill.: Charles C Thomas, 1957.

_____, Ghormley, R. K., and Pugh, D. G. Giant cell tumor of bone: differential diagnosis. Proc. Staff Meet. Mayo Clin., 31:31–42, 1956.

Dyke, S. C. Metastasis of the "benign" giant-cell tumour of bone (osteoclastoma). J. Path. & Bact., 34:259–263, 1931.

Eyre-Brook, A. L., Thomson, A. D., and Sissons, H. A. Discussion: giant cell tumour of bone and related conditions. Proc. Roy. Soc. Med., 49:409–422, 1956.

Geschickter, C. F. So-called fibrosarcoma of bone. Bone involvement by sarcoma of the neighboring soft parts. Arch. Surg., 24:231–291, 1932.

Gilmer, W. S., Jr., and MacEwen, G. D. Central (medullary) fibrosarcoma of bone. J. Bone & Joint Surg., 40–A:121–141, 1958.

Jaffe, H. L. Tumors of the skeletal system: pathological aspects. Bull. New York Acad. Med., 23:497–511, 1947.

_____. Giant-cell reparative granuloma, traumatic bone cyst, and fibrous (fibro-osseous) dysplasia of the jawbones. Oral Surg., 6:159–175, 1953.

_____. Giant-cell tumour (osteoclastoma) of bone: its pathologic delimitation and the inherent clinical implications. Ann. R. Coll. Surgeons England, 13:343–355, 1953.

DESMOPLASTIC FIBROMA

(Figures 203–206 are from the same case)

Figure 203. Roentgenogram of a destructive lesion of the proximal portion of a humerus, interpreted as a malignant bone tumor. This occurred in a 33-year-old white woman who had had pain, in the region of the right deltoid muscle, intermittently for nine years. The pain apparently had been accentuated by pregnancies. W.U. 54–125; A. F. I. P. Acc. No. 218757–194.

Figure 204. Photograph showing that the well circumscribed fibrous mass of the excised specimen was partly cystic. It had extended partially down the shaft of the humerus and had destroyed and replaced the bone. W.U. 53–6405; A. F. I. P. Acc. No. 218757–195.

Figure 205. This microscopic field is representative of the many blocks of tissue cut from this tumor. It had originally been diagnosed as well differentiated fibrosarcoma. Note the few nuclear aberrations. Hematoxylin and eosin stain. X 400. W.U. 54–103; A. F. I. P. Acc. No. 218757–196.

Figure 206. Follow-up roentgenogram 3.5 years after excision shows the fibula graft in place and no persistent tumor. The patient was well at least four years after excision of the tumor. W.U. 58–3853; A. F. I. P. Acc. No. 218757–197.

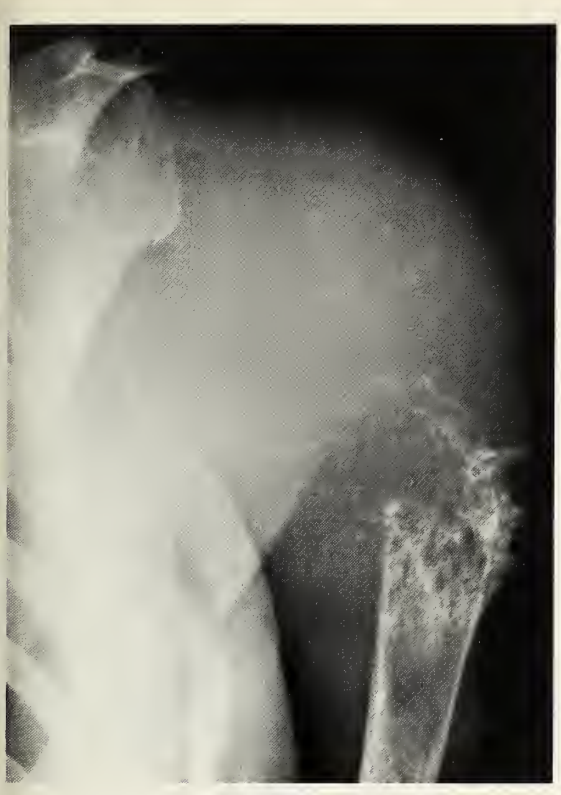

Fig. 203

Fig. 204

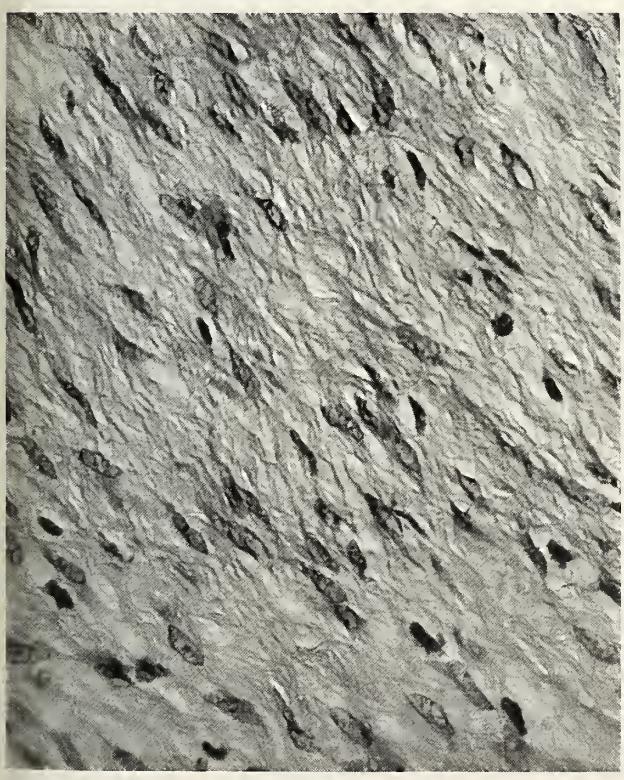

Fig. 205

Fig. 206

FIBROSARCOMA

(Figures 207, 208, and plate III are from the same case. Figures 209–211 are from the same case)

Figure 207. Scalloped margins and destruction of cortical and cancellous bone are evident in the roentgenogram of this fibrosarcoma. The lesion also has a multicystic appearance. W.U. 57–893; A. F. I. P. Acc. No. 218757–189.

Figure 208. This histologic section shows the lesion as well differentiated with a few hyperchromatic bizarre nuclei. Hematoxylin and eosin stain. X 275. W.U. 58–3896; A. F. I. P. Acc. No. 218757–190.

Figure 209. Fibrosarcoma of the distal portion of a radius of a 10-year-old girl. A destructive lesion is seen on the roentgenogram but still appears fairly well circumscribed. W.U. 53–4086; A. F. I. P. Acc. No. 218757–191.

Figure 210. A well circumscribed tumor, replacing marrow space and destroying cortex in this sagittal section through the tumor. The hemorrhagic area between the tumor nodules represents the site of previous curettement. W.U. 53–4069; A. F. I. P. Acc. No. 218757–192.

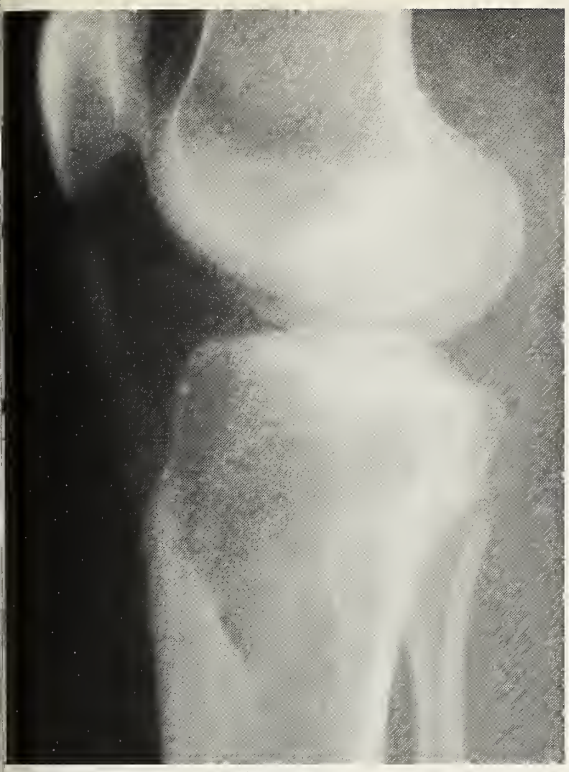

Fig. 207

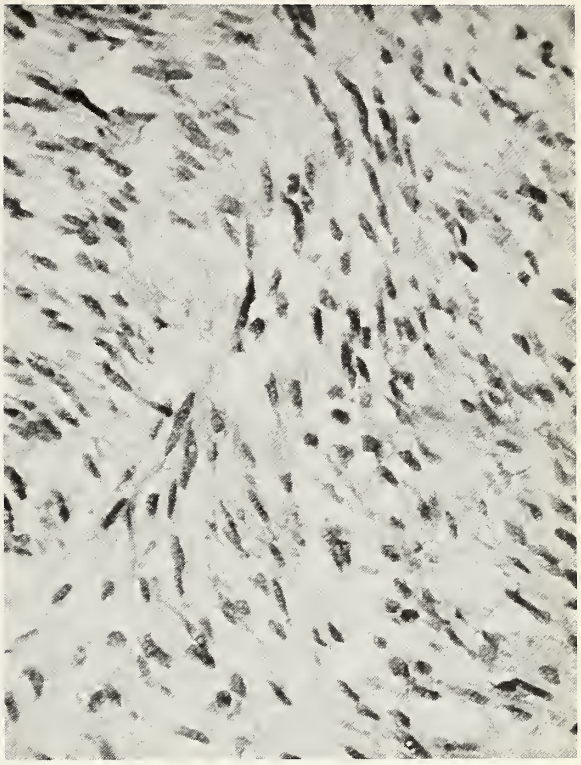

Fig. 208

Fig. 209

Fig. 210

FIBROSARCOMA

(Figures 209–211 are from the same case)

Figure 211. This representative microscopic field from the fibrosarcoma has bizarre nuclei evidencing poor differentiation. Hematoxylin and eosin stain. X 615. B.H. 53–3973; A. F. I. P. Acc. No. 218757–48.

Figure 212. The histologic pattern of this cellular, poorly differentiated fibrosarcoma, primary in the right femur, is similar to a fibrosarcoma of soft tissues. Hematoxylin and eosin stain. X 275. B.H. 53–623; A. F. I. P. Acc. No. 218757–193.

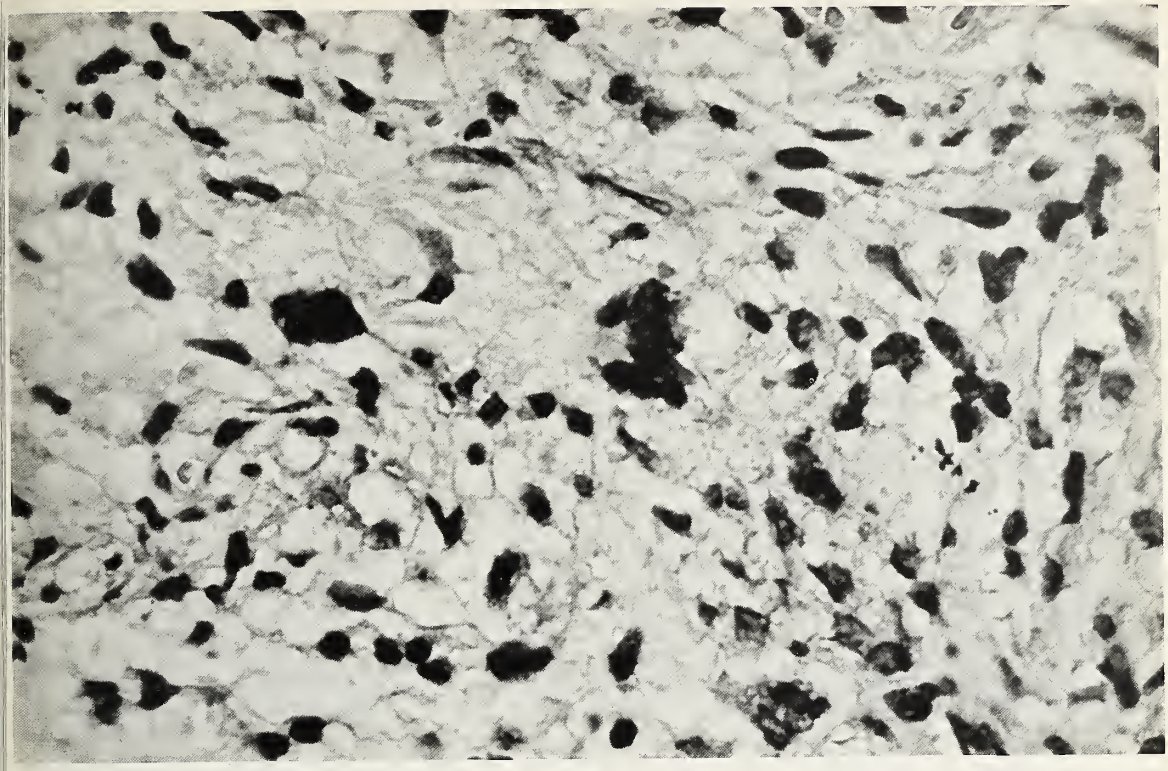

Fig. 211

Fig. 212

FIBROSARCOMA

(Figures 213–216 and plate IV are from the same case)

Figure 213.* Cross section of a fibrous mass, of three months' duration, removed Sept. 1956, from the right thigh of a 24-year-old woman. Histologically it was interpreted as a desmoid, with the atypical feature of osteoid formation. W.U. 56–4966; A. F. I. P. Acc. No. 218757–199.

Figure 214.* This histologic section from the recurrent periosteal sarcoma shows no mitotic figures. However, nuclei are hyperchromatic and atypical. The original lesion (fig. 213) was histologically similar to this. The patient was alive and well April 1961. Hematoxylin and eosin stain. X 150. B.H. 57–2200; A. F. I. P. Acc. No. 218757–200.

*Courtesy of Dr. D. O. Burst, St. Louis, Mo.

Fig. 213

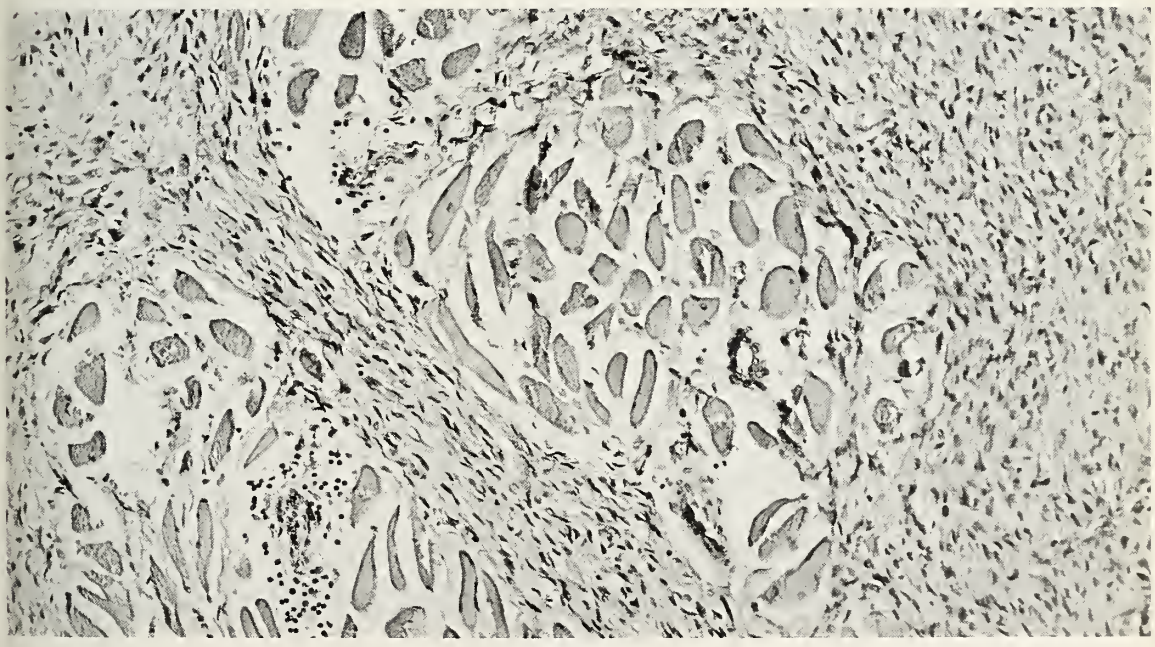

Fig. 214

FIBROSARCOMA

(Figures 213–216 and plate IV are from the same case)

Figure 215.* Another microscopic field shows osteoid formation and calcified osteoid, while the stroma has the appearance of a desmoid. Hematoxylin and eosin stain. X 225. B.H. 57–2200; A. F. I. P. Acc. No. 218757–201.

Figure 216.* Higher power microscopic view of this stroma shows atypical nuclei with their relationship to the skeletal muscle. The nuclear changes, rapid reappearance of the tumor, and the size it attained in this period of growth confirmed the impression of periosteal sarcoma. Hematoxylin and eosin stain. X 615. B.H. 57–2200; A. F. I. P. Acc. No. 218757–202.

---

*Courtesy of Dr. D. O. Burst, St. Louis, Mo.

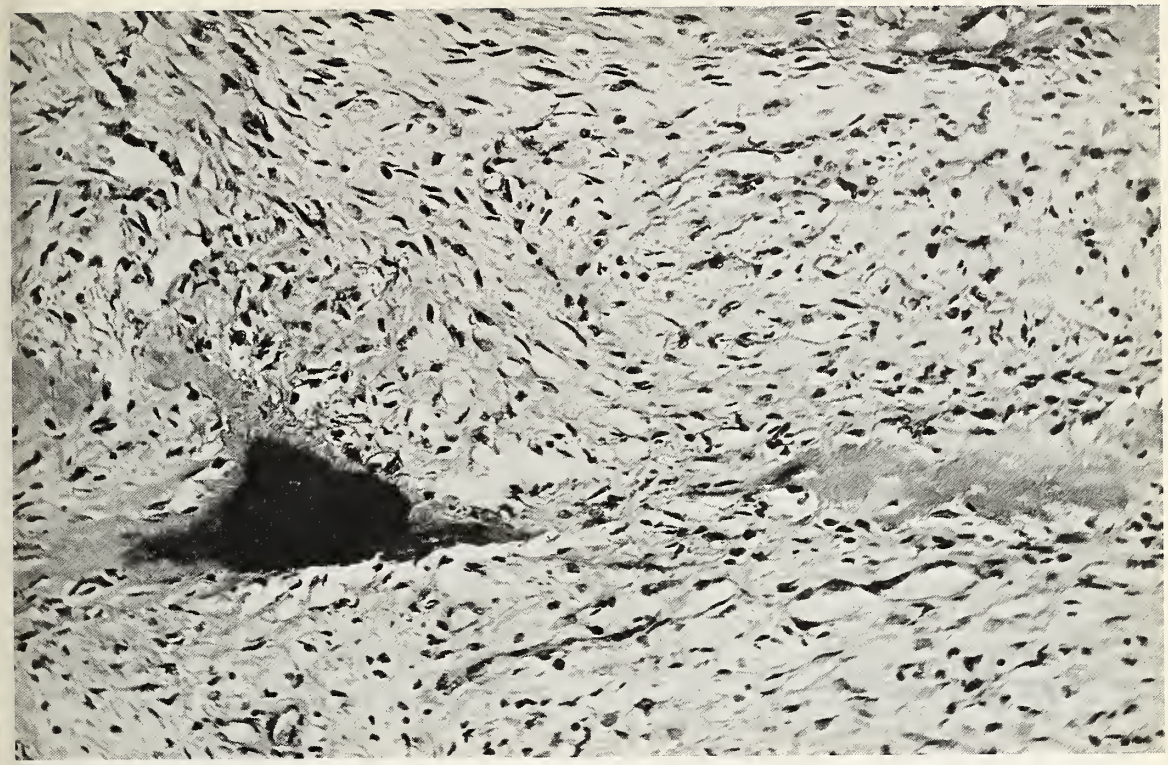

Fig. 215

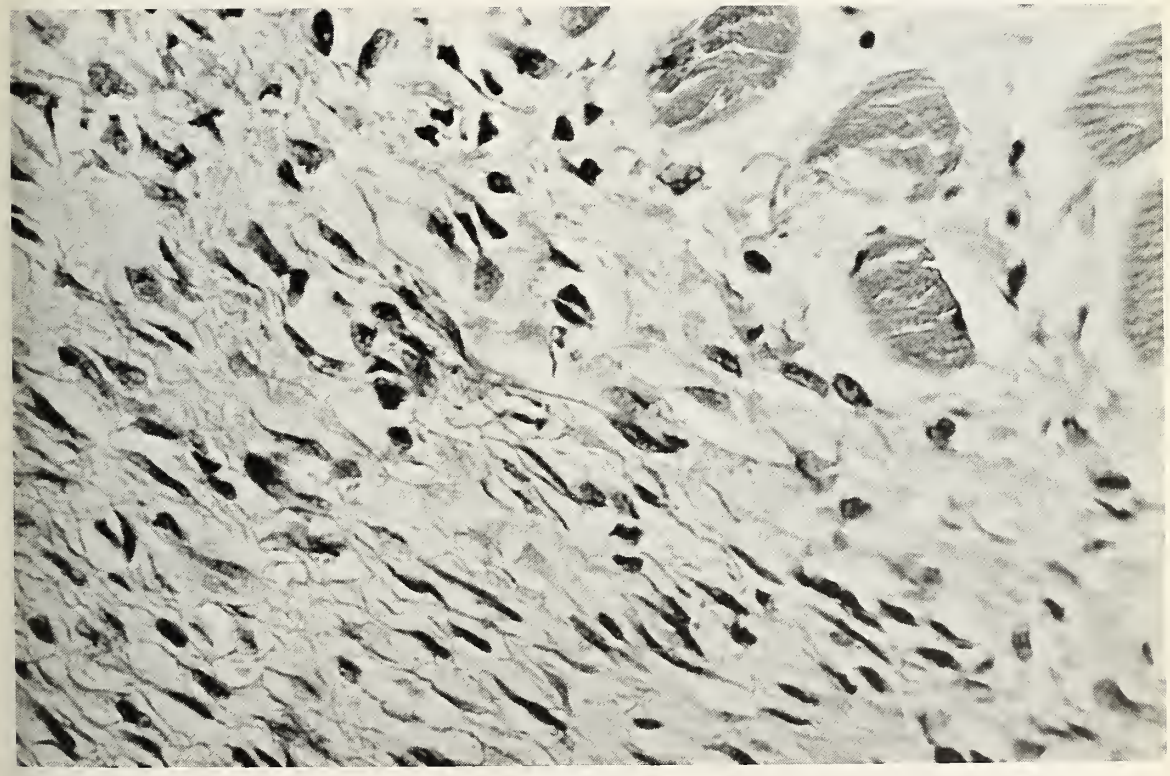

Fig. 216

FIBROSARCOMA

(Figures 217–219 are from the same case*)

Figure 217. Resected specimen of a tumor of the distal portion of a femur of a 25-year-old woman. The mass seemed to be extracortical with no medullary component. This feature was confirmed by histologic examination, and the tumor therefore was considered a periosteal fibrosarcoma. A. F. I. P. Acc. No. 218757–360.

Figure 218. Hemisection of this specimen. A. F. I. P. Acc. No. 218757–390.

Figure 219. Photomicrograph illustrating the pattern of a well differentiated fibrosarcoma. Hematoxylin and eosin stain. X 275. W.U. 58–5016; A. F. I. P. Acc. No. 218757–361.

---

*Courtesy of Dr. E. Uehlinger, Zurich, Switzerland.

Fig. 217

Fig. 218

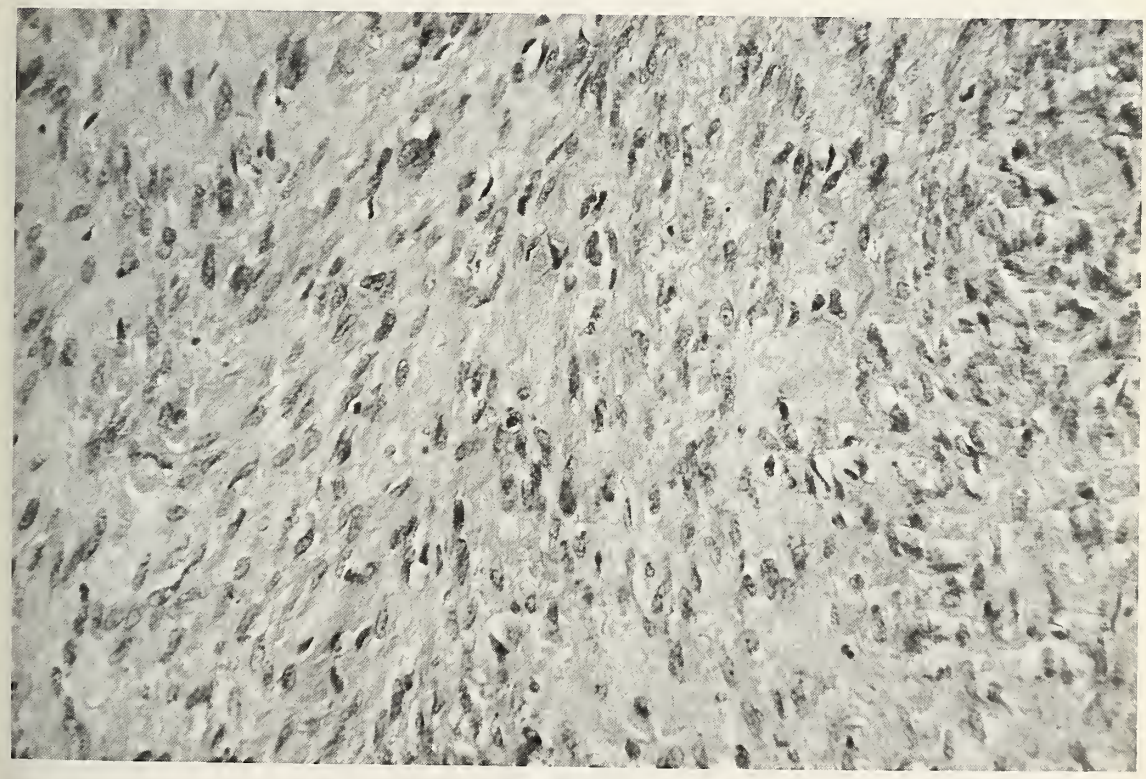

Fig. 219

GIANT CELL TUMOR

(Figure 220 and plate V–A, B are from the same case. Figures 222 and 223 are from the same case)

Figure 220. Roentgenogram illustrating an extensively destructive giant cell tumor of the proximal portion of the right femur. Note destroyed cortex and tumor extending into soft tissues. (Courtesy of Dr. L. W. Gardner, Detroit, Mich.) W.U. 54–3729; A. F. I. P. Acc. No. 218757–203.

Figure 221. Roentgenogram of a giant cell tumor of the right first metacarpal of an 18-year-old girl. Extensive bony destruction and soft tissue component of the tumor are outlined. After biopsy, radiation therapy was administered. Nine months later presence of persistent tumor was proved. W.U. 53–6697; A. F. I. P. Acc. No. 218757–220.

Figure 222. Giant cell tumor of a radius of a 16-year-old girl. The roentgenogram shows an eccentric expanding multicystic tumor and suggests irregular periosteal bone formation. The lesion was initially treated by curettage followed by radiation therapy. W.U. 53–6695; A. F. I. P. Acc. No. 218757–218.

Figure 223. A roentgenogram taken 11 years after completion of radiation revealed no evidence of persistent tumor. W.U. 55–92; A. F. I. P. Acc. No. 218757–219.

Fig. 220

Fig. 221

Fig. 222

Fig. 223

GIANT CELL TUMOR

(Figures 224–226 are from the same case)

Figure 224.* Roentgenogram of a giant cell tumor of the distal portion of a femur. Note the multiloculated appearance of the tumor area, its extension up the shaft of the femur, and destruction of cortex posteriorly. A. F. I. P. Acc. No. 218757–204.

Figure 225.* Sagittal section of the resected tumor confirmed the impression of multiple cysts, cortical destruction, and extension up the shaft of bone. Areas of hemorrhagic necrosis and typical fibrous-like stroma were also noted. A. F. I. P. Acc. No. 218757–205.

Figure 226. Histologic pattern of an area from the specimen shows osteoid formation, few multinucleated giant cells, numerous blood vessels, and loose stroma. Hematoxylin and eosin stain. X 275. W.U. 58-3095; A. F. I. P. Acc. No. 218757–221.

---

*From Sissons, H. A. Malignant Tumours of Bone and Cartilage. In: Raven, R. W. (ed.). Cancer, pp. 324–349. Vol. II. London: Butterworth & Co., Ltd., 1958. Figures 202 and 203 are fascicle figures 224 and 225.

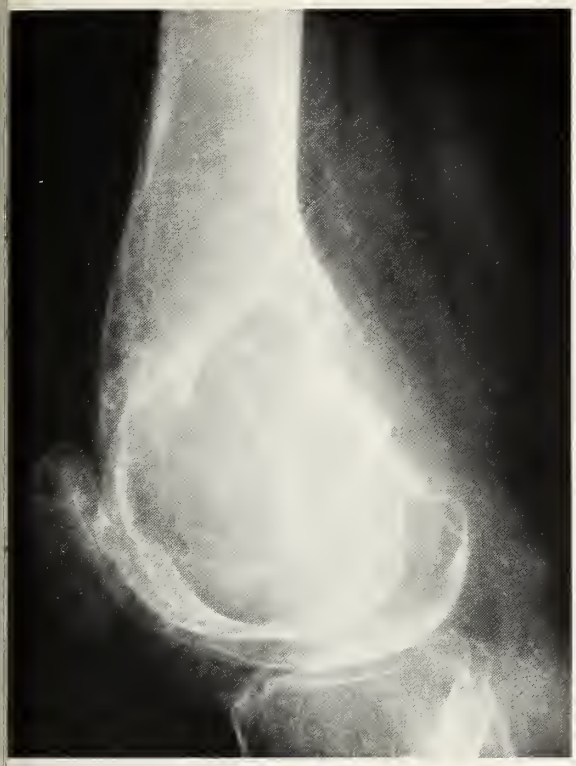

Fig. 224

Fig. 225

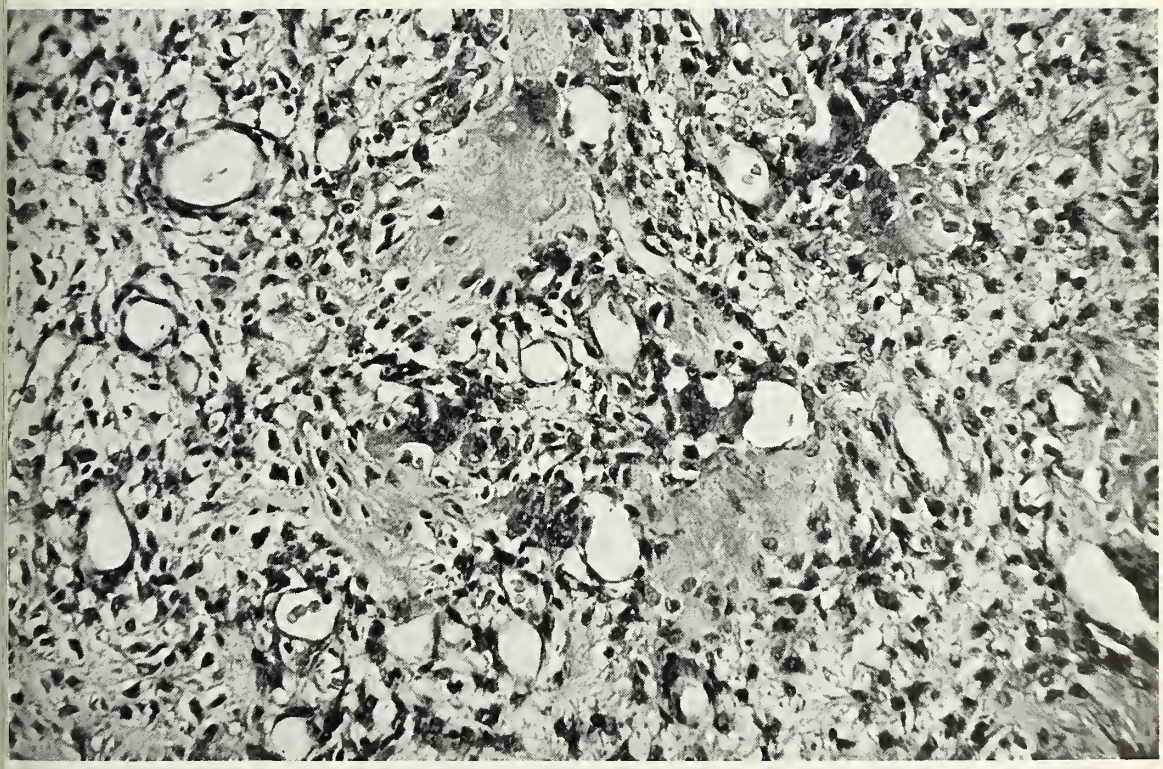

Fig. 226

GIANT CELL TUMOR

(Figures 227–229 are from the same case)

Figure 227. Roentgenogram of a giant cell tumor of the distal radius of a 44-year-old man who had had pain in his wrist. When the tumor area was explored, the frozen section was interpreted as malignant, and an above-the-wrist amputation was performed. W.U. 54–5030; A. F. I. P. Acc. No. 218757–206.

Figure 228. Roentgenogram of the chest of this patient five years after the amputation revealed a well circumscribed density in the right upper lobe of the lung (note arrow). W.U. 54–471; A. F. I. P. Acc. No. 218757–207.

Figure 229. The photomicrograph shows the benign pattern of this metastatic lung lesion and is similar to the histologic sections from the primary tumor. The patient remains well 15 years after lobectomy. Hematoxylin and eosin stain. X 400. W.U. 54–3647; A. F. I. P. Acc. No. 218757–208.

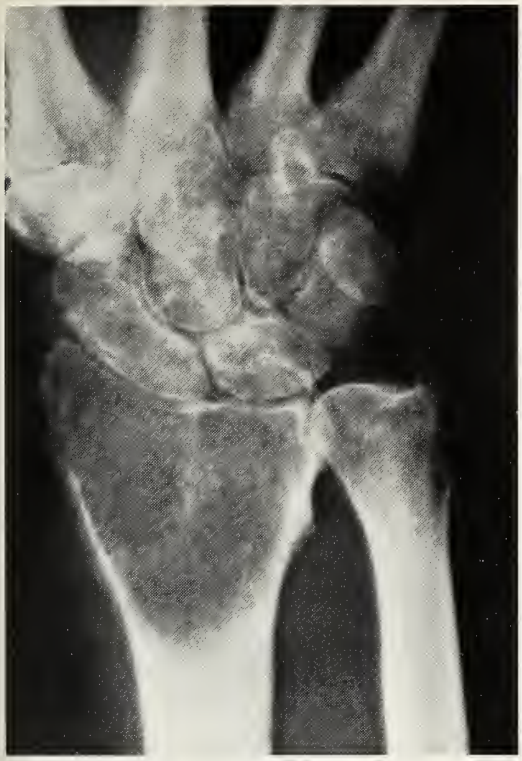

Fig. 227

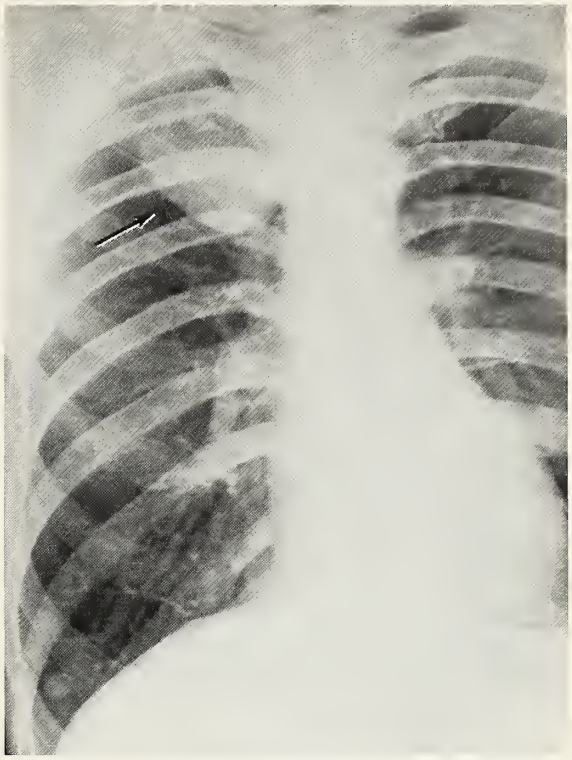

Fig. 228

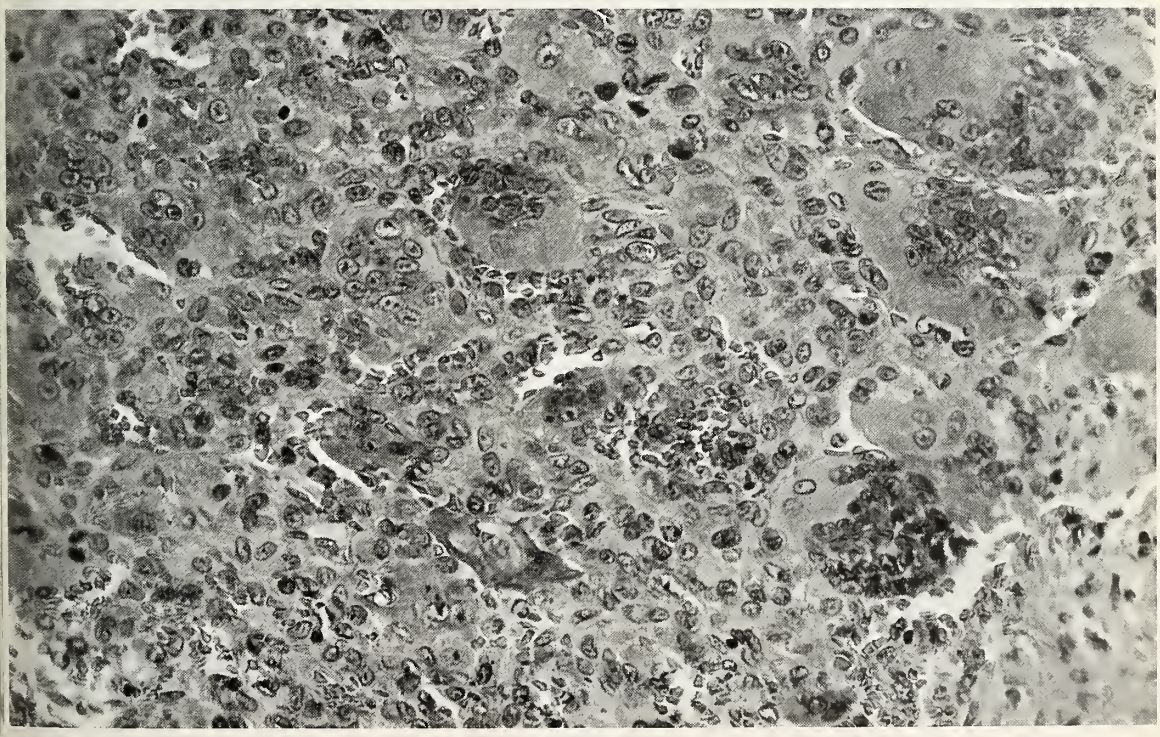

Fig. 229

GIANT CELL TUMOR

(Figures 230–235 are from the same case)

Figure 230. Lateral roentgenographic view of the cystic, slightly expanded defect of the distal femur of a 58-year-old man. W.U. 49–5963; A. F. I. P. Acc. No. 218757–210.

Figure 231. Antero-posterior view of the defect. Since this was diagnosed as a malignant giant cell tumor, it was irradiated without prior biopsy. During therapy, fracture through a cystic area of the bone occurred, which necessitated curettage and replacement by bone chips. W.U. 49–5963; A. F. I. P. Acc. No. 218757–211.

Figure 232. Histologic section of the giant cell tumor removed by curettage following the fracture shows edematous stroma with few atypical nuclei. Hematoxylin and eosin stain. X 200. W.U. 54–3648; A. F. I. P. Acc. No. 218757–212.

Figure 233. Hemisection of the amputated specimen obtained during disarticulation of the femur; amputation followed recurrence of the tumor 14 months after completion of radiation therapy. Note residual tumor impinging on articular surfaces of the bone and the breakdown of the cortex. W.U. 50–663; A. F. I. P. Acc. No. 218757–209.

Fig. 230

Fig. 231

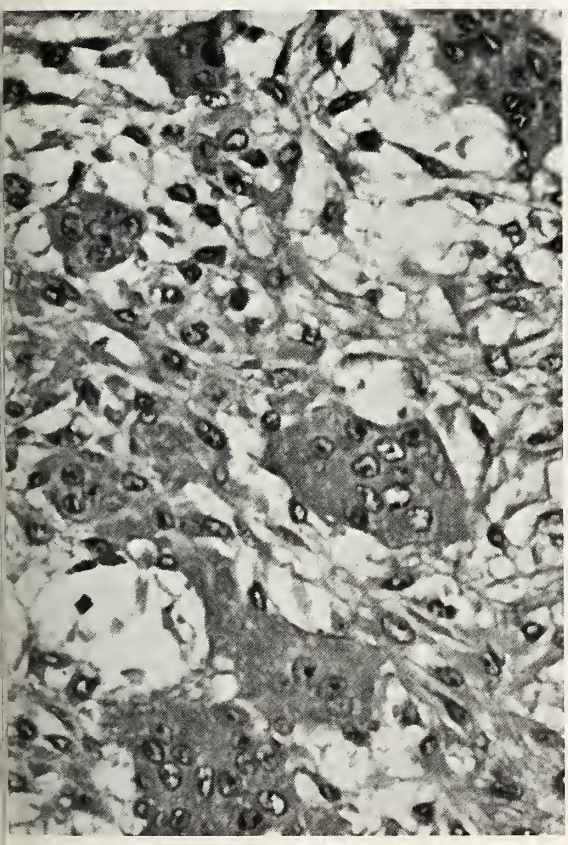

Fig. 232

Fig. 233

GIANT CELL TUMOR

(Figures 230–235 are from the same case)

Figure 234. Section of the recurrent giant cell tumor after radiation therapy. Histologically it seemed a fibrosarcoma. Mitotic figures and large atypical nuclei are noted. Hematoxylin and eosin stain. X 400. W.U. 54-3313; A F I P. Acc. No. 218757–213.

Figure 235. Higher power microscopic view of another field from the tumor. The patient died of pulmonary metastases seven months after disarticulation. Hematoxylin and eosin stain. X 660. B.H. 50–322; A. F. I. P. Acc. No. 218757–214.

Figure 236. Osteoid formation in a giant cell tumor of bone is illustrated in this photomicrograph. Hematoxylin and eosin stain. X 400. W.U. 54-3319; A. F. I. P. Acc. No. 218757–222.

Fig. 234

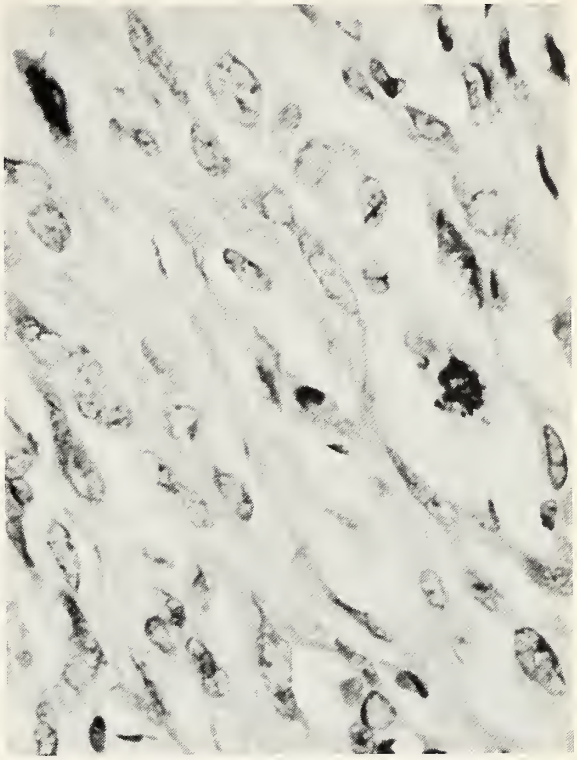

Fig. 235

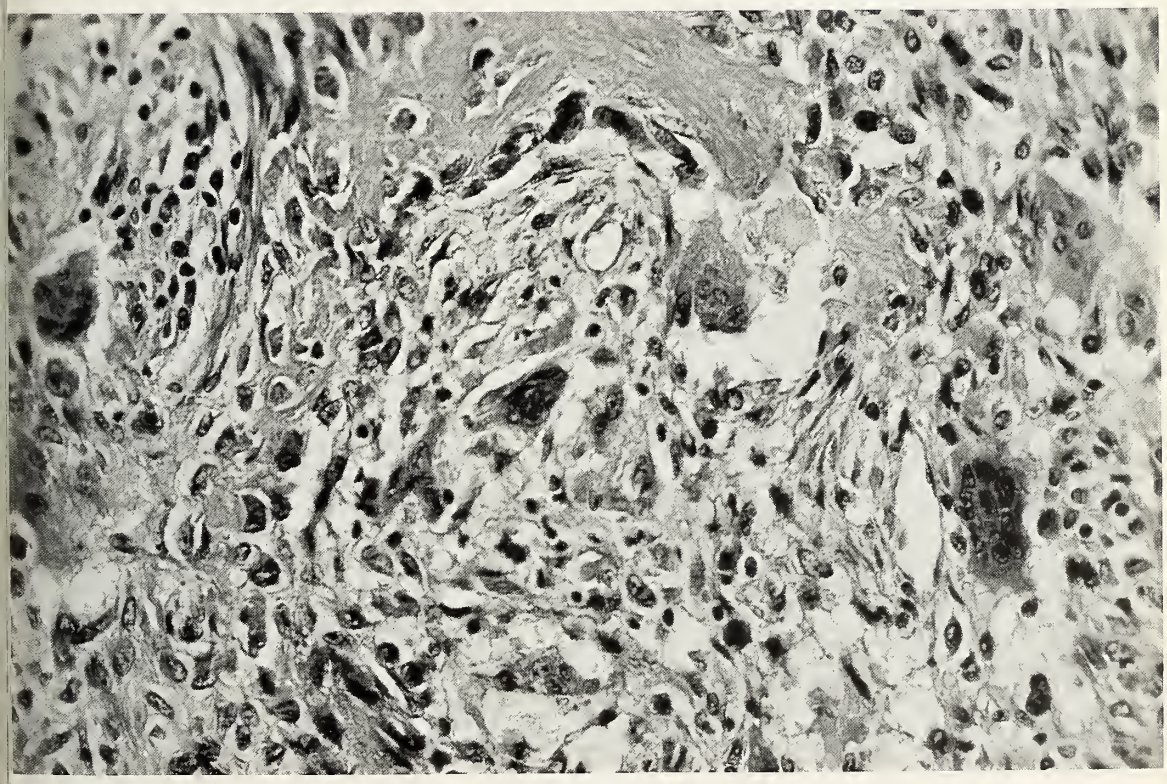

Fig. 236

GIANT CELL TUMOR

(Figures 237–239 are from the same case*)

Figure 237. Giant cell tumor of the proximal portion of a fibula of a 30-year-old woman. The roentgenogram illustrates the expanding and cystic character of the lesion. W.U. 58–3579; A. F. I. P. Acc. No. 218757–215.

Figure 238. Lateral view shows extension of the tumor into soft tissue. A. F. I. P. Acc. No. 218757–216.

Figure 239. Histologic sections showed a giant cell tumor of intermediate differentiation, few mitotic figures, and a tumor thrombus in a vein adjacent to this lesion. This tumor recurred in the soft tissues 16 months later. There were no pulmonary metastases. Hematoxylin and eosin stain. X 150. W.U. 58–3092; A. F. I .P. Acc. No. 218757–217.

---

*Courtesy of Dr. I. H. Nelson, Tulsa, Okla.

Fig. 237

Fig. 238

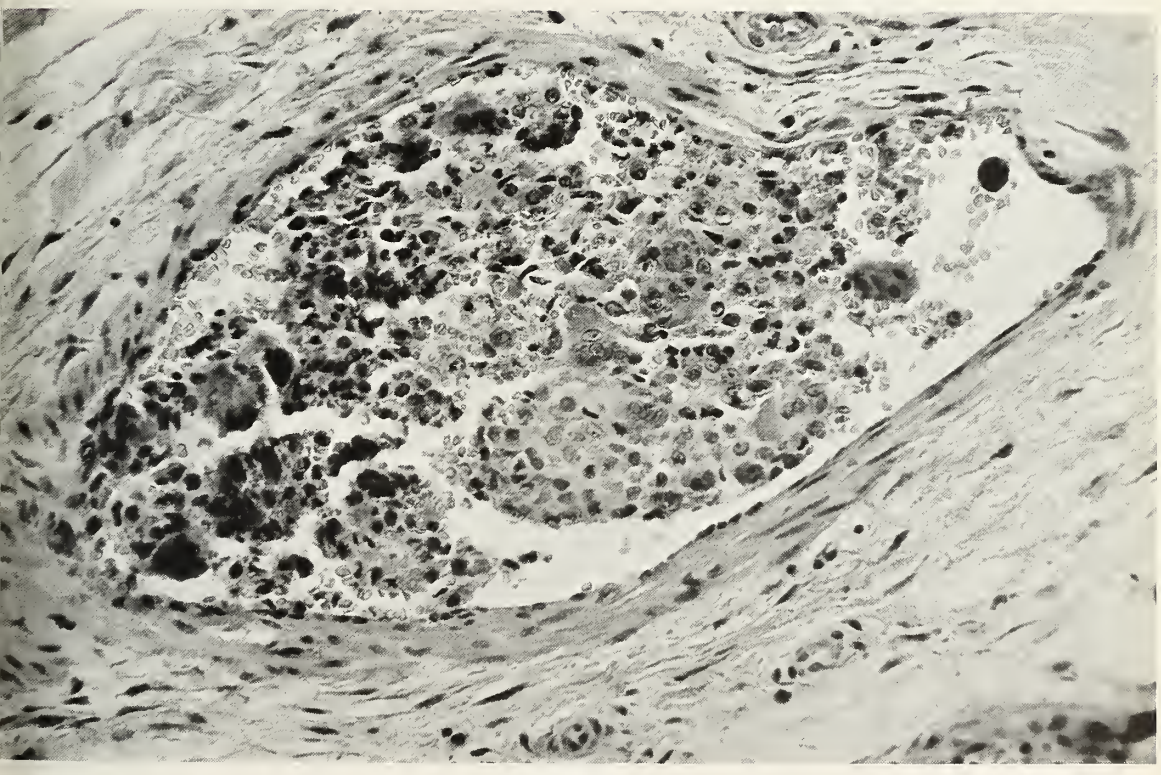

Fig. 239

GIANT CELL TUMOR

Figure 240. This photomicrograph shows the relationship of a giant cell tumor to cortical bone. Where tumor has eroded the bone, soft tissue forms the boundary of the tumor. Hematoxylin and eosin stain. X 165. B.H. 55–3550; A. F. I. P. Acc. No. 218757–223.

Figure 241. This section represents a metastatic carcinoma of the thyroid and serves to illustrate the similarity between the histologic patterns of some carcinomas of the thyroid and giant cell tumors of bone. Hematoxylin and eosin stain. X 400. W.U. 54–3318; A. F. I. P. Acc. No. 218757–224.

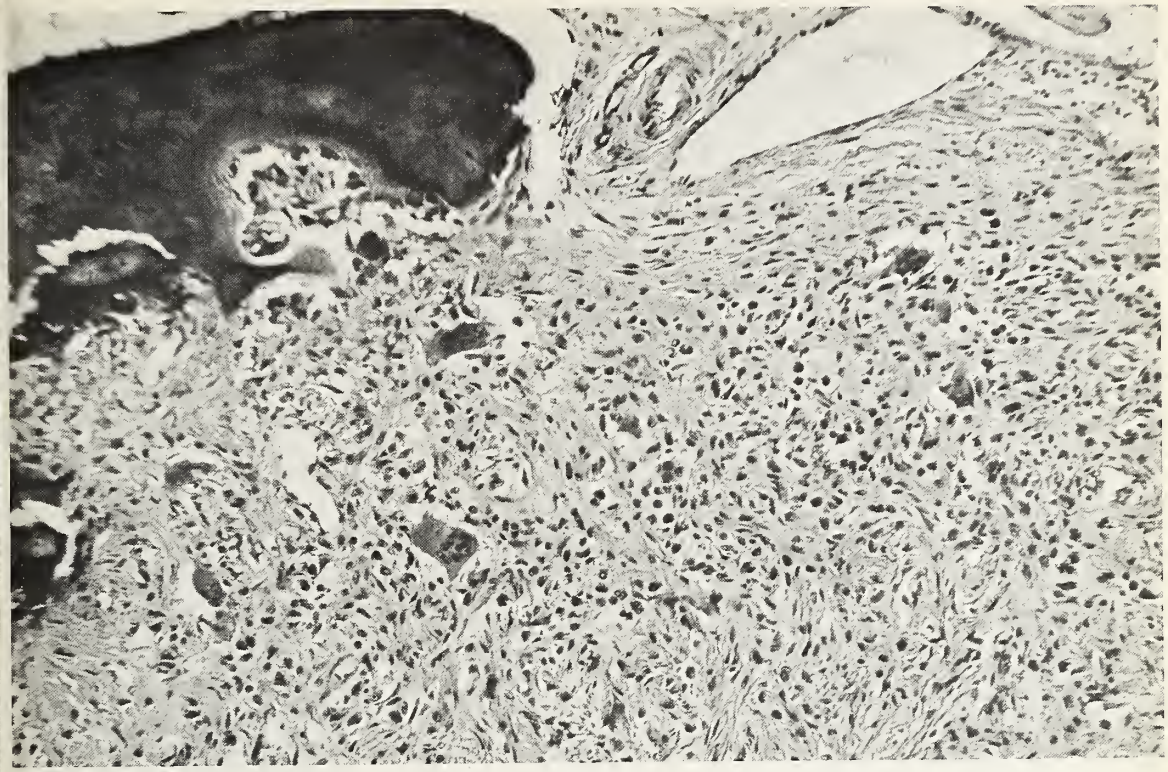

Fig. 240

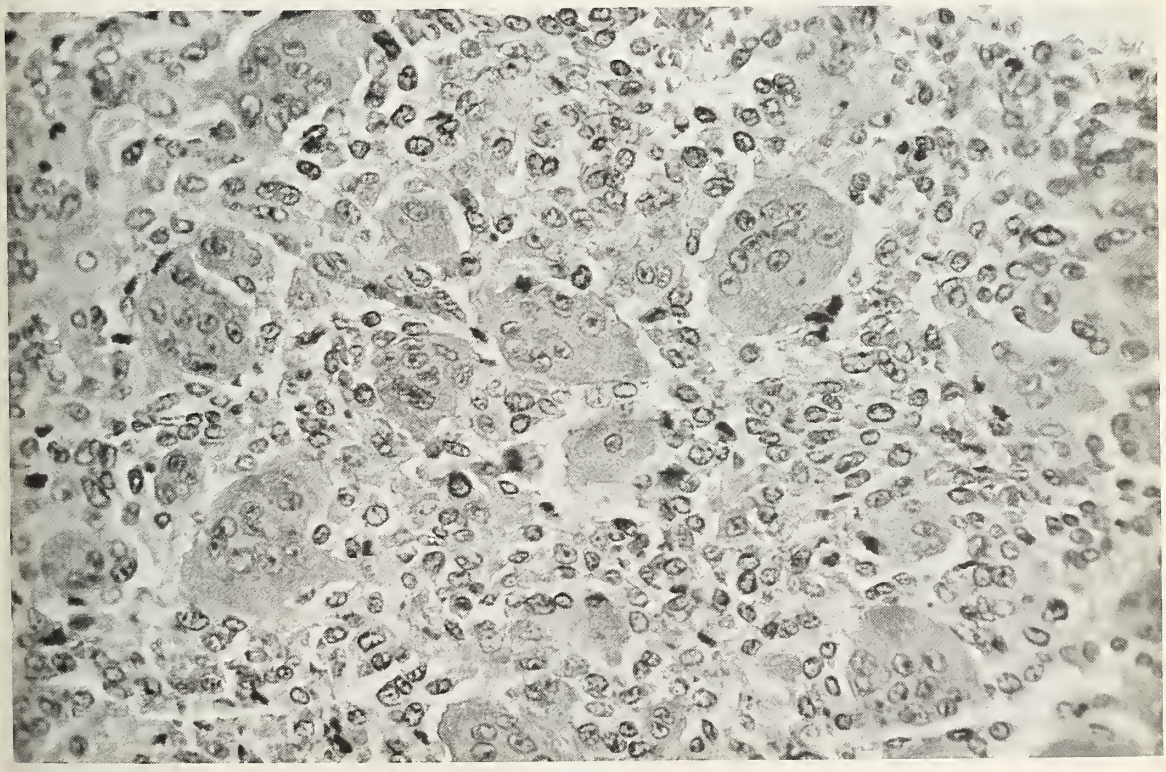

Fig. 241

Jaffe, H. L. Tumors and Tumorous Conditions of the Bones and Joints. Desmoplastic Fibroma and Fibrosarcoma, pp. 298–313. Philadelphia: Lea & Febiger, 1958.

_____, Lichtenstein, L., and Portis, R. B. Giant cell tumor of bone. Its pathologic appearance, grading, supposed variants and treatment. Arch. Path., 30:993–1031, 1940.

Johnson, E. W., Jr., and Dahlin, D. C. Treatment of giant-cell tumor of bone. J. Bone & Joint Surg., 41–A:895–904, 1959.

King, E. S. J. Malignant giant-cell tumour of bone. Brit. J. Surg., 20:269–278, 1932.

Lichtenstein, L. Giant-cell tumor of bone. Current status of problems in diagnosis and treatment. J. Bone & Joint Surg., 33–A:143–150, 1951.

_____. Tumors of periosteal origin. Cancer, 8:1060–1069, 1955.

_____. Bone Tumors. Fibrosarcoma of Bone, pp. 215–226. St. Louis: C. V. Mosby Co., 1959.

Macdonald, I., and Budd, J. W. Osteogenic sarcoma. I. A modified nomenclature and a review of 118 five year cures. Surg., Gynec. & Obst., 77:413–421, 1943.

McLeod, J. J., Dahlin, D. C., and Ivins, J. C. Fibrosarcoma of bone. Am. J. Surg., 94:431–437, 1957.

Meyerding, H. W. Treatment of benign giant-cell tumors by resection or excision and bone grafting. J. Bone & Joint Surg., 27:196–207, 1945.

Morton, J. J. Giant-cell tumor of bone. Cancer, 9:1012–1026, 1956.

Murphy, W. R., and Ackerman, L. V. Benign and malignant giant-cell tumors of bone. A clinical-pathological evaluation of thirty-one cases. Cancer, 9:317–339, 1956.

Pepler, W. J. Histogenesis of osteoclastomata. Nature, 181:633, 1958.

Prossor, T. M. Treatment of giant-cell tumours of bone. With a review of twenty-five cases. J. Bone & Joint Surg., 31–B:241–251, 1949.

Russell, D. S. Malignant osteoclastoma. And the association of malignant osteoclastoma with Paget's osteitis deformans. J. Bone & Joint Surg., 31–B:281–290, 1949.

Schajowicz, F. Giant-cell tumors of bone (osteoclastoma). A pathological and histochemical study. J. Bone & Joint Surg., 43–A:1–29, 1961.

Steiner, P. E. Multiple diffuse fibrosarcoma of bone. Am J. Path., 20:877–893, 1944.

Stewart, F. W., Coley, B. L., and Farrow, J. H. Malignant giant cell tumor of bone. Am. J. Path., 14:515–535, 1938.

Stout, A. P. Fibrosarcoma. The malignant tumor of fibroblasts. Cancer, 1:30–63, 1948.

_____. Personal communication, 1961.

Whitesides, T. E., Jr., and Ackerman, L. V. Desmoplastic fibroma. A report of three cases. J. Bone & Joint Surg., 42–A:1143–1155, 1960.

Williams, R. R., Dahlin, D. C., and Ghormley, R. K. Giant-cell tumor of bone. Cancer, 7:764–773, 1954.

Windeyer, B. W., and Woodyatt, P. B. Osteoclastoma. A study of thirty-eight cases. J. Bone & Joint Surg., 31–B:252–267, 1949.

A

FIBROSARCOMA

(Plate III and figures 207 and 208 are from the same case)

A. Hemisection of a fibrosarcoma from the proximal end of the left tibia of a 27-year-old woman. Previous history was of trauma, with subsequent swelling of the knee. Characteristic discrete delineation of the tumor by scalloped margins, destruction of cortex, and confinement by periosteum are seen. A. F. I. P. Acc. No. 218757–378.

A

PERIOSTEAL SARCOMA

(Plate IV and figures 213–216 are from the same case)

A. Hemisection of recurrent periosteal sarcoma from a 24-year-old woman. Tumor was attached to the proximal portion of a femur. Roentgenographic examination revealed periosteal bone formation without cortical destruction. Amputation was done because of rapid reappearance and large size of the tumor. A mass excised from this area six months previously had been incorrectly interpreted as a desmoid. (Courtesy of Dr. D. O. Burst, St. Louis, Mo.) A. F. I. P. Acc. No. 218757–379.

TUMORS OF VASCULAR ORIGIN—PRIMARY BENIGN AND MALIGNANT

Hemangioma

SYNONYMS AND RELATED TERMS: Angioma; hemangioendothelioma.

DEFINITION. A rare lesion of bone composed of large, blood-filled vascular channels, occasionally in combination with lymphatic channels.

INCIDENCE. Hemangioma of bone represented less than 1 percent of all bone tumors seen at the Mayo Clinic (Dahlin); capillary hemangiomas of bone, though also rare, have been reported (Sherman). There is no sex predilection. Lesions occur at all ages; some authors have stated that highest incidence is in young adults, with fewer lesions in childhood and elderly persons. This is in contrast to the clinically insignificant lesions discovered by Töpfer in which his patients were predominantly above the age of 60.

CLINICAL DATA. Lesions of long bones may be discovered because of swelling, pain, or pathologic fractures.

The case history of a patient observed for 10 years with multiple hemangiomas of the skeleton has been delineated in part by Ackerman and Hart. The hemangiomas were in the proximal and distal portions of the tibia, fibula, tarsals, and metatarsals. Roentgenogram revealed characteristic multicystic uniform expansion of bone. Cysts were distinct, and the cortex was intact but thin. Within the 10-year period, the lesions became denser, particularly centrally; locules became smaller but were still present. The lesions did not disappear completely except for that of the fibula, in which the bone was said to have become reconstituted. The lesions reossified centrally, but the reconstituted bone appeared to be structurally different from normal bone.

Roentgenographically this lesion, demonstrated by Ackerman and Hart as lytic, can be outlined as sclerotic in its center with a more radiolucent area peripherally. Cortex over the hemangioma may be greatly thinned, show irregular destruction, and be accompanied by moderate periosteal bone proliferation. In the skull, full thickness of the bone may be entirely destroyed (figs. 247, 248); although the periosteum remains intact, there is subperiosteal bone formation which gives an impression of radiating spicules of bone likened to a "sunburst."

PATHOGENESIS. Since it is difficult to determine whether a hemangioma is a true neoplasm or a malformation, Jacobs and Kimmelstiel have suggested that cavernous hemangiomas should be designated as angiohamartoma.

Rare primary malignant vascular tumors have been designated as hemangioendothelioma or as angiosarcoma.

SITES OF TUMOR. In over 2,000 vertebral columns examined at autopsy, Töpfer found 257 hemangiomas (approximately 12 percent); he also found 9 hemangiomas in the sternum, 3 in the skull, and 2 in the proximal femur. All ages were represented in this study, the majority of patients being 60 years of age and over; all lesions were clinically insignificant. One third of the hemangiomas in this series were multiple; multiple bone involvement, in fact, previously has been reported as cystic angiomatosis (Jacobs and Kimmelstiel) and hemangiomatosis of the skeleton (Ritchie and Zeier).

Relatively frequent occurrence of hemangiomas of bone in the vertebral column, therefore, has been well demonstrated by Töpfer. In patients with hemangioma of the vertebral bodies, involvement of the spinal canal with compression of the cord has been described (Perman).

While we have seen only single hemangiomas of the humerus, clavicle, rib, and fibula (Goidanich and Venturi; figs. 242, 245), a single bone may have multiple foci of involvement (fig. 246). Hemangiomas of viscera, particularly spleen and liver, may be associated with hemangiomas of bone.

GROSS. Fairbank has observed that a hemangioma occasionally may become sufficiently erosive to involve adjacent bones. It has also been noted that in long bones the hemangioma has a tendency to begin erosion in the cortex, with little or no involvement of the medulla. When involved by hemangiomas (fig. 244), bones often show expansion, even long bones; the shape of vertebral bodies, however, is well maintained.

MICROSCOPIC. The rare capillary hemangiomas reported have a histologic pattern similar to that of capillary hemangiomas of skin (fig. 243). A case reported by Sherman occurred in a 2-year-old child and involved the distal femur; the lesion was destructive and had been diagnosed clinically as osteomyelitis.

TREATMENT. This varies; there has been evidence to support use of radiation therapy as a means of controlling the lesion. If possible, surgical extirpation may be done.

PROGNOSIS. Since these tumors do not become malignant, prognosis is excellent.

ASSOCIATED LESIONS. **Glomus tumors** of the skin, particularly of fingers and extremities, are common lesions, but occurrence of a glomus tumor apparently arising in bone is rare. One such case has been reported in the literature by Lattes and Bull. The lesion occurred in a distal phalanx of the thumb of a 28-year-old woman. Histologically it had the characteristics of a glomus tumor.

Hemangiomas of joints are also rare entities which may diffusely involve entire joint cavities. A few cases have been reported which predominantly involved the knee; usually these lesions are confined to the synovial or capsular membrane. The patients range in age from 4 to 28 years. Histologically the lesions are cavernous hemangiomas, although an occasional pedunculated

hemangioma has occurred. Radiation therapy seems to give satisfactory results in controlling the disease.

The rare unusual **Maffucci's syndrome** is a combination of hemangiomas and is associated with dyschondroplasia. Most often the hemangiomas appear on the skin; only rarely are bones or joints involved. Sarcomas, presumably osteosarcoma and chondrosarcoma, may develop in patients afflicted with this disease.

Massive osteolysis, occasionally also called "phantom bone" or "disappearing bone," is another rare syndrome of bone related to hemangioma. This unusual progressive and distressing disease is an actual dissolution of bone with replacement by fibrous tissue. More than 30 cases of this disease process have been reported in the literature (Gorham and Stout; Johnson and McClure).

The disease usually occurs in childhood; as the patient ages, the process tends to stabilize. In mild cases only parts of a bone may be absorbed; in severe cases an entire bone such as the mandible, or parts of more than one bone, may be absorbed and disappear. Roentgenographic progression of the disease over a period of about two and one-half years has been illustrated by Johnson and McClure. From the chart presented in the paper of Gorham and Stout it would seem that the lesion has a tendency to unilateral distribution.

Lymphangioma

DEFINITION. A rare lesion with histologic features similar to those of lymphangiomas in soft tissues or skin.

INCIDENCE. Harris and Prandoni reported the case of a 20-year-old white man who had primary lymphangiomas involving the skull, vertebra, humerus, scapula, rib, pelvic bones, femur, and tibia. Biopsy of the rib had proved that the lesions were lymphangiomas. Cohen and Craig described a similar case occurring in a 3-year-old child. Falkmer and Tilling later reported a lymphangioma involving transverse processes of L3, 5 vertebrae. Surgical exploration proved these lesions unusual in that there was little or no hemorrhage from them; neither were there surrounding soft tissue tumors. Photomicrographs of the lesions were histologically compatible with lymphangioma.

Lymphangiomas involving bone secondarily to an adjacent soft tissue lesion also have been reported (Wrede; Bickel and Broders). Although the latter authors also reported their case as primary lymphangioma of the ilium, biopsies showed soft tissues but no bone. In this case, too, there was progressive dissolution of the ilium, ischium, and parts of the vertebrae, so that the lesion probably bore relationship to the entity of massive osteolysis.

PATHOGENESIS. Whether lymphangioma is a true neoplasm or represents a hamartoma as suggested in the preceding section on hemangioma, we are unable to determine. However, since it has been stated that lymphatic channels are not present in the marrow spaces of bone but that a rich lymphatic

plexus is present in the periosteum accompanying nutrient vessels to the bone, perhaps lymphangiomas or lymphangiectases could arise from these channels. If arising in the periosteum, it would be reasonable to assume that lymphangiomas in bone had eroded from the periosteal surface (fig. 249).

Angiosarcoma

SYNONYMS AND RELATED TERMS: Angioblastoma; angioendothelioma; hemangioendothelioma; hemangiosarcoma; malignant hemangioma.

DEFINITION. A rare malignant tumor apparently having its origin in the vasculature or precursive cells of vessels of bone, although malignant transformation of hemangiomas per se has not been demonstrated.

INCIDENCE. Ages of patients have ranged from three months to 60 years or more. There is no predilection for either sex.

SITES OF TUMOR. Although the lesion is rare, it may involve multiple bones or multiple sites in a single bone. Most bones of the body have been involved by it on occasion, e.g. temporal bone, maxilla, clavicle, scapula, ribs, radius, carpals, metacarpal, ilium, femur, tibia, fibula, tarsal and metatarsals.

GROSS. Examination of resected specimens and roentgenographic studies (fig. 250) show angiosarcomas as destructive lesions. They are hemorrhagic and friable, or sometimes rubbery in consistency (figs. 251, 255). The cortex may be eroded to allow penetration of the tumor into surrounding soft tissues. In fixed specimens, hemorrhagic portions of the lesion may have the appearance of blood clots.

MICROSCOPIC. The basic pattern is that of new blood vessel formation and endothelial proliferation. Endothelial cells are a prominent feature of the tumor, and formative cells have malignant characteristics (figs. 252–254). In many areas there seems to be budding of formative cells, giving the tumor a papillary appearance. Other areas may be quite solid and suggest a synovial sarcoma, with which these lesions have sometimes been confused.

TREATMENT. This varies and may include local excision, amputation, irradiation, or a combination of radiation therapy and excision.

PROGNOSIS. This disease often has fatal termination. In a group of cases collected by Carter and associates, 7 of the 15 patients on whom there was follow-up had died; only 2 patients were known to be alive longer than five years.

In 6 cases of angioendotheliomas reported by Thomas, 5 patients had died and 1 patient had survived 10 years.

METASTASES. Lymph nodes and viscera may be involved.

DIFFERENTIAL DIAGNOSIS. We believe that angiosarcoma and hemangioendothelioma are similar lesions and not necessarily histologically and clinically distinctive. However, Thomas distinguishes these lesions histologically in that vascular proliferation with new blood vessel formation provides the basic pattern for angiosarcoma; he feels that hemangioendothelioma is char-

acterized by an epithelium-like structure that is the result of endothelial proliferation. The latter is occasionally difficult to distinguish from carcinoma metastatic to bone, such as renal cell carcinoma.

References

Abbott, W. B. Angioma of the skull. Ann. Surg., 113:306–311, 1941.

Ackerman, A. J., and Hart, M. S. Multiple primary hemangioma of the bones of the extremity. Am. J. Roentgenol., 48:47–52, 1942.

Bean, W. B. Dyschondroplasia and hemangiomata (Maffucci's syndrome). Arch. Int. Med., 95: 767–778, 1955; 102:544–550, 1958.

Bennett, G. E., and Cobey, M. C. Hemangioma of joints. Report of five cases. Arch. Surg., 38:487–500, 1939.

Bickel, W. H., and Broders, A. C. Primary lymphangioma of the ilium. Report of a case. J. Bone & Joint Surg., 29:517–522, 1947.

Bucy, P. C., and Capp, C. S. Primary hemangioma of bone with special reference to roentgenologic diagnosis. Am. J. Roentgenol., 23:1–33, 1930.

Carter, J. H., Dickerson, R., and Needy, C. Angiosarcoma of bone: a review of the literature and presentation of a case. Ann. Surg., 144:107–117, 1956.

Castleman, B., and Kibbee, B. U. Case 43521. Presentation of case. New England J. Med., 257: 1283–1287, 1957.

Cobey, M. C. Hemangioma of joints. Arch. Surg., 46:465–468, 1943.

Cohen, J., and Craig, J. M. Multiple lymphangiectases of bone. J. Bone & Joint Surg., 37–A: 585–596, 1955.

Dahlin, D. C. Bone Tumors. Hemangioma. Hemangioendothelioma and Hemangiopericytoma, pp. 84–89. Springfield, Ill.: Charles C Thomas, 1957.

Fairbank, T. Haemangioma of bone. Practitioner, Lond., 177:707–711, 1956.

Falkmer, S., and Tilling, G. Primary lymphangioma of bone. Acta orthop. scand., 26:99–110, 1956.

Geschickter, C. F., and Maseritz, I. H. Primary hemangioma involving bones of the extremities. J. Bone & Joint Surg., 20:888–900, 1938.

Goidanich, I. F., and Venturi, R. Emangioma cavernoso della tibia. Chir. org. movim., 43:295–313, 1956.

Gorham, L. W., and Stout, A. P. Massive osteolysis (acute spontaneous absorption of bone, phantom bone, disappearing bone). Its relation to hemangiomatosis. J. Bone & Joint Surg., 37–A:985–1004, 1955.

Gramiak, R., Ruiz, G., and Campeti, F. L. Cystic angiomatosis of bone. Radiology, 69:347–353, 1957.

Hadders, H. N., and Oterdoom, H. J. The identification of aneurysmal bone cyst with haemangioma of the skeleton. J. Path. & Bact., 71:193–200, 1956.

———, and Rinsma, S. G. Capillary haemangioma of the fibula giving rise to severe clinical manifestations. Arch. chir. neerl., 7:257–264, 1955.

Hambach, R., Pujman, J., and Maly, V. Massive osteolysis due to hemangiomatosis. Report of a case of Gorham's disease with autopsy. Radiology, 71: 43–47, 1958.

Harris, R., and Prandoni, A. G. Generalized primary lymphangiomas of bone: report of a case associated with congenital lymphedema of forearm. Ann. Int. Med., 33:1302–1313, 1950.

Herzog, G. Hämangiome der Wirbelsäule. In: Henke, F., and Lubarsch, O. (eds.). Handbuch der speziellen pathologischen Anatomie und Histologie, pp. 56–61. Vol. IX, pt. 5. Berlin: Julius Springer, 1944.

Jacobs, J. E., and Kimmelstiel, P. Cystic angiomatosis of the skeletal system. J. Bone & Joint Surg., 35–A:409–420, 1953.

HEMANGIOMA

(Figures 242 and 243 are from the same case*)

Figure 242. Roentgenogram of a cavernous hemangioma of the fibula in a 52-year-old woman who had experienced local pain in the area for three years. On this evidence of bone destruction, the lesion radiographically was interpreted as malignant, possibly a Ewing's tumor. A. F. I. P. Acc. No. 218757–245.

Figure 243. Histologic section of this tumor shows delicate vessels filled with blood. Hematoxylin and eosin stain. X 160. A. F. I. P. Acc. No. 218757–19.

Figure 244. Photograph of a gross specimen of a capillary hemangioma of the fibula. This tumor had produced marked bone destruction and secondary periosteal proliferation. (This is figure 15 in Hadders, H. N., and Oterdoom, H. J. The identification of aneurysmal bone cyst with haemangioma of the skeleton. J. Path. & Bact., 71:193–200, 1956.) A. F. I. P. Acc. No. 218757–246.

Figure 245. Roentgenogram of a hemangioma of a humerus of an 8-year-old boy. This shows central sclerosis with radiating spicules of bone, expansion of bone, and focal destruction of cortex, which are characteristics of the lesion. After confirmatory biopsy, the tumor was treated by four surgical procedures which entailed curettage and fibular bone graft. Roentgenotherapy followed, and four years after the last treatment the bone appeared almost normal. (Courtesy of Dr. R. W. Byrne, Milwaukee, Wis.) A. F. I. P. Acc. No. 218757–362.

---

*Courtesy of Dr. D. C. Dahlin, Rochester, Minn.

Fig. 242

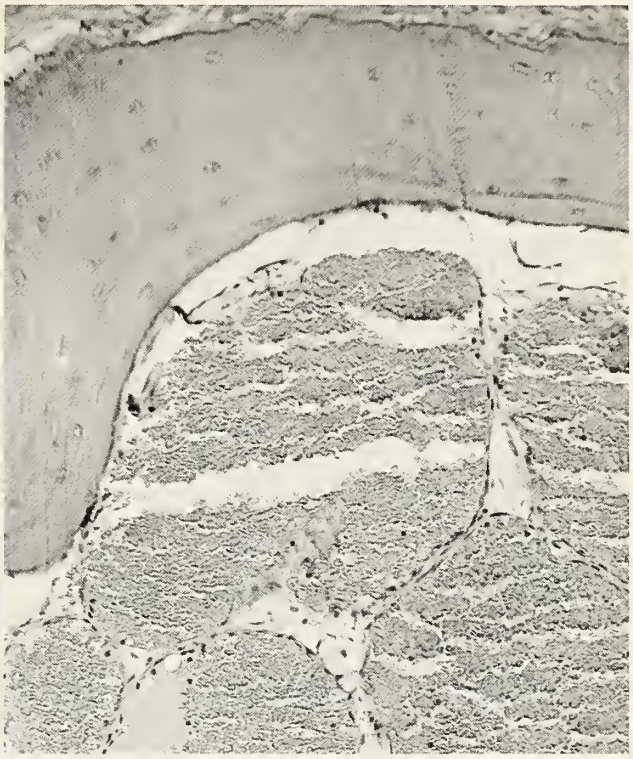

Fig. 243

Fig. 244

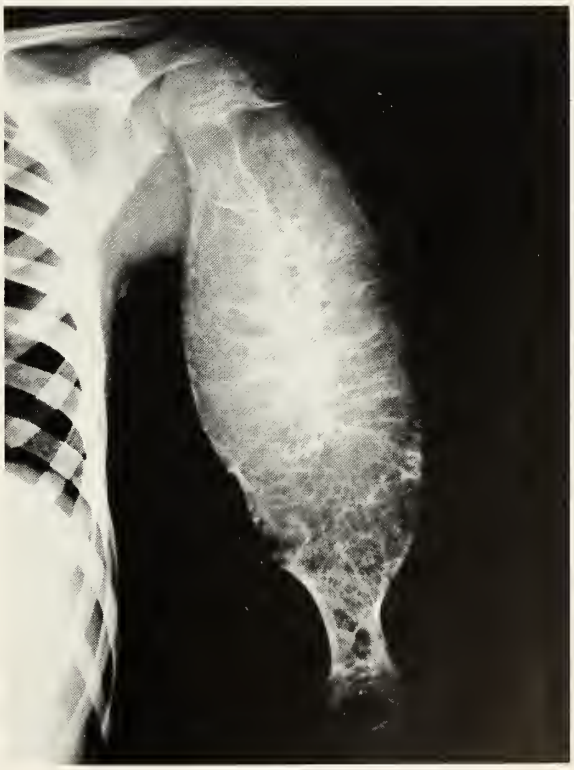

Fig. 245

HEMANGIOMA

(Figures 247 and 248 are from the same case*)

Figure 246. Lateral and antero-posterior roentgenograms of a radius and ulna of an 11-year-old Negro boy show cystic areas in both bones. There were also cystic lesions of all other long bones, ribs, scapulae, and pelvis. When the illustrated lesion of the ulna was biopsied, the surgeon encountered a blood-filled cavity. Histologic studies of the curettings demonstrated an angiomatous lesion. Since the age of eight years, the patient had fractured both humeri twice and the right clavicle and right forearm once. (Courtesy of Dr. E. E. Palik, Tulsa, Okla.) W.U. 61–842; A. F. I. P. Acc. No. 218757–397.

Figure 247. Sagittal section of an asymptomatic hemangioma of the frontal bone of a 73-year-old woman. A. F. I. P. Acc. No. 218757–363.

Figure 248. The macerated specimen of the lesion seen in figure 247 demonstrated a trabecular jungle corresponding to these radiographic reticular and sunburst patterns. A. F. I. P. Acc. No. 218757–391.

LYMPHANGIOMA

Figure 249.* The photomicrograph shows the delicate lymphatic channels composing a lymphangioma of a frontal bone in a 3½-year-old child. Hematoxylin and eosin stain. X 100. A. F. I. P. Acc. No. 218757–364.

---

*Courtesy of Dr. E. Uehlinger, Zurich, Switzerland.

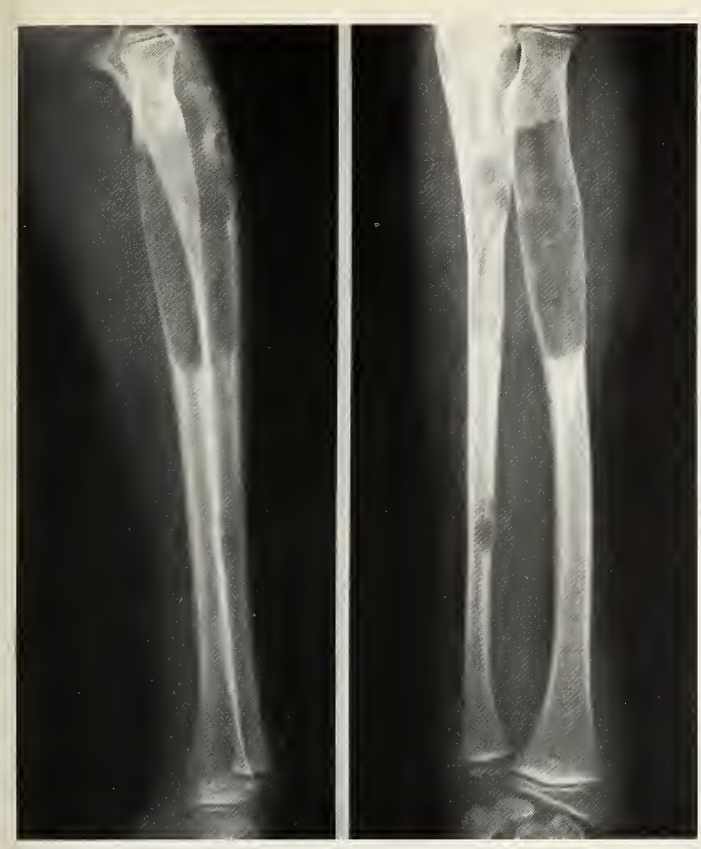

Fig. 246

Fig. 247

Fig. 248

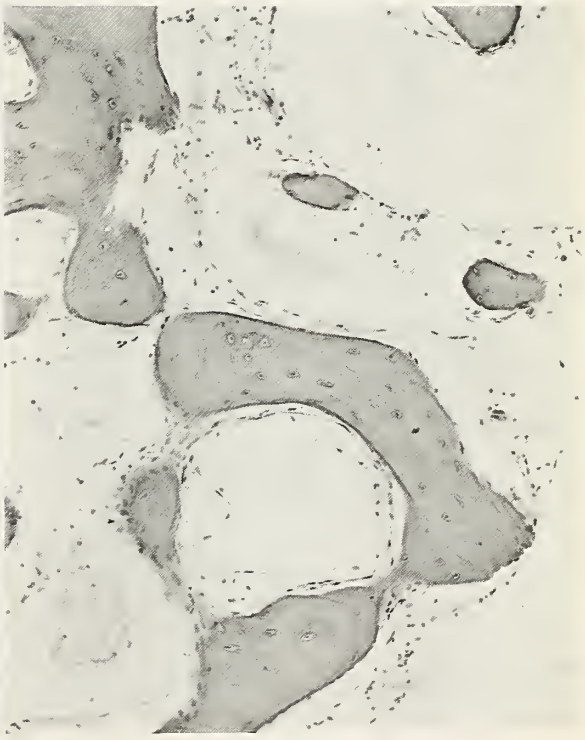

Fig. 249

ANGIOSARCOMA

(Figures 250–254 are from the same case)

Figure 250.* Radiograph of an angiosarcoma of a tibia and fibula of a 74-year-old woman. Multiple sites of tumor are evident. A. F. I. P. Acc. No. 218757–365.

Figure 251.* This section through the amputation specimen of the tumor demonstrates multiple hemorrhagic tumor foci. A. F. I. P. Acc. No. 218757–366.

Figure 252.* The photomicrographic field shows malignant proliferative cells forming blood vessels and tufts that appear to be endothelial. Hematoxylin and eosin stain. X 350. W.U. 58–4151; A. F. I. P. Acc. No. 218757–248.

---

*Courtesy of Dr. J. H. Carter, Albany, N.Y., and Dr. Marvin Kuschner, New York, N.Y.

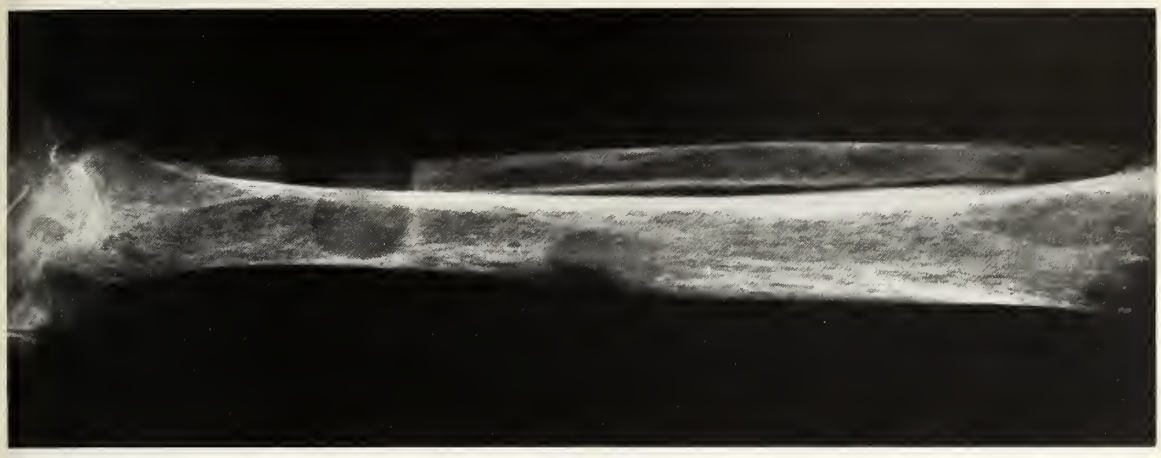

Fig. 250

Fig. 251

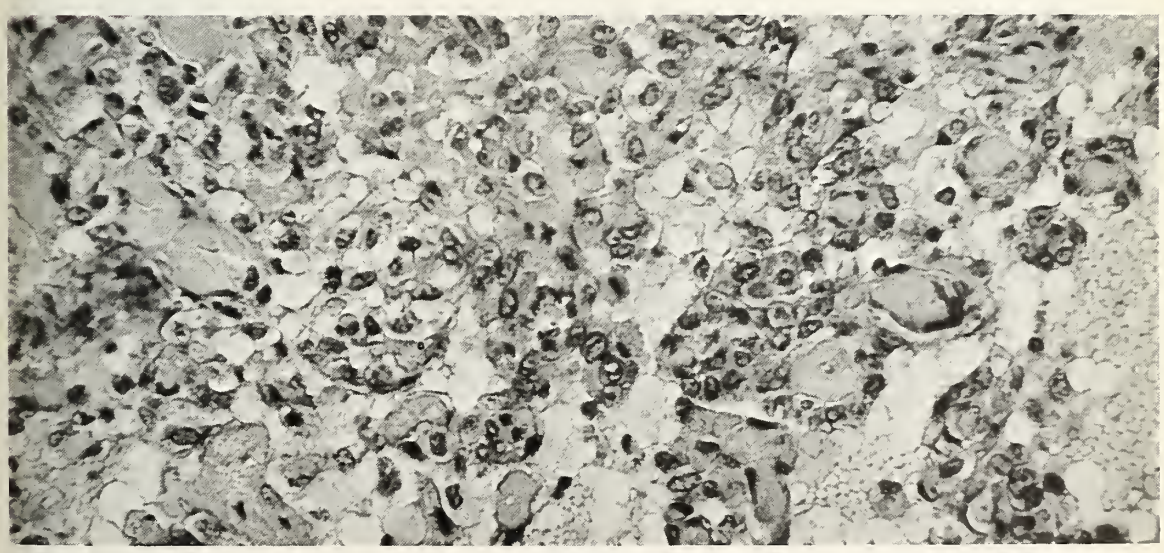

Fig. 252

ANGIOSARCOMA

(Figures 250–254 are from the same case)

Figure 253.* Note hyalinization of the tufts in this photomicrograph. Hematoxylin and eosin stain. X 350. W.U. 58-4150; A. F. I. P. Acc. No. 218757-249.

Figure 254.* Surviving bone is shown in relation to the angiosarcoma. In the study of many other microsections, bone formation was not a feature of the tumor. Hematoxylin and eosin stain. X 275. W.U. 58-3895; A. F. I. P. Acc. No. 218757-250.

Figure 255. Hemisection of an angiosarcoma of thoracic vertebrae 4, 5, and 6 of a 56-year-old woman. Its bloody, destructive, and expansile nature are evident. Histologically this is an angiosarcoma and not an aneurysmal bone cyst or hemangioma. (Courtesy of Dr. E. Uehlinger, Zurich, Switzerland.) A. F. I. P. Acc. No. 218757-367.

---

*Courtesy of Dr. J. H. Carter, Albany, N.Y., and Dr. Marvin Kuschner, New York, N.Y.

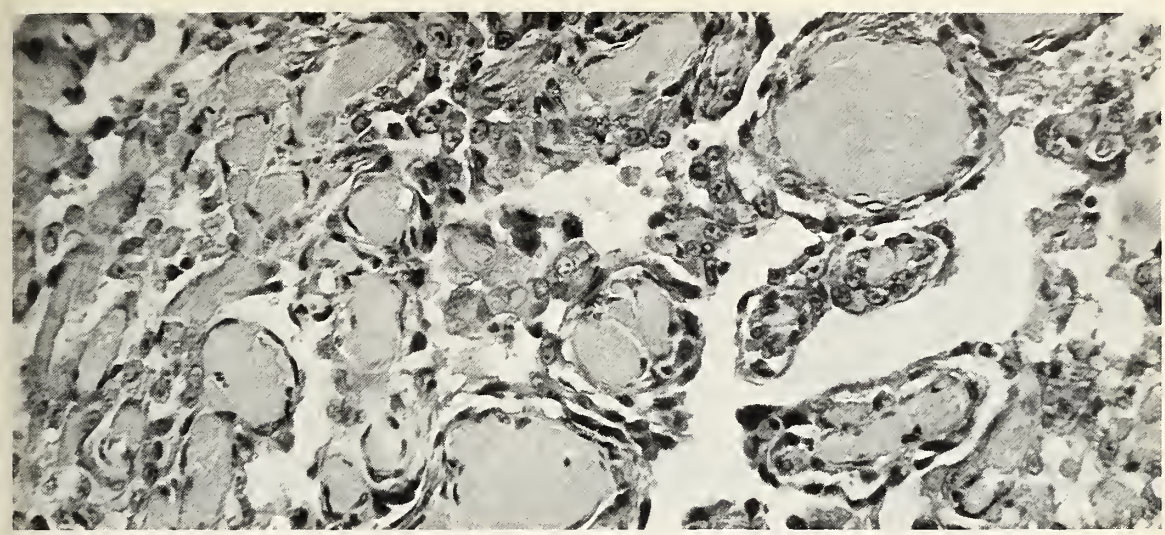

Fig. 253

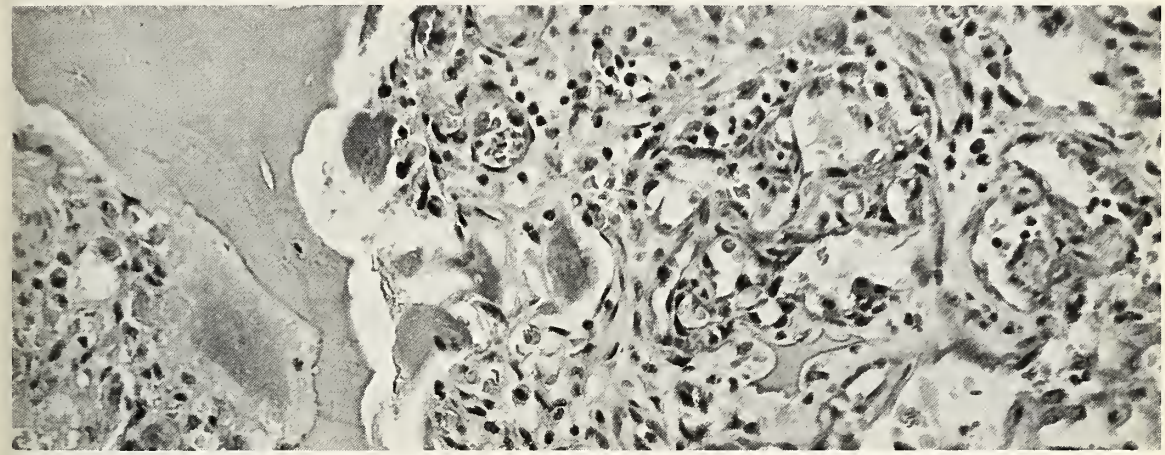

Fig. 254

Fig. 255

Jaffe, H. L. Tumors and Tumorous Conditions of the Bones and Joints. Malignant Vascular Tumors, pp. 341–349. Philadelphia: Lea & Febiger, 1958.

Johnson, P. M., and McClure, J. G. Observations on massive osteolysis. A review of the literature and report of a case. Radiology, 71:28–42, 1958.

Lattes, R., and Bull, D. C. A case of glomus tumor with primary involvement of bone. Ann. Surg., 127:187–191, 1948.

Lichtenstein, L. Bone Tumors. Tumors of Bone of Vascular Origin: Hemangioma, Hemangio-endothelioma, Hemangiopericytoma (Glomus), pp. 146–157. St. Louis: C. V. Mosby Co., 1959.

Perman, E. On haemangiomata in the spinal column. Acta chir. Scandinav., 61:91–105, 1926.

Ritchie, G., and Zeier, F. G. Hemangiomatosis of the skeleton and the spleen. J. Bone & Joint Surg., 38:115–122, 1956.

Selakovich, W. G., and Sherman, M. S. Hemangiomas of the musculoskeletal system. Ochsner Clin. Rep., 2:41–54, 1956.

Sherman, M. S. Capillary hemangioma of bone. Arch. Path., 38:158–161, 1944.

Stout, A. P. Hemangio-endothelioma: a tumor of blood vessels featuring vascular endothelial cells. Ann. Surg., 118:445–464, 1943.

Thomas, A. Vascular tumors of bone. A pathological and clinical study of twenty-seven cases. Surg., Gynec. & Obst., 74:777–795, 1942.

Töpfer, D. I. Über ein infiltrierend wachsendes Hämangiom der Haut und multiple Kapillarektasien der Haut und inneren Organe. II. Zur Kenntnis der Wirbelangiome. Frankf. Zschr. Path., 36:337–345, 1928.

Trommer, B. Zur lehre der Hämangiome der Wirbelsäule. (Kavernöses Chondrom des funften Brustwirbels mit Kompressionsmyelitis). Frankf. Zschr. Path., 22:313–326, 1919–20.

Wrede, L. Ueber Lymphangiome im Knochen. Beitr. klin. Chir., 73:213–225, 1911.

TUMORS OF NEUROGENOUS ORIGIN—PRIMARY BENIGN AND MALIGNANT

Neurilemoma

SYNONYMS AND RELATED TERMS: Benign nerve sheath tumor; encapsulated neurofibroma; schwannoma.

DEFINITION. A benign neoplasm arising from the nerve sheath and appearing within the substance of bone.

CLINICAL DATA. This has been summarized in table III.

PATHOGENESIS. These tumors arise from sheaths of nerves entering bone, usually accompanying the nutrient artery.

SITES OF TUMOR. Lesions have been reported in the mandible, humerus, ulna, metacarpal, sacrum, and femur (see table III).

GROSS. Material from curettement is grayish yellow or hemorrhagic. Within the bone, neurilemomas form a sharply delineated mass; we presume that if they could be removed en masse they would show a well defined capsule (fig. 256).

MICROSCOPIC. Antoni type A tissue (figs. 257, 259) shows palisading and characteristics of Verocay bodies; Antoni type B tissue (fig. 258) contains zones of cystic degeneration. Frequently there are thick-walled blood vessels.

TREATMENT. Curettage and replacement with bone chips are usually effective.

PROGNOSIS. Excellent prognosis prevails.

Neurofibromatosis (von Recklinghausen)

Alterations of bone in this disease are fairly common, occurring in 7 to 29 percent of patients. Holt and Wright have classified these bone defects as erosion, scoliosis, disorders of growth, congenital bowing and pseudarthrosis of the lower leg, intraosseous cystic lesions, and congenital anomalies; scoliosis reportedly is the commonest of these. Defects may be caused by actual neurofibroma in the medullary cavity, as observed by Friedman, or by erosion from adjacent neurofibromatous lesions. Disproportionate growth is not necessarily explained only on the basis of neurofibromatous involvement of bones of the extremity, but also may be associated with hypertrophy of the surrounding soft tissues. Occasionally, there may be actual diminution of the caliber and length of a bone rather than elongation of its longitudinal axis. Autopsy studies on patients who had had neurofibromatosis also have shown osteomalacia; however, bones affected by osteomalacia were not necessarily those with neurofibromatous involvement.

Table III

CLINICAL SUMMARIES OF PATIENTS WITH NEURILEMOMAS OF BONE

Author	Sex & Age	Duration & Symptoms	Site of Tumor	Radiograph	Pathology	Treatment	Subsequent History
Peers (1934)	M 55	1 yr.; swelling of right forearm	Midshaft of ulna (R)	In middle third of ulna, fusiform tumor pushing thin cortex of bone before it. Thin bony septae divide tissue into loculi	Whorl-like. Fibroblastic areas with palisading of nuclei	Amputation	Alive 20 mos. later
Gross, Bailey and Jacox (1939)	F 37	3 yrs.; painless mass over left upper arm	Midshaft of humerus (L)	Cystic area in midshaft	Soft, solid. Micro: typical neurilemoma	Local excision	.....
DeSanto and Burgess (1940)	M 37	8 yrs.; repeated fractures of left forearm	Midshaft of ulna (L)	Multilocular cystic change with thin shell of cortical bone	Soft, hemorrhagic. Micro: typical neurilemoma	Resection with bone graft	.....
Spilka (1953)	M 39	4 yrs.; intermittent pain in mandible	Body and ramus of mandible (R)	Cystic, rarefied lesion in body and ramus	Irregular fragments of red yellowish tissue. Micro: typical neurilemoma	Curettement	No recurrence after 18 mos.
Jones (1953)	F 34	4 yrs.; swelling of back and hand	4th metacarpal (L)	Cystic lesion	Typical neurilemoma	Curettement with bone graft	.....
Hart and Basom (1958)	M 45	Fracture	Proximal femur (R)	Cystic bone defect with fracture	Brownish red to yellow-gray. Micro: typical neurilemoma	Curettement	2 yrs. follow-up with healing
AFIP Acc. No. 82563	M 36	15 yrs.; trauma, subsequent painful nodule	Proximal fibula (L)	.....	Cystic, grayish, encapsulated. Micro: neurilemoma	Curettement	.....
Stout (1958)	..	.....	Mandible (2 cases), ulna, 4th metacarpal, and sacrum	.....	.....	.....	.....

Ganglioneuroma

A single case of ganglioneuroma of bone has been reported (Wilber and Woodcock). This occurred in a 22-year-old man. Radiolucent lesions were present in the proximal portions of the right ulna, radius, and humerus, in the 4th lumbar vertebra, and in the left tibia. The tibial and ulnar lesions were biopsied; histologic examination of the tissue revealed a tumor compatible with ganglioneuroma. After two years, follow-up data stated that the patient was well and had neither skin lesions nor evidence of disease within the body.

References

De Santo, D. A., and Burgess, E. Primary and secondary neurilemmoma of bone. Surg., Gynec. & Obst., 71:454–461, 1940.

Friedman, M. M. Neurofibromatosis of bone. Am. J. Roentgenol., 51:623–630, 1944.

Gould, E. P. The bone changes occurring in von Recklinghausen's disease. Quart. J. Med., 11:221–228, 1918.

Gross, P., Bailey, F. R., and Jacox, H. W. Primary intramedullary neurofibroma of the humerus. Arch. Path., 28:716–718, 1939.

Hart, M. S., and Basom, W. C. Neurilemoma involving bone. J. Bone & Joint Surg., 40–A:465–468, 1958.

Holt, J. F., and Wright, E. M. The radiologic features of neurofibromatosis. Radiology, 51: 647–664, 1948.

Jones, H. M. Neurilemmoma of bone. Brit. J. Surg., 41:63–65, 1953.

Miller, G. Die Knochenveränderungen bei der Neurofibromatosis Recklinghausen. Fortsch. Röntgenstrahl., 78:669–689, 1953.

Peers, J. H. Primary intramedullary neurogenic sarcoma of the ulna. Report of a case. Am. J. Path., 10:811–820, 1934.

Spilka, C. J. Neurilemmoma (schwannoma): report of case. J. Oral Surg., 11:245–248, 1953.

Stout, A. P. Personal communication, 1958.

Wilber, M. C., and Woodcock, J. A. Ganglioneuromata in bone. Report of a case. J. Bone & Joint Surg., 39–A:1385–1388, 1957.

NEURILEMOMA

(Figures 256–259 are from the same case)

Figure 256. Radiograph of a neurilemoma of a femur showing an area of fracture at the point of cystic change. (This is figure 1 in Hart, M. S., and Basom, W. C. Neurilemoma involving bone. J. Bone & Joint Surg., 40–A:465–468, 1958.) A. F. I. P. Acc. No. 218757–257.

Figure 257. In this photomicrograph of the tumor, note cystic change and variability of pattern. Hematoxylin and eosin stain. X 20. A. F. I. P. Acc. No. 218757–258.

Figure 258. Higher power photomicrograph demonstrating loose areas of tissue and zones of palisading. Hematoxylin and eosin stain. X 150. B.H. 55–5193; A. F. I. P. Acc. No. 218757–259.

Figure 259. Higher power microscopic view shows classic cellular areas suggestive of Verocay bodies. Hematoxylin and eosin stain. X 615. B.H. 55–5193; A. F. I. P. Acc. No. 218757–260.

Fig. 256

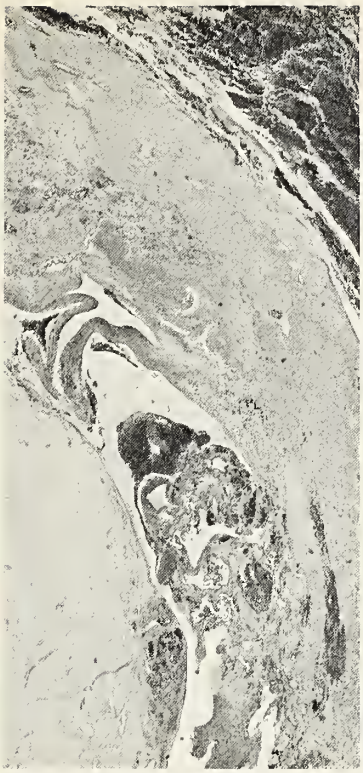

Fig. 257

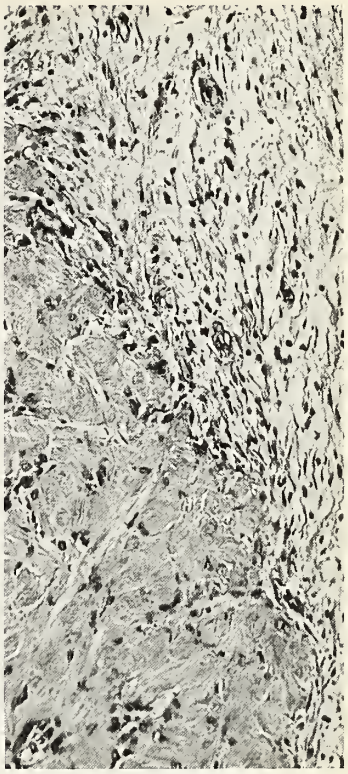

Fig. 258

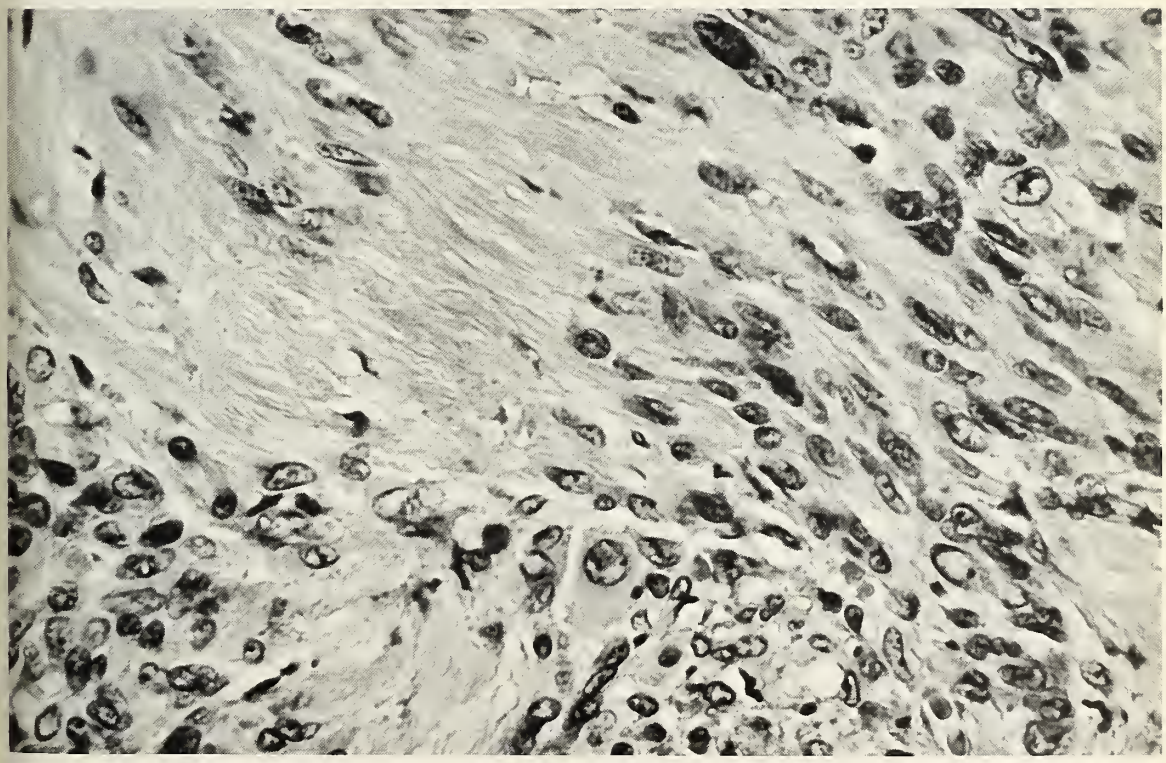

Fig. 259

TUMORS OF ADAMANTINE ORIGIN (UNCERTAIN)—PROBABLY PRIMARY MALIGNANT

Adamantinoma

SYNONYMS AND RELATED TERMS: Ameloblastoma; malignant angioblastoma.

CLINICAL DATA. Patients with the tumor are usually between 25 and 50 years of age.

Roentgenograms of adamantinoma demonstrate a well delimited osteolytic polycystic lesion close to, but not invading, the epiphysis (figs. 260, 264, 265, 270). The cortex may be intact or destroyed; the lesion may extend to involve the fibula when the tumor arises in the tibia. The tumors usually grow slowly and may remain localized without metastases for several years, but eventually pulmonary metastases develop.

PATHOGENESIS. The term adamantinoma indicates that the tumor contains enamel; in this instance, it is misleading, for enamel has never been found in these tumors. There have been numerous theories regarding their origin, including that of:

(1) Cell rests; such cell rests, however, have never been identified in or around the tibia.

(2) Trauma, with possible implantation of basal cells of the epidermis deep in the subcutaneous tissues, could be considered the most acceptable approach to histogenesis, for many patients with adamantinoma of the tibia have had a history of injury; of course, the tibia is subject to frequent injury, because it is a long bone in which skin is closely applied to the periosteum.

(3) Endothelial origin (Richter; Simon).

(4) Malignant angioblastoma (Changus et al.).

SITES OF TUMOR. Of 33 cases of adamantinoma in bone reviewed by Changus and associates, all were in the tibia except one each in the ulna and femur; moreover in two instances, the fibula was involved with the tibia.

GROSS. The lesion produces a well delimited osteolytic defect, often arising close to the epiphysial line (pl. V–D; fig. 270). The cortex is frequently destroyed by extension of tumor into soft tissue to secondarily involve a well delimited portion of the fibula. At times, however, the cortex is thickened and firm, and a pale tan-white appearance with translucent zones then prevails. When the tumor undergoes cystic degeneration, particles of bone may be scattered within the neoplasm.

MICROSCOPIC. This tumor superficially resembles adamantinomas of jaw bones (figs. 261, 262, 266–268).

Baker and associates (p. 709) described three patterns: "The first pattern consists of masses of epithelial islands in which the peripheral cells are columnar and arranged in a palisaded fashion. The central cells of these masses are stellate, producing reticulum formation. Within the center of the reticulum, cystic areas may exist. This pattern can be easily mistaken for adenocarcinoma. At times, the columnar peripheral palisaded cells appear to be lining a lumen, producing an alveolar arrangement.

"The second pattern consists of islands of cells resembling basal cells, varying greatly in size and shape and scattered throughout a fibrous stroma. Palisading may again be a feature of the peripheral cells. Cystic areas may be present within the epithelial masses which are quite reminiscent of basal-cell carcinoma [figs. 261, 262].

"The third pattern consists of islands of squamous epithelium scattered throughout a fibrous stroma. Great variation in size and shape of the islands is found. Pearl formation is a feature" (fig. 263).

Apparent vascular spaces filled with red blood cells are common; these are separated invariably by a rather loose, cellular, connective tissue framework (fig. 269).

Metastatic squamous cell carcinoma may produce a "punched-out" osteolytic defect in the metaphysis of the tibia. We have seen a metastatic squamous cell carcinoma incorrectly diagnosed as adamantinoma with the primary in the lung.

TREATMENT. Curettage invariably fails as treatment. If the lesion is well localized, block excision can result in cure. Often because of the extent of the lesion, however, amputation is indicated.

References

Baker, P. L., Dockerty, M. B., and Coventry, M. B. Adamantinoma (so-called) of the long bones. Review of the literature and a report of three new cases. J. Bone & Joint Surg., 36–A:704–720, 1954.

Changus, G. W., Speed, J. S., and Stewart, F. W. Malignant angioblastoma of bone. A reappraisal of adamantinoma of long bone. Cancer, 10:540–549, 1957.

Richter, C. S. Ein Fall von adamantinomartiger Geschwulst des Schienbeins. Ztschr. f. Krebsforsch., 32:273–279, 1930.

Simon, W. V. Die Knochensarkome. Erg. Chir. Orthop., 16:199–483, 1923.

Schulenburg, C. A. R. Adamantinoma. Hunterian lecture. Ann. R. Coll. Surgeons England, 8:329–353, 1951.

ADAMANTINOMA

(Figures 260–262 are from the same case)

Figure 260. Roentgenogram of an adamantinoma of the distal portion of a tibia of a 27-year-old woman. The lesion had originally been removed by curettage, but amputation became necessary 16 years later. (This is figure 21–2 in Dahlin, D. C. Bone Tumors. Springfield, Ill.: Charles C Thomas, 1957.) A. F. I. P. Acc. No. 218757–261.

Figure 261.* Photomicrograph showing reticulated pattern of the tumor cells in the fibrous stroma. Cystic dilation of tumor components is also demonstrated. Hematoxylin and eosin stain. X 125. A. F. I. P. Acc. No. 218757–15.

Figure 262.* Higher power microscopic view of a similar field. Hematoxylin and eosin stain. X 300. A. F. I. P. Acc. No. 218757–52.

Figure 263. Photomicrograph showing the basal cell-like pattern of an adamantinoma. Note collection of cells resembling squamous epithelium (center). Hematoxylin and eosin stain. X 260. A. F. I. P. Acc. No. 716749.

---

*Courtesy of Dr. D. C. Dahlin, Rochester, Minn.

Fig. 260

Fig. 261

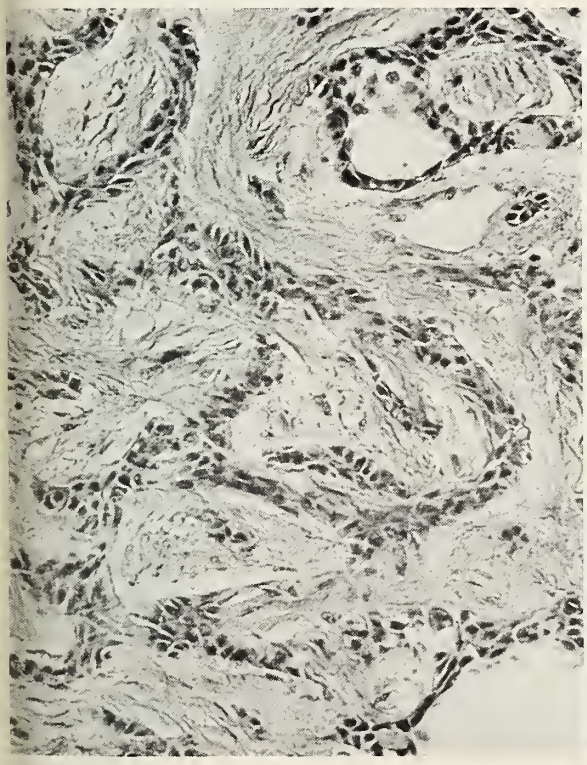

Fig. 262

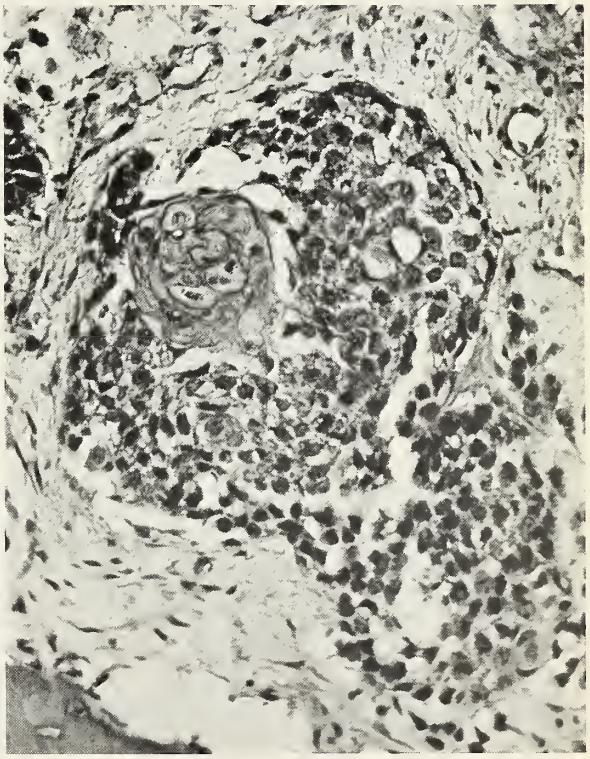

Fig. 263

ADAMANTINOMA

(Figures 264–267 are from the same case*)

Figure 264. Roentgenogram of an adamantinoma of the proximal portion of a tibia from a 44-year-old man shows an expanding destructive lesion. The tumor was curetted and packed with bone chips in 1954. However, it was persisting and still expanding in 1958. W.U. 57–6439; A. F. I. P. Acc. No. 218757–262.

Figure 265. Lateral roentgenogram of this lesion. W.U. 57–6439; A. F. I. P. Acc. No. 218757–263.

Figure 266. This histologic section illustrates a portion of the tumor which demonstrates linear nests of cells in a dense fibrous stroma. Hematoxylin and eosin stain. X 330. A. F. I. P. Acc. No. 218757–16.

Figure 267. Photomicrograph illustrating the pseudoglandular pattern that may occur in adamantinomas. Hematoxylin and eosin stain. X 125. A. F. I. P. Acc. No. 218757–18.

---

*Courtesy of Dr. R. A. Marcial, San Juan, Puerto Rico.

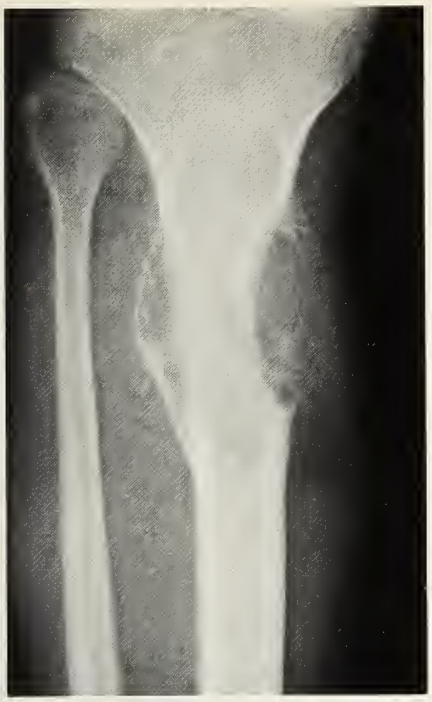

Fig. 264

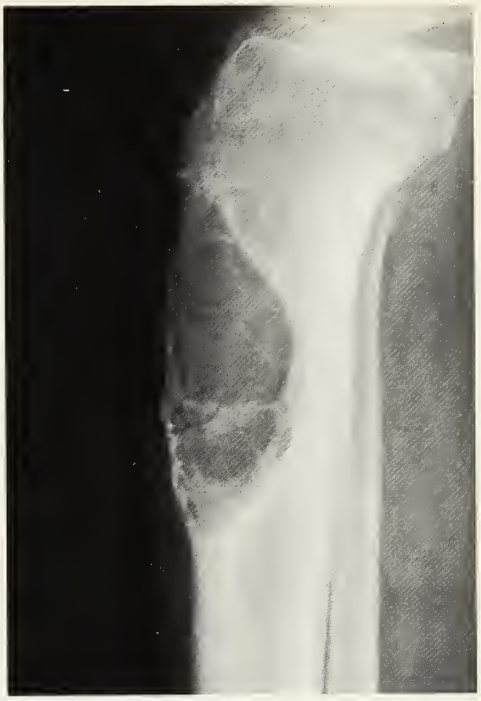

Fig. 265

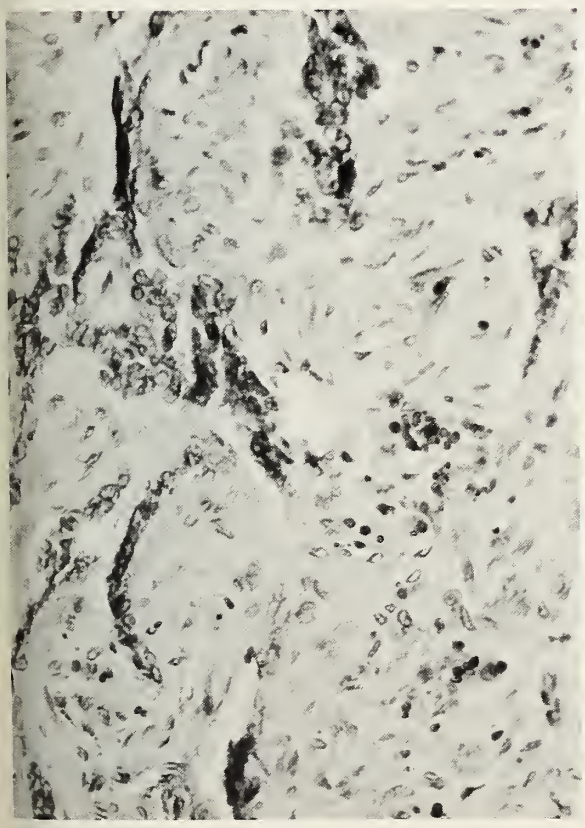

Fig. 266

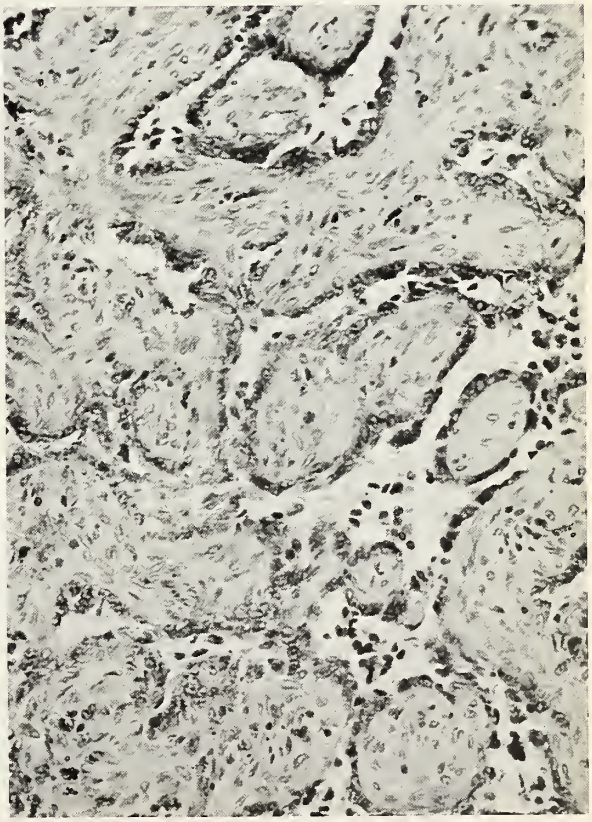

Fig. 267

ADAMANTINOMA

(Figures 268 and 269 are from the same case*)

Figure 268. Photomicrograph illustrating nests and strands of undifferentiated-appearing cells that could be misinterpreted as undifferentiated metastatic carcinoma. Hematoxylin and eosin stain. X 260. A. F. I. P. Acc. No. 740608-3.

Figure 269. Photomicrograph illustrating foci within an adamantinoma that could suggest a vascular origin for this lesion. Hematoxylin and eosin stain. X 660. A. F. I. P. Acc. No. 740608-2.

Figure 270. Roentgenogram of a large area of bone destruction in the distal metaphysis of a tibia. Bone outline in the area of the lesion was somewhat distended. Lateral view (not shown) outlined a loculated shadow and fracture through the cortex on the medial side. Biopsy established diagnosis as adamantinoma, and a below-the-knee amputation was done.

This 48-year-old man had had no complaints relative to the tumor until about five months before the limb was amputated. The first symptom noted was swelling of the lower part of the leg. About two months later, he began to complain of pain in the leg on weight-bearing and walking. Physical examination revealed a slight swelling over the distal part of the leg, which was moderately tender. A. F. I. P. Acc. No. 218757-337.

---

*From the Armed Forces Institute of Pathology.

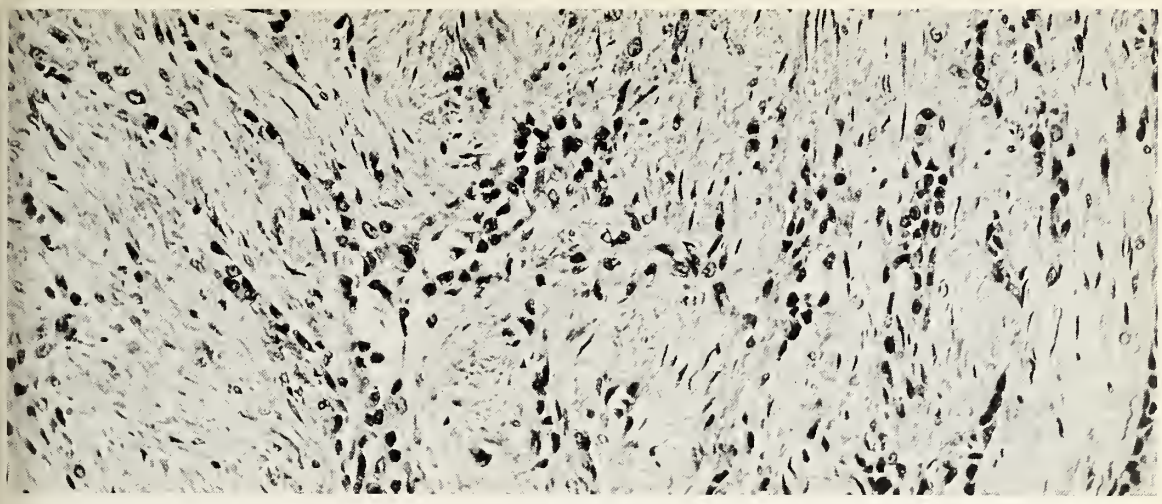

Fig. 268

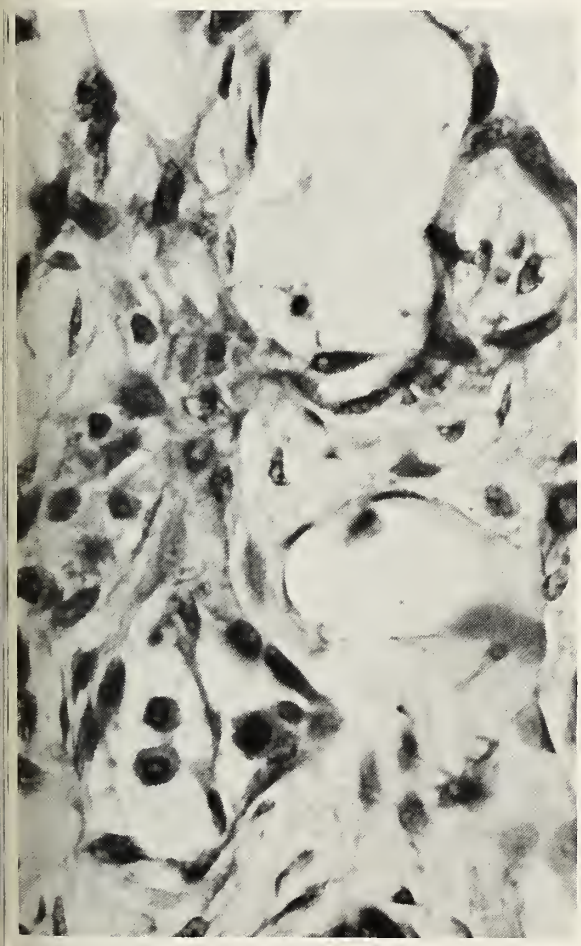

Fig. 269

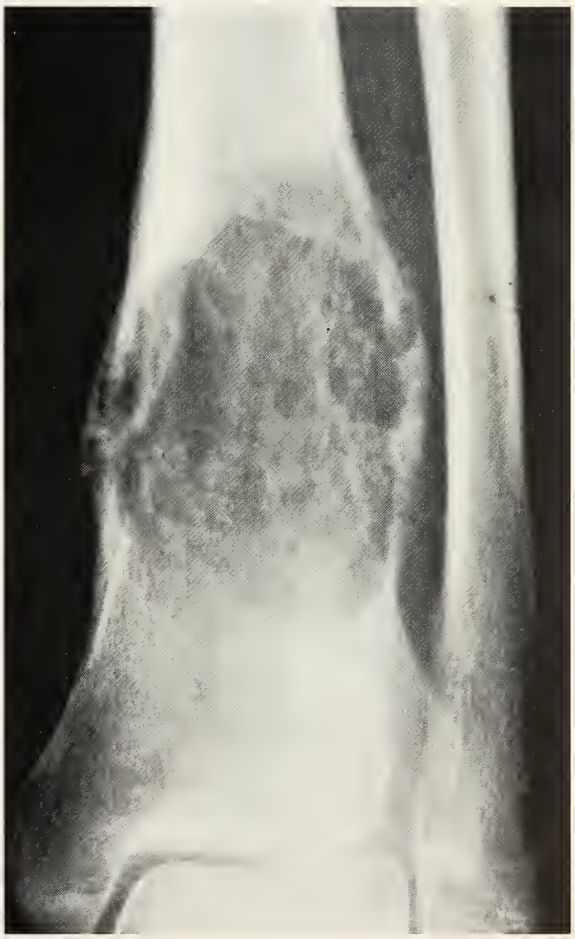

Fig. 270

PLATE V

GIANT CELL TUMOR

(Plate V–A, B and figure 220 are from the same case)

A.* Photograph of gross specimen of a giant cell tumor from the proximal portion of a femur of a 15-year-old boy. This shows lobulation of the tumor and its destruction of bone. A. F. I. P. Acc. No. 218757–380.

B.* Hemisection of the tumor also demonstrates extensive destruction of marrow and cortical bone. Cystic and hemorrhagic areas are present.

This tumor was disarticulated because the histologic pattern of biopsy had been diagnostic of malignant giant cell tumor. The patient was living, with no tumor evident, at least four years after amputation. (It is of further interest that 2½ years after disarticulation, this patient became National Golf Champion of the Handicapped.) A. F. I. P. Acc. No. 218757–381.

EWING'S SARCOMA

C. This amputated specimen presents a sagittal section of Ewing's sarcoma of the proximal portion of the right humerus of a 15-year-old boy. Note destruction of marrow space and cortex with tumor extending into soft tissues. Much of the lesion shows hemorrhagic necrosis. This patient died, two years after amputation, of disseminated Ewing's sarcoma. B.H. 50–5971; A. F. I. P. Acc. No. 218757–382.

ADAMANTINOMA

D. Photograph of a sagittal section of a gross specimen which is characteristic of adamantinoma of long bones. This shows the well circumscribed, lobular, yellow-white lesion destroying cortex of the distal portion of a tibia. (Courtesy of Dr. H. L. Jaffe, New York, N.Y., and Eastman Kodak Co., Rochester, N.Y.) A. F. I. P. Acc. No. 218757–384.

---

*Courtesy of Dr. L. W. Gardner, Detroit, Mich.

A

B

C

D

Plate V

TUMORS AND TUMOR-LIKE LESIONS SIMULATING PRIMARY TUMORS OF BONE

INVASIVE TUMORS

Benign tumors may erode bones sufficiently to produce roentgenographic features which may be confused with more serious entities:

(1) Epidermal cysts of fingers are often confused radiologically with enchondromas. The cysts are commonest in terminal phalanges; they appear as lytic lesions with a thin but intact cortex.

(2) One ganglion has been reported (Fisk) as involving the distal tibia by erosion. Grossly, the lesion was a cyst containing mucinous material; histologically, it was compatible with a ganglion.

(3) Giant cell tumors of tendon sheaths also locally erode and destroy bones (see section on Giant Cell Tumors of Tendon Sheath).

(4) Pigmented villonodular synovitis occasionally erodes adjacent bone.

(5) A glomus tumor of the finger has been described as producing a bony effect (Posch; figs. 271–273).

Malignant neoplasms also may involve bones by direct extension:

(1) Kaposi's disease has been reported as extending into, or involving, bone to cause its destruction (McCarthy and Pack; Davies).

(2) Overlying carcinoma commonly invades by direct extension. For instance, carcinoma of the gingiva may invade the mandible, carcinoma of the skin may invade underlying bones such as those in the dorsum of the hand, and carcinoma of the lung may invade vertebrae or ribs.

(3) Epidermoid carcinoma may develop in a fistulous tract formed in chronic osteomyelitis of long duration. This epidermoid carcinoma within the fistulous tract may secondarily invade the bone.

(4) Soft tissue sarcomas may secondarily invade bone (fig. 274).

METASTATIC TUMORS

Although metastases to bone are predominantly destructive, a smaller number are productive of bone (Milch and Changus). Metastases from carcinoma of the kidney and thyroid are usually osteolytic.

Either destructive or productive lesions may be produced by carcinoma of the breast. An example of characteristically osteoblastic metastatic lesions (fig. 277) is prostatic carcinoma. The destructive, or osteolytic lesions (fig. 279), are produced by most of the metastases arising from squamous epithelial structures, e.g. cervix, oral cavity, or larynx. One exception is that of carcinoma of the urinary bladder. While osteolytic lesions are commoner, osteoblastic

lesions are seen more often than would be expected from carcinomas of organs lined by squamous or transitional epithelium (Turner and Jaffe).

Theories have been advanced to explain destruction of bone by tumor: (1) that bone is destroyed by mechanical effect of the presence of the tumor, e.g. its expansion, is the most favored; (2) that a substance is elaborated by the tumor cells which promotes destructive processes in bone trabeculae. Bone production is explained on the basis that bone is stimulated to repair by its effort to combat the presence of tumor.

Metastatic Carcinoma

Carcinoma metastatic to bone is the commonest malignant tumor of bone. Its manifestations frequently mimic primary bone tumors and benign conditions, particularly when solitary. We have seen: (a) numerous metastatic cancers involving vertebrae simulating apparently typical lesions of ruptured nucleus pulposus (Odell and Key); true nature of the lesions was apparent only after histologic sections were studied; (b) a loculated lesion of long duration involving the sacrum, diagnosed as giant cell tumor or aneurysmal bone cyst (figs. 285, 286), proved metastatic thyroid cancer; (c) a lesion thought to be chondrosarcoma of the ischium represent metastatic cancer from the uterine cervix; (d) a purely osteolytic lesion at times mistaken for a unicameral bone cyst.

INCIDENCE. Although almost all malignant lesions have at some time been reported as metastasizing to or invading bone, the most frequent source of metastatic cancer of bone is breast (fig. 276), with prostate, lung, and colon the next most frequent. Considering male versus female populations, prostate is the commonest in the male, with lung, urinary bladder, and stomach the next most common; in the female population, the commonest metastatic carcinoma is from breast, and then from uterus, colon, and stomach.

At autopsy, 73 percent of patients with carcinoma of the breast, 32 percent with carcinoma of the lung, 24 percent with carcinoma of the kidney, 13 percent with carcinoma of the rectum, and 11 percent with carcinoma of the stomach had histologic evidence of metastases to bone. The incidence varies, probably depending upon the extent of bone sampling done. In 1,000 consecutive autopsied patients with carcinoma, 27 percent had metastases to bone (Abrams). In a smaller series, using only a wedge of a lumbar vertebra for sampling, an incidence of 41 percent for metastatic carcinoma was found (Young and Funk).

CLINICAL DATA. Of clinical interest is a fact well demonstrated by numerous observers that there may be extensive involvement of bone before roentgenographic evidence of metastatic disease becomes manifest (figs. 281, 282). Borak drilled holes 1 cm. in diameter through dried vertebrae. Roentgenograms of these vertebrae failed to reveal the defects in the cancellous portion of the bone, even though the cortical defects were visible. He observed, therefore, that only in advanced lesions, particularly in vertebrae, would roentgen changes be visible. The earliest recognizable defect is a change in contour

of the vertebrae rather than in trabecular pattern. Metastases that involve bones with a well developed spongiosa such as ribs, pelvis, metaphyses of long bones, and vertebrae are noted for having advanced metastatic disease but negative roentgenograms.

Of further clinical interest is the fact that pain often may be an indication of metastases even when roentgenograms are negative. In bones such as the skull or in the diaphyses of long bones where there is well developed compact or rather poorly developed cancellous bone, Borak states (p. 603) that "No roentgen-negative stage does exist . . .," e.g. roentgenograms will show a defect at the time symptoms or signs suggest the presence of metastatic disease.

SITES OF TUMOR. All bones of the body have been involved by metastatic tumor at some time, including reported rare instances of involvement of small bones of the hand (Kerin). In the phalanges, most common source of metastatic cancer is from lung; it is of interest that these metastases are often symmetrical (Uehlinger).

Bones most commonly involved by metastatic tumor are those with well developed red marrow, such as skull, rib, sternum, vertebra, pelvis, and upper femur.

MICROSCOPIC. In this section of the fascicle we chiefly are concerned with those patients having obscure diagnoses for lesions in bones. While in some bones distribution or location of the tumor may give indication of the site of the primary cancer, such determinations are mere guesses without biopsy. In metastatic pulsating destructive osteolytic lesions of the sternum, for instance, metastasis usually comes from the thyroid or kidney (fig. 280).

After biopsy of a bone lesion in which it was not clinically certain whether the process present was neoplastic or non-neoplastic, microscopic differentiation is not difficult.

SPREAD OF TUMOR. At present, evidence suggests that metastases involving bone are blood-borne in the vast majority of instances. It seems likely that few, if any, metastases are transported to bones via the lymphatics. A few metastases may become lodged in lymphatics of the periosteum. In a bone, the tumor spreads through the medullary cavity and the haversian and Volkmann's canals. Apparently this permeation through the medullary cavity makes roentgen detection difficult, particularly in spongy bones.

DIFFERENTIAL DIAGNOSIS. In most instances, differentiation between primary malignant bone tumor and metastatic malignant tumor is clear. By combining clinical information with microscopic findings, the pathologist usually can determine origin of the tumor. In metastatic cancer from the kidney, for instance, a typical pattern may be seen which enables the pathologist to insist that the primary tumor is present in the kidney.

When a well defined adenocarcinoma is present, mucin stain may reveal the presence of epithelial mucin; with the typical pattern of individual cells,

this finding may suggest pancreas, large bowel, or stomach as the site of the primary.

Other primary cancers, such as those from the lung and gallbladder, can produce mucin; metastatic cancers from the prostate and thyroid, however, practically never produce it. At times, cancer metastatic from the thyroid may resemble normal thyroid or may take up radioactive iodine so that its source is obvious.

A metastatic tumor may be confused with a primary malignant tumor by a pathologist, because presence of metastasis alone may cause secondary overproduction of bone. When this is associated with an undifferentiated tumor, the pathologist erroneously may consider primary osteosarcoma (figs. 282, 284). If metastatic cancer is associated with a fracture with considerable callus formation, this, too, may be confusing. Confusion of primary malignant bone tumor with metastatic cancer fortunately occurs less commonly.

Malignant Lymphomas and Leukemias

In autopsy surveys, comparisons of those entities involving bone as secondary manifestations of the disease show that 49 percent of patients with Hodgkin's disease and approximately 29 percent of those with lymphosarcoma had evidence of bone lesions. In a corresponding series in which roentgenographic evidence of bone involvement was tabulated, Hodgkin's disease was demonstrated secondarily in bone in 14.8 percent of the patients and lymphosarcoma in 7 percent. Of interest in this latter series, too, was the observation that the average duration of life after detection of Hodgkin's disease was 17 months; however in lymphosarcoma, average survival under similar circumstances was 5.8 months. In reviewing the course of the disease in these two lesions, more than one third of the osseous lesions of Hodgkin's disease were detected before one half of the course of the disease had elapsed; comparatively in lymphosarcoma, almost two thirds of the lesions were detected during the latter one third of the course of the disease (Vieta et al.). An unusual feature of Hodgkin's disease is that approximately 14 percent of its metastases are osteoblastic (fig. 278), while it is rare for metastases of lymphosarcomas to be osteoblastic; pure osteoblastic lesions are most commonly seen in the vertebrae and occasionally may be single.

Bone also is commonly involved as a secondary manifestation of malignant lymphomas, and giant follicular lymphomas cause demonstrable lesions in the rarest of circumstances. Reticulum cell sarcoma, other than that primary in bone, may be seen in bone as a metastatic process. Leukemia may cause either destructive or sclerotic lesions in bone (Brünner et al.), lymphocytic leukemia apparently more commonly than myelocytic leukemia.

References

Abrams, H. L. Skeletal metastases in carcinoma. Radiology, 55:534–538, 1950.

———, Spiro, R., and Goldstein, N. Metastases in carcinoma. Analysis of 1000 autopsied cases. Cancer, 3:74–85, 1950.

Borak, J. Relationship between the clinical and roentgenological findings in bone metastases. Surg., Gynec. & Obst., 75:599–604, 1942.

Brünner, S., Gudbjerg, C. E., and Iversen, T. Skeletal lesions in leukaemia in children. Acta radiol., 49:419–424, 1958.

Carroll, R. E. Epidermoid (epithelial) cyst of the hand skeleton. Am. J. Surg., 85:327–332, 1953.

Davies, A. G. M. Bone changes in Kaposi's sarcoma. Analysis of 15 cases occurring in Bantu Africans. J. Fac. Radiologists, 8:32–40, 1956.

Fisk, G. R. Bone concavity caused by a ganglion. J. Bone & Joint Surg., 31–B:220–221, 1949.

Jaffe, H. L. Tumors and Tumorous Conditions of the Bones and Joints. Desmoplastic Fibroma and Fibrosarcoma, pp. 298–313. Philadelphia: Lea & Febiger, 1958.

Kerin, R. Metastatic tumors of the hand. J. Bone & Joint Surg., 40–A:263–278, 1958.

Lovell, W. W., King, R. E., and Alldredge, R. Carcinoma in the skin, sinuses and bone following chronic osteomyelitis. South. M. J., 50:266–271, 1957.

McAnally, A. K., and Dockerty, M. B. Carcinoma developing in chronic draining cutaneous sinuses and fistulas. Surg., Gynec. & Obst., 88:87–96, 1949.

McCarthy, W. D., and Pack, G. T. Malignant blood vessel tumors. A report of 56 cases of angiosarcoma and Kaposi's sarcoma. Surg., Gynec. & Obst., 91:465–482, 1950.

Milch, R. A., and Changus, G. W. Response of bone to tumor invasion. Cancer, 9:340–351, 1956.

Odell, R. T., and Key, J. A. Lumbar disk syndrome caused by malignant tumors of bone. J.A.M.A., 157:213–216, 1955.

Posch, J. L. Tumors of the hand. J. Bone & Joint Surg., 38–A:517–540, 1956.

Rubenfeld, S. Osseous manifestations in the malignant lymphomas. Bull. Hosp. Joint Dis., 17: 271–280, 1956.

Shackman, R., and Harrison, C. V. Occult bone metastases. Brit. J. Surg., 35:385–389, 1948.

Sherman, R. S., and Pearson, T. A. The roentgenographic appearance of renal cancer metastasis in bone. Cancer, 1:276–285, 1948.

Turner, J. W., and Jaffe, H. L. Metastatic neoplasms. A clinical and roentgenological study of involvement of skeleton and lungs. Am. J. Roentgenol., 43:479–492, 1940.

Uehlinger, E. Personal communication, 1959.

Vieta, J. O., Friedell, H. L., and Craver, L. F. A survey of Hodgkin's disease and lymphosarcoma in bone. Radiology, 39:1–15, 1942.

Walther, H. E. Krebsmetastasen. Basel, Switzerland: Benno Schwabe & Co., 1948.

Weese, K. Zur Genese der Knochenbildung in den Knochenmetastasen der Carcinome. Virchows Arch., 329:1–12, 1956.

Willis, R. A. The Spread of Tumours in the Human Body. 2nd ed. London: Butterworth & Co., Ltd., 1952.

Young, J. M., and Funk, J. F., Jr. Incidence of tumor metastasis to the lumbar spine. A comparative study of roentgenographic changes and gross lesions. J. Bone & Joint Surg., 35–A:55–64, 1954.

CYSTS—BENIGN

Solitary Unicameral Bone Cyst

SYNONYMS AND RELATED TERMS: Benign bone cyst; bone cyst; juvenile unicameral bone cyst; simple bone cyst; solitary bone cyst.

DEFINITION. An uncommon fluid-filled, expansile, benign cavitary lesion having predilection for proximal or distal ends of long bones, often near the epiphysial plate.

INCIDENCE. Seventy-five percent of these lesions occur in the femur or humerus (Garceau and Gregory), usually the proximal portion adjacent to the epiphysial plate. Although erosion of the epiphysial plate by a cyst is rare,

Key reported having seen three that had crossed the epiphysial line to involve the head of the femur and humerus (Stewart and Hamel). Fewer cysts have been reported in other long bones, such as the radius, ulna, fibula, tibia, and metatarsal; occasional cysts have been observed in the calcaneus.

These cysts are diagnosed in childhood or adolescence (figs. 287, 288). They are most frequently seen in patients between 9 and 14 years of age, with an age range of 2 to 50 years; in fact, one patient with a bone cyst of the diaphysis of the humerus was seen by us when in her seventh decade. There is sex predilection for the male, in some series 2:1.

CLINICAL DATA. Clinical signs and symptoms are slight unless there is a fracture through the cyst; mild pain and perhaps swelling or stiffness of the nearest joint are likely to be the only outstanding symptoms. However, fracture occurs in about 65 percent of patients, and commonly calls attention forcefully to its presence.

This is a lesion in which it is absolutely essential that the radiograph also be available; otherwise exact diagnosis is extremely difficult, if not impossible.

PATHOGENESIS. Theories of pathogenesis of unicameral bone cysts have been well summarized (James et al.; Jaffe and Lichtenstein): (1) result of cystic degeneration of bone tumor; (2) result of organization of a low grade inflammatory process; (3) relation to some local disturbance of bone growth, perhaps combined with trauma, resultant organization, and cystic change within a hematoma.

This lesion has emerged from a maze of cystic lesions and "fibrocystic diseases" of bone as a distinct entity (Bloodgood; Jaffe and Lichtenstein).

GROSS. Its descriptive gross features have been chiefly derived from detailed roentgenologic anatomy (Lodwick) and surgical findings. The frequent roentgenographic observation of a smooth cortical surface is borne out by the finding of a smooth but often exceedingly thin cortex which may show small defects. Soft tissues surrounding the cyst and the covering periosteum which separates easily show little if any pathologic alteration unless a fracture has transgressed the cyst.

Fluid in the cyst imparts a bluish sheen to the exposed cortex and periosteum. Fluid content may be clear and yellow, blood-tinged, or frankly bloody if fracture has occurred; occasionally no fluid has been found, or altered blood may be present.

After removal of any fluid present, bony ridges of varied sizes and thickness may be observed (fig. 289). However, these ridges do not divide the cyst into compartments. While the unicameral form is maintained, these bony ridges do give a multiloculated appearance to many of the cysts when viewed by roentgenograms. The inner surface of the cyst is mostly gray-white, but reddish brown or brown areas may be seen; these represent the altered blood and are usually a result of previous trauma to the cyst. If trauma has not altered the cyst, curettings from the wall may be meager.

MICROSCOPIC. Specific diagnostic features are lacking. The lining membrane varies from a few strands of connective tissue to a fairly thick and sometimes vascular connective tissue; occasionally isolated osteoid and mature bone may be seen in this membrane. Bone which has been formed recently may constitute part of the cyst wall; this bony wall is usually less compact than normal cortical bone. Intertrabecular spaces frequently contain numerous blood vessels. Subperiosteal bone formation is seen, particularly if the cyst is complicated by fracture. In areas of injury, osteoblastic and osteoclastic activity may be found. Areas of luxuriant repair with numerous giant cells have been confused with and diagnosed as cystic giant cell tumors and aneurysmal bone cysts. Foci of new bone and accompanying fibrosis have been mistaken for fibrous dysplasia.

Most cysts contain foci of granulation tissue, evidence of old hemorrhage, fibrin, calcific deposits, cholesterol slits, macrophages, and a few varied inflammatory cells (figs. 290–292); recurrent cysts also contain residuals of bone chip grafts (fig. 294).

Histologic features of active cysts near the epiphysial plate and inactive cysts which are said to have migrated into the diaphysis are similar.

TREATMENT. Approximately 15 percent of these cysts have been noted to heal after fracture. Though varied, treatment is not always successful. Curettage followed by insertion of autogenous or homogeneous bone chips has been considered the most productive basic means of treatment. Chemical cauterization of the cyst wall before addition of bone chips is not universally done. Radiation therapy has been tried but discarded as unsuccessful according to most authors; not only is there hesitance in giving irradiation for lesions commonly so near the epiphysial plate, but danger of postradiation sarcomatous development has also been cited as a contraindication to this type of therapy (James et al.).

Results of treatment vary with differences in locations of the cysts, i.e. those near the epiphysial plate are less successfully treated than those not near the epiphysis. This may be due partially to performance of less vigorous curettage when the lesion is near the epiphysial plate because of the danger of damaging it, with resultant epiphysial arrest (fig. 293).

PROGNOSIS. Follow-up of 31 patients with unicameral bone cysts revealed 13 (41.9 percent) with recurrence one to nine years after treatment (Graham). One patient had 2 recurrences; 3 had 3 recurrences; the remainder had 1 recurrence. Others have reported a recurrence rate of 21 to 26 percent (Garceau and Gregory).

Aneurysmal Bone Cyst

SYNONYMS AND RELATED TERMS: Aneurysmal giant cell tumor; atypical giant cell tumor; benign bone aneurysm; expansile hemangioma; hemangiomatous bone cyst; hemorrhagic bone cyst; ossifying hematoma; ossifying subperiosteal hematoma; subperiosteal giant cell tumor.

DEFINITION. A benign, solitary, localized tumor appearing most often in vertebrae, flat bones, or long bones.

CLINICAL DATA. Swelling, pain, tenderness, and limitation of motion of a joint are commonest complaints. Severe joint limitation is well illustrated by two cases of Lichtenstein (1953) in which there was extensive erosion of articular cartilages by the expanding cyst. Nerve pain and paresthesias also may develop if a cyst of the vertebrae, for example, becomes large enough to impinge upon nerves.

Rate of growth of these cysts seems unpredictable; for instance, a cyst of the rib which had remained unchanged by roentgenogram for a 10-year period was observed by us (fig. 300). The patient was finally persuaded to have the lesion resected.

The cysts most commonly occur in the second and third decades, but ages of patients have ranged from 4 to 61 years (Sherman and Soong). Clear-cut sex predilection is not evident; however, there seems to be slight predominance of women in larger series.

Roentgenologic findings are characteristic, and with increased knowledge of these lesions by radiologists, accurate clinical diagnoses now are being made (fig. 304). Formerly, however, roentgenographic diagnoses, such as giant cell tumor, bone cyst, osteochondroma, osteosarcoma, hemangioma, and Ewing's tumor, have been made for such lesions (Dahlin et al.; fig. 298).

By serial roentgenographic studies, Sherman and Soong have traced the development of aneurysmal bone cysts. They described an initial lytic lesion, followed by a mature or more characteristic lesion, and finally a calcified stage. The majority of their patients presented mature phases of aneurysmal bone cysts.

PATHOGENESIS. Aneurysmal bone cyst was crystallized as a clinical and pathologic entity by Jaffe and Lichtenstein in 1942. Subsequent studies (Lichtenstein; Dahlin et al.; Sherman and Soong; and others) have added greatly to knowledge concerning diagnosis and course of this lesion.

Although its etiology is unknown, two of the various explanations advanced are: subperiosteal hemorrhage with organization; and vascular disturbance within the bone, such as thrombosis of a vein or an arteriovenous communication. In fact, by careful study of two amputational specimens of aneurysmal bone cyst of a femur and a fibula, Hadders and Oterdoom were led to conclude that aneurysmal bone cyst is in reality a hemangioma.

The role of trauma in genesis of the lesion is not established. As many as one half of patients give a history of trauma to the affected part. However, it is possible that trauma only served as an alert for or caused an exacerbation of a pre-existing lesion.

SITES OF TUMOR. Almost all bones have been reported as being involved by aneurysmal bone cyst, including isolated instances in the occipital bone, ribs, sternum, metacarpals, metatarsals, and phalanges. In long bones, the lesion may be located in the shaft or proximal or distal portions of the

bone. It is commonly eccentrically placed but may be central in its location; frequently a subperiosteal position also has been demonstrated.

GROSS. Specimens frequently consist only of biopsy curettements. However, intact aneurysmal bone cysts have been obtained for study either when the lesion was so located that it could be resected without deformity or in those unfortunate instances in which clinical and radiographic diagnosis of malignant bone tumor had been made (figs. 295–297).

Because of the expansile nature of the lesion, the involved bone is greatly distorted and may be partly destroyed. The cysts vary in size from 2 to 23 cm. in diameter. Outlines of the lesions are irregular, a thin shell of cortical bone or new subperiosteal bone usually serving as the delimiting boundary. When bone is absent, thickened periosteum and compressed soft tissues may bound parts of the lesions. These masses have often been described as spongy, for on the cut surface the structure is honeycombed or spongelike; the tissue is usually dark red to red-brown, or brown. Varied sized cystic spaces containing fresh blood or blood in different stages of clotting and organization are outstanding features. Trabeculae of bone or fibrous tissue intermingled with relatively solid fibrous or bony areas traverse the lesion. Small lesions, presumably less advanced in their development, are usually more solid and less cavernous than are the large aneurysmal bone cysts (fig. 303). Solid areas are fibrous, though histologically vascular.

MICROSCOPIC. Although the pattern is varied, basically the lesion is formed by large and small vascular channels which may be outlined by trabeculae of fibrous tissue, fibrous tissue and osteoid, or granulation-like tissue in which numerous multinucleated giant cells are seen. Trabeculae separating these cavernous channels are of different thicknesses and lengths, but tend to be spindly (figs. 305–309). Solid areas of fibrous tissue, spindly osteoid, mature bone, and giant cells may be seen (figs. 299, 301, 302). The latter, with the cavernous channels, may give rise to a false impression of vascular giant cell tumor. Since cartilage also occasionally has been observed, the areas of active osteoid and bone formation with proliferative stromal background, if not carefully studied, could be and have been mistaken for osteosarcoma; however, confusion with the more benign lesions is more prevalent.

From studies of a number of aneurysmal bone cysts in addition to those illustrated in the fascicle, vascular channels seem lined by an indistinct endothelium, and the walls are devoid of a muscularis. In the stroma of the lesion are noted hemosiderin, extravasated blood, histiocytes, and varied inflammatory components. Peripherally, subperiosteal bone formation may be present, while adjacent soft tissues, such as skeletal muscle, fat, and connective tissue, are compressed.

TREATMENT. Lesions respond favorably to surgical or roentgen ray therapy. Surgical therapy usually consists of curettage followed by insertion of bone chips; however, small lesions in favorable sites are sometimes resected.

After curettage, persistence of the lesion is quite common and necessitates a second surgical procedure.

Sherman and Soong report no failures in eight patients treated by roentgen ray therapy. In a recent survey of 50 cases of aneurysmal bone cyst, Lichtenstein (1957) advised prompt radiation therapy for those lesions either deemed unsatisfactory for surgical approach, or for which surgical intervention had proved unsuccessful. Only "moderate" doses of roentgen rays are indicated.

References

Beeler, J. W., Helman, C. H., and Campbell, J. A. Aneurysmal bone cysts of spine. J.A.M.A., 163:914–918, 1957.

Bloodgood, J. C. Benign bone cysts, ostitis fibrosa, giant-cell sarcoma and bone aneurism of the long pipe bones. Ann. Surg., 52:145–189, 1910.

Copleman, B., Vidoli, M. F., and Crimmings, F. J. Solitary cyst of the calcaneus. Radiology, 47:142–148, 1946.

Dahlin, D. C., Besse, B. E., Jr., Pugh, D. G., and Ghormley, R. K. Aneurysmal bone cysts. Radiology, 64:56–65, 1955.

Garceau, G. J., and Gregory, C. F. Solitary unicameral bone cyst. J. Bone & Joint Surg., 36–A: 267–280, 1954.

Graham, J. J. Solitary unicameral bone cyst. Follow-up study of 31 cases with proven pathological diagnoses. Bull. Hosp. Joint Dis., 13:106–130, 1952.

Hadders, H. N., and Oterdoom, H. J. The identification of aneurysmal bone cyst with haemangioma of the skeleton. J. Path. & Bact., 71:193–200, 1956.

Jaffe, H. L., and Lichtenstein, L. Solitary unicameral bone cyst. With emphasis on the roentgen picture, the pathologic appearance and the pathogenesis. Arch. Surg., 44:1004–1025, 1942.

James, A. G., Coley, B. L., and Higinbotham, N. L. Solitary (unicameral) bone cyst. Arch. Surg., 57:137–147, 1948.

Lichtenstein, L. Aneurysmal bone cyst. A pathological entity commonly mistaken for giant-cell tumor and occasionally for hemangioma and osteogenic sarcoma. Cancer, 3:279-289, 1950.

———. Aneurysmal bone cyst. Further observations. Cancer, 6:1228–1237, 1953.

———. Aneurysmal bone cyst. Observations on fifty cases. J. Bone & Joint Surg., 39–A: 873–882, 1957.

Lodwick, G. S. Juvenile unicameral bone cyst. A roentgen reappraisal. Am. J. Roentgenol., 80:495–504, 1958.

Sherman, R. S., and Soong, K. Y. Aneurysmal bone cyst: its roentgen diagnosis. Radiology, 68:54–64, 1957.

Stewart, M. J., and Hamel, H. A. Solitary bone cyst. South. M. J., 43:927–936, 1950.

TUMOR-LIKE LESIONS OF FIBROUS TISSUE ORIGIN—BENIGN

Fibrous Dysplasia

SYNONYMS AND RELATED TERMS: Bone cyst; fibroma ossificans; fibrous osteoma; focal area of osteodystrophia fibrosa; focal fibrosis of bone; focal osteitis fibrosa; localized fibrocystic disease; ossifying fibroma; osteofibroma.

DEFINITION. A benign, relatively common, fibro-osseous monostotic or polyostotic, sharply delimited pathologic abnormality of bone of unknown etiology.

INCIDENCE. This is usually a monostotic process but may be polyostotic (9 of 23 cases, Reed). Rarely, it may assume the identity described by Albright

and associates as precocious puberty with pigmentation and predominantly unilateral polyostotic lesions. In the classic manifestation of this abnormality in a rib, the bone is involved in the well delimited process by fusiform expansion, thinning of the cortex, and bone replacement by a homogeneous pathologic process (fig. 310). Fibrous dysplasia is one of the commonest benign tumescences of ribs; in a series studied by Hochberg and Crastnopol, it represented 31.5 percent of benign and 16.5 percent of all rib lesions.

Review of a series of 69 cases of fibrous dysplasia by Schlumberger revealed that further distribution of the lesion was as follows: rib 29; femur 9; tibia 8; maxilla 7, the commonest site of involvement of the skull bones; calvarium 5; mandible, humerus, and ulna each 2; vertebra, pelvis, and fibula each 1; of the 2 remaining cases, 1 had involved the tibia and femur and the second was polyostotic.

CLINICAL DATA. In a series of 256 cases of fibrous dysplasia collected from the literature, Pritchard observed that the disease could be traced as beginning in childhood in 131 of the patients. In only 11 cases was the lesion strictly unilateral when it was polyostotic. Fractures had occurred in 102 of the patients. Seventy-nine of the 256 patients had skin pigmentation; the prominence and abundance of this increased with severity of the disease. Two patients with the monostotic fibrous dysplasia of bone described by Russell and Chandler also had skin pigmentation.

Although this lesion of young adults more frequently occurs in boys than girls, Albright's syndrome is predominantly found in young girls; however, two cases have been reported by Albright and associates in which the patients were boys. The syndrome is not characterized solely by precocious puberty; one patient had what was termed precocious bone development.

In weight-bearing bones such as the tibia, fractures may occur with complication of the process by fracture repair (fig. 311).

PATHOGENESIS. Lichtenstein and Jaffe have suggested that the lesion represents a form of congenital anomaly, or, at least, a malfunction of bone-forming mesenchyme; they have likened the lesion to a hamartoma. Bengold has suggested that fibrous dysplasia represents a sequela of hemorrhage in bone, an intraosseous hematoma undergoing incomplete repair by fibrous tissue intermixed with bone. If only fibrous tissue participates in incomplete repair of the hematoma, he suggests that a nonosteogenic fibroma, or fibrous defect, is formed. If no repair of the intraosseous hematoma occurs, a cyst may form. If complete repair occurs, normal bone will eventuate. However, we are not in accord with this theory, but believe that the pathogenesis and etiology of fibrous dysplasia of bone are unknown.

GROSS. Myxomatous foci may be seen in the fibrous tissue; rarely small islands of cartilage may be seen. Epiphyses are usually spared. Occasional cysts have been described as occurring in the process (Lichtenstein and Jaffe). Often the lesion is sufficiently soft to be cut with a knife. Lesions involving the

base of the skull or the maxilla are often harder than lesions of other bones, because of the correspondingly larger quantity of bone found in fibrous dysplasia of these bones. Confirmation of this finding is found in the fact that the lesion of fibrous dysplasia in long bones or in ribs is commonly radiolucent, but in skull bones the lesion is commonly radiopaque.

MICROSCOPIC. Pathologic findings in typical cases of either monostotic or polyostotic fibrous dysplasia provide recognition of the entity without difficulty. Poorly oriented trabeculae of bone that may be semicalcified and separated by cellular fibrous tissue can be seen (fig. 312). Under polarized light, the bone seems woven rather than lamellar. This aids in distinguishing fibrous dysplasia from other fibro-osseous lesions (figs. 314, 315). Cartilage is rarely present. Formation of bone, one of the major components of fibrous dysplasia, undoubtedly represents metaplasia of connective tissue. By use of the Hortega technic, Valls and associates have been able to demonstrate formation of trabeculae from what they term reticulohistiocytic elements of the tumor. The new bony trabeculae are irregular in size, shape, and distribution; they are poorly oriented, and apparently have no relation to the function of the involved bone.

TREATMENT. In monostotic fibrous dysplasia, treatment consists of either curettement with replacement of curetted material by bone chips, or local resection if the lesion occurs in bone such as rib.

In polyostotic fibrous dysplasia, multiple lesions may require treatment. For instance, we saw one patient in whom dyspnea had developed after involvement of multiple ribs and extension of the process within the pleural cavity; tumefaction caused respiratory embarrassment. When the tissue was removed, it weighed over 1,000 gm.

PROGNOSIS. Good prognosis is usual. Under the rarest of circumstances, however, fibrous dysplasia may become fibrosarcoma or osteosarcoma (Perkinson and Higinbotham); we have seen such a case of fibrosarcoma occur in the tibia. Coley and Stewart also have reported two cases in which the lesions apparently had undergone such transformations and were diagnosed as pleomorphic sarcomas. When these transitions occur, prognosis assumes that for the disease noted.

DIFFERENTIAL DIAGNOSIS. Histologic findings in this lesion may also promote a tendency toward misinterpretation as: (1) osteosarcoma, in those cases in which the process is in a stage of evolution—particularly the relatively young bone of young children; (2) fibrosarcoma, when wide zones of highly cellular connective tissue are present; (3) giant cell tumor, when focal collections of giant cells are present (fig. 313).

If the concept that fibrous dysplasia in part represents a defect in the conversion of woven bone to lamellar bone, confusion of this lesion with ossifying fibroma, fibrous osteoma, osteoma, and cherubism will not be made (Reed, 1959).

In fibrous dysplasia, there is no osteoblastic rimming of bone trabeculae which may be seen in other fibro-osseous lesions.

Metaphysial Fibrous Defect

SYNONYMS AND RELATED TERMS: Fibroma; fibrous cortical defect; nonossifying fibroma; nonosteogenic fibroma.

DEFINITION. A fibrous tissue lesion, probably non-neoplastic, occurring as a well delimited defect in the metaphysial part of bones, long bones particularly.

CLINICAL DATA. This lesion occurs chiefly in children, with equal distribution between boys and girls. It is commonly present in the femur, tibia, and fibula (figs. 316, 317; table IV).

Metaphysial fibrous defect is one of the few lesions of bone in which radiographic accuracy of diagnosis is approximately 100 percent.

Table IV

DISTRIBUTION OF METAPHYSIAL FIBROUS DEFECT IN LONG BONES

	Jaffe and Lichtenstein	Hatcher	Cunningham and Ackerman
Upper Extremities:			
Humerus			
proximal	.....	.....	2
Radius			
distal	.....	.....	1
Ulna			
distal	1	.....	.....
Lower Extremities:			
Femur			
proximal	.....	.....	1
distal	1	32	3
Tibia			
proximal	3	11	1
distal	1	5	7
Fibula			
proximal	1	.....	2
distal	1	2	.....
position not stated	2	.....	.....
Site not stated	.....	1	.....
Totals	10	51*	17

*17 cases histologically verified.

This table is adapted from table I in Cunningham, J. B., and Ackerman, L. V. Metaphyseal fibrous defects. J. Bone & Joint Surg., 38–A: 797–808, 1956.

PATHOGENESIS. "Several facts indicate that the lesion arises as a result of some developmental aberration at the epiphyseal plate.

1. It has been found only in the metaphysis of a bone;

2. It migrates (relatively) away from the epiphysis as the bone grows in length;

3. It tends to be elongated in the longitudial [sic] axis of the bone, as though the abnormal development had occurred over a period of time;

4. Ponseti and Friedman have illustrated three successive lesions arising from the same area of the epiphyseal plate, indicating that the factors producing the defects may act intermittently;

5. No evidence of malignant transformation or unusual mitotic activity has been noted" (Cunningham and Ackerman, p. 807).

GROSS. The lesions of the defect appear soft and yellow. They are characteristically located eccentrically in metaphysial areas and have scalloped sclerotized margins.

MICROSCOPIC. These complicated masses of fairly cellular connective tissue are often interspersed with multinucleated giant cells and foam cells. The presence of the giant cells has unfortunately confused the lesion in the past with giant cell tumors. However, no evidence of new bone formation is observed (figs. 318–320).

Jaffe considers nonossifying fibromas as more advanced forms of metaphysial fibrous defect in that they no longer are confined to the cortex but involve the medullary cavity.

TREATMENT. Curettement is curative. Under some conditions this lesion may become so large in a weight-bearing bone that fracture occurs.

DIFFERENTIAL DIAGNOSIS. Although this lesion is not considered a true neoplasm, it has been described to eliminate the possibility of continued confusion with giant cell tumor. Cellularity of the fibrous tissue in infrequent instances has also created confusion between it and fibrosarcoma.

Periosteal Desmoid

DEFINITION. A rare lesion of children and young adults usually occurring in association with periosteum and localized destruction of bone.

CLINICAL DATA. Kimmelstiel and Rapp reported four cases in males of 8, 16, 19, and 20 years of age. Two of these patients had histories of trauma; in one of the two patients amputation unfortunately was done.

PATHOGENESIS. These well delimited masses apparently arise from periosteum. The lesions are firm and grayish pink. Localized destruction of bone (fig. 321) is caused by them.

MICROSCOPIC. Adult fibroblasts with much intercellular collagen comprise these lesions which may be confused radiographically with malignant neoplasms. Even though mitotic figures are few, the lesions may be incorrectly interpreted as fibrosarcoma. In one case of Kimmelstiel and Rapp, for

instance, erosion of the bony floor with osteoclastic activity was noted (fig. 322).

References

Albright, F., Scoville, B., and Sulkowitch, H. W. Syndrome characterized by osteitis fibrosa disseminata, areas of pigmentation, and a gonadal dysfunction. Further observations including the report of two more cases. Endocrinology, 22:411–421, 1938.

Bingold, A. C. Benign fibrous tumours of single bones. Hunterian lecture. Ann. R. Coll. Surgeons England, 18:28–45, 1956.

Coley, B. L., and Stewart, F. W. Bone sarcoma in polyostotic fibrous dysplasia. Ann. Surg., 121:872–881, 1945.

Cunningham, J. B., and Ackerman, L. V. Metaphyseal fibrous defects. J. Bone & Joint Surg., 38–A:797–808, 1956.

Dahlin, D. C. Bone Tumors. Fibrous Dysplasia, pp. 198–201. Springfield, Ill.; Charles C Thomas, 1957.

Hatcher, C. H. The pathogenesis of localized fibrous lesions in the metaphyses of long bones. Ann. Surg., 122:1016–1030, 1945.

Hochberg, L. A., and Crastnopol, P. Tumors of the ribs. Dis. of Chest, 28:406–415, 1955.

Jaffe, H. L. Tumors and Tumorous Conditions of the Bones and Joints. Fibrous Cortical Defect and Non-ossifying Fibroma, pp. 76–91. Philadelphia: Lea & Febiger, 1958.

———, and Lichtenstein, L. Non-osteogenic fibroma of bone. Am. J. Path., 18:205–221, 1942.

Kimmelstiel, P., and Rapp, I. H. Cortical defect due to periosteal desmoids. Bull. Hosp. Joint Dis., 12:286–297, 1951.

Lichtenstein, L., and Jaffe, H. L. Fibrous dysplasia of bone. A condition affecting one, several or many bones, the graver cases of which may present abnormal pigmentation of skin, premature sexual development, hyperthyroidism or still other extraskeletal abnormalities. Arch. Path., 33:777–816, 1942.

Marek, F. M. Fibrous cortical defect (periosteal desmoid). Bull. Hosp. Joint Dis., 16:77–87, 1955.

Perkinson, N. G., and Higinbotham, N. L. Osteogenic sarcoma arising in polyostotic fibrous dysplasia. Report of a case. Cancer, 8:396–402, 1955.

Phemister, D. B., and Grimson, K. S. Fibrous osteoma of the jaws. Ann. Surg., 105:564–583, 1937.

Ponseti, I. V., and Friedman, B. Evolution of metaphyseal fibrous defects. J. Bone & Joint Surg., 31–A:582–585, 1949.

Pritchard, J. E. Fibrous dysplasia of the bones. Am. J. M. Sc., 222:313–332, 1951.

Reed, R. J. Observations on bone maturation and fibrous dysplasia of bone. Bull. Tulane M. Fac., 19:45–53, 1959.

———. A precise histologic definition of fibrous dysplasia and a review of 23 cases. To be published.

Russell, L. W., and Chandler, F. A. Fibrous dysplasia of bone. J. Bone & Joint Surg., 32–A: 323–337, 1950.

Schlumberger, H. G. Fibrous dysplasia of single bones (monostotic fibrous dysplasia). Mil. Surgeon, 99:504–527, 1946.

Valls, J., Polak, M., and Schajowicz, F. Fibrous dysplasia of bone. J. Bone & Joint Surg., 32–A:311–322, 1950.

MISCELLANEOUS LESIONS—BENIGN

Pigmented Villonodular Synovitis

SYNONYMS AND RELATED TERMS: Giant cell tumor of the synovium; hemorrhagic villous synovitis; pigmented giant cell sarcoma; pigmented villous synovitis; sclerosing hemangioma; xanthoma; xanthogranuloma.

"Synovioma" or "benign synovioma" should no longer be used as terms to designate pigmented villonodular synovitis, since they have confused diagnoses and led to unwarranted reports of cures in synovial sarcoma.

DEFINITION. An uncommon lesion characterized by proliferation of synovial lining and connective tissue stratum of the synovium which forms numerous villous projections that may become fused into nodular masses.

CLINICAL DATA. The knee is the predominant joint of involvement of pigmented villonodular synovitis; bilateral involvement of knee joints also has been described (Friedman and Schwartz; Greenfield and Wallace). Of other joints which have been reported as sites of the disease, the hip is perhaps the next most common; in a case reported by Carr and associates, there was retroperitoneal extension of the lesion sufficient to present as an abdominal mass. Small joints of the fingers and ankles and those of the tibio-tarsal and calcaneo-cuboidal joints have been reported as being involved. On rare occasions the lesion has eroded into adjacent bone (Breimer and Freiberger). Even bursae may be involved by a disease process that is grossly similar to pigmented villonodular synovitis of the knee joint.

PATHOGENESIS. Etiology of this entity remains unknown. It is closely related to the giant cell tumor of tendons. Lesions with similar patterns proliferating extensively in soft tissues of the region of the joint space, such as the knee, elbow, or ankle, have also been seen by us. Therefore, this lesion perhaps belongs more properly in the fascicle "Tumors of the Soft Tissues." Though it probably is not a true neoplasm, it is included in our fascicle because it grows in close apposition to bone, proliferates and ramifies within the joint, may secondarily invade bone, and is frequently called malignant (McMaster).

GROSS. The involved joint contains a serosanguineous effusion. If this fluid is secured by aspiration of the joint, a presumptive diagnosis of pigmented villonodular synovitis may be made. While the lesion may be diffuse or circumscribed in its involvement of a joint, both are histologically similar.

In the circumscribed variety, the disease manifests itself as a single nodular outgrowth which usually occurs near the menisco-capsular junction (Jaffe et al.). It is sessile, but may have a short stalk. Discoloration is similar to that of the diffuse type of pigmented villonodular synovitis.

In the diffuse form of the disease, reddish brown fluid frequently is encountered by the surgeon opening the joint; this may contain fibrinous clots. There is usually an accompanying somewhat diffuse reddish brown to yellowish brown discoloration of the synovium which imparts a rusty appearance to the membrane.

Varied terms have been used to describe the gross appearance of the diffuse form of the disease; "mosslike" and "bearded" (fig. 323) are the commoner terms because of the appearance of the villi. They are either elongated and delicate or stubby and nodular; they often become entangled, matted, and flattened. On cut section, the matted portions are spongy, but have a similar

histologic appearance to villous areas. However, because of fusion of villi, synovial-lined clefts are noted in the nodular and matted areas.

The nodular projections may measure up to 2 cm. in diameter, but average between 5 mm. to 1 cm. The larger nodular masses are often attached to a short pedicle. Synovial membrane may be diffusely involved, predominantly in recesses but also at the junction of the meniscus with the synovial membrane.

MICROSCOPIC. The diverse microscopic pattern shows intact, delicate villi covered by synovial lining cells and occasional fibrin (figs. 324, 325). Cores of these villi are composed of delicate vascular connective tissue. Hemosiderin deposits may be found within synovial cells and macrophages or lying free within the connective tissue of the villi. In more nodular masses, stromal proliferation adopts characteristics suggesting neoplasm (Bennett). If this connective tissue proliferation is associated with multinucleated giant cells, it may impart a histologic pattern suggesting giant cell tumor. However, many lesions of joints may contain occasional multinucleated giant cells and therefore should not be categorized as pigmented villonodular synovitis on this finding alone. Macrophages which have finely vacuolated cytoplasm may be mixed with stroma and multinucleated giant cells, may be seen in groups, or may appear singly in other portions of the lesion. A mixture of plasma cells and lymphocytes is often seen.

In foci that have presumably undergone trauma with extravasation of blood, hyalinization has occurred as an end stage of healing of such areas. Consequently it is often seen in larger masses of the lesion. Most areas of the lesion which have not undergone hyalinization remain quite vascular.

TREATMENT. Excision of the involved synovial membrane is accepted treatment. If excision is incomplete, the lesion may recur. In lesions that cannot be completely excised, radiation therapy has offered good results (Shafer and Larmon; Friedman and Schwartz). There are no known instances in which malignant transformation of this lesion has occurred.

An entity which is believed to be an earlier phase of pigmented villonodular synovitis also has been described (Bennett). This is known as **pigmented villous synovitis.** It is grossly characterized by the "mosslike" configuration formed by hypertrophied villi, has nodules and a small amount of red-brown effusion, and has a color similar to that of pigmented villonodular synovitis.

Synovial Osteochondromatosis

SYNONYMS AND RELATED TERMS: Chondromatosis; diffuse enchondroma of the joint capsule; joint chondromata; osteochondromatosis; synovial chondroma.

DEFINITION. A benign infrequent lesion of synovium characterized by multiple osteochondromatous and synovial "loose bodies," and most commonly affecting knee and elbow joints, bursae, and tendon sheaths.

CLINICAL DATA. Duration of symptoms usually averages eight years (Mussey and Henderson). Aching, weakness, and progressive limitation of

motion of the affected joint are major symptoms, while effusions are usually not of consequence. The disease is more common in men than women.

PATHOGENESIS. Trauma to the affected joint, inflammatory diseases, cartilaginous rests, metaplasia, and neoplasia have been suggested as explanations for the pathogenesis of osteochondromatosis; consequently, the problem remains unsettled. Metaplasia and neoplasia are favored on a histologic basis, i.e. evident transformation of synovial tissue into cartilage.

SITES OF TUMOR. In addition to knee and elbow joints, temporomandibular, metacarpophalangeal, interphalangeal, wrist, shoulder, hip, and ankle joints may be affected. However, multiple involvement of these joints is unusual; only 10 of the 104 patients of Mussey and Henderson had bilateral joint involvement, and these were of the knees and elbows only; roentgenographic evidence of osteoarthritis also was present in one half of their 104 cases. Collins has observed further that a joint containing "loose bodies" will almost certainly develop osteoarthritis.

GROSS. Increased vascularity may produce a hyperemic synovium. The synovium may also be thickened by villous projections, particularly in areas occupied by "loose bodies" (figs. 326, 327). Most of these bodies are found in the posterior pouch of the knee; others may be found in the suprapatellar bursa or other recesses of the joint cavity (Wilmoth). In rare instances, "loose bodies" break through the joint capsule and continue to proliferate (Freund); they are white, round or ovoid, cartilaginous nodules with smooth, roughened, or faceted surfaces. While their sizes may vary greatly, they are usually 1 cm. or less in diameter. As many as 1,047 "loose bodies" have been produced in one joint (Fisher). Cases included in the study of Mussey and Henderson had four or more of these, unless they apparently were secondary to trauma.

Not all cartilaginous nodules become "loose bodies"; some remain attached by a pedicle to the synovium, while others are embedded in it; the latter may be of minute size. It is felt that these bodies mature in the synovium and either are extruded or become detached from their pedicles to assume the role of "loose bodies" (Collins, 1950).

MICROSCOPIC. Those bodies embedded in or attached to synovium may be either completely cartilaginous or partly bone. Their calcification is common; the "loose bodies" may be completely ossified except for a cartilaginous covering. Cells of proliferating cartilage may be sufficiently abnormal to result in misinterpretation as chondrosarcoma. Because such a case was referred to us, discussion of the lesion was included in this fascicle (figs. 328–331).

TREATMENT. Results are good from removal of all available bodies and synovectomy (Leydig and Odell). No known malignant transformation of osteochondromatosis has occurred; in fact, it has been demonstrated by roentgenograms that spontaneous regression may follow even incomplete

removal of the bodies, or they may recur. Separate "loose bodies" also have been noted by roentgenograms (Freund) to fuse into one.

Myositis Ossificans

SYNONYMS AND RELATED TERMS: Extraosseous localized non-neoplastic bone and cartilage formation.

DEFINITION. Myositis ossificans is a term loosely applied to a group of conditions. The term is a misnomer, for not only does "myositis" imply inflammation (which is lacking) of muscle (which also may be lacking), but early in its evolution there also is no bone in the lesion to satisfy the connotation of "ossificans"; finally, the lesion may not even be connected with the bone.

CLINICAL DATA. The condition usually occurs in healthy, vigorous young men. Periosteum is not necessary to production of the lesion.

PATHOGENESIS. It is possible, but as yet unproved, that the initial change is damage to muscle. Although we find no evidence of recent or old hemorrhage, about one half of the cases of myositis ossificans will have had a previous history of trauma.

Lewis (1923, p. 1282) cited the 127 cases of traumatic myositis ossificans of Strauss as showing the following anatomic distribution: "sixty-four of these occurred in the flexor muscles of the upper arm, the brachialis anticus being the one most frequently affected; forty-three occurred in the quadriceps femoris; thirteen, in the adductor muscles of the thigh; two, in the gluteal muscles; one, in the muscles of the ball of the thumb, and one, in the temporal muscle." The lesion may grow to considerable size, especially when it occurs in the buttock. The clinician must be alerted to this possibility, particularly in young adults; myositis ossificans should be considered when the lesion is in close association with periosteum, or in soft tissue.

GROSS. Appearance of these lesions varies with their evolution (figs. 336–339). Ossification usually is not present in the first two weeks, nor are zones of old or recent hemorrhage evident. In biopsied or excised material the process is invariably well established. Frequently no muscle is included within the actual lesion; a zone of demarcation with good capsule may prevail. In some lesions of the buttock, no connection to bone has been noted (figs. 334, 335). In the region of the thigh and elbow, however, periosteum undoubtedly is involved. To cite a case: after initial demonstration of the lesion in a 15-year-old boy, a roentgenogram taken at the fifth week showed a "dotted-veil" appearance. This seemed so characteristic to the radiologist and surgeon that no biopsy was taken and no treatment was given. Two years later, the soft tissue lesion had disappeared, but there was a zone of periosteal thickening (figs. 332, 333).

MICROSCOPIC. Diagnosis of myositis ossificans is difficult to make from microscopic findings unless normal evolution of this lesion is known. Establishment of zone phenomena (fig. 340) simplifies our understanding of the process, however. The undifferentiated pattern of early evolution of the lesions (fig.

349), perhaps the first 10 days in our cases, is extremely difficult to diagnose; however, zone phenomena later develop and enable diagnosis to be made. The central area of this phenomenon shows a highly cellular zone, with atypical mitotic figures and great variation in size and shape of cells; this resembles an undifferentiated sarcoma (fig. 341). Toward the periphery, organization of the tissue begins to produce a regularity of pattern with poorly defined osteoid tissue (figs. 342, 346, 348); infrequently cartilage is present also in these lesions (fig. 347). In the margins of the lesion, there is well formed bone covered with a connective tissue capsule (figs. 343, 347).

A case in point is that of a 15-year-old girl who had had a soft tissue mass of the abdominal wall of unknown duration. This lesion clinically was thought to be a soft tissue sarcoma until incipient osteoid and good orientation of the process (fig. 348) were noted microscopically. Therefore no treatment was given, and the patient was still well 15 months later.

When further time has lapsed, if the lesion is located in the region of the knee joint, the process is partly reabsorbed and the lesion becomes smaller; it may even develop a cartilaginous cap to resemble an osteochondroma. Such lesions have been designated as post-traumatic osteochondromas. Myositis ossificans does not become osteosarcoma. However, extraosseous osteosarcoma exists. In this rare entity, a malignant microscopic pattern prevails throughout the entire lesion; there are no evidences of zone phenomena or maturation (Fine and Stout).

Some lesions of osteosarcoma of parosteal type also have been confused with myositis ossificans.

TREATMENT. The necessity of biopsy or excision of this benign lesion can be evaluated correctly only when the pathologist knows the history, location, and duration of the process. When this background was lacking, unnecessary amputation occurred in several instances. In some instances, when the lesion was recognized by roentgenogram and biopsy, no treatment was given. If the lesion is excised early in its evolution, it may recur. Sequential radiographs may be helpful in demonstrating maturation of the process (figs. 336–339).

PROGNOSIS. Excellent prognosis is expected with conservative treatment.

DIFFERENTIAL DIAGNOSIS. Included in this entity are lesions in which periosteum apparently plays an important role; there are other lesions occurring close to bone, however, in which periosteum is not involved. These lesions have been confused radiographically and pathologically with malignant tumors of bone and soft tissues. However, myositis ossificans, as discussed in this section, is not related to the rare disease myositis ossificans progressiva; therefore these two entities should not be confused (Grewal and Das).

A number of these lesions in atypical locations have been confused with extraosseous osteosarcoma, or possibly with extensions of primary osteosarcoma of bone into the soft tissues. Grossly these latter lesions were fairly well de-

limited, however, and by roentgenogram showed evidence of bone around their peripheral margins (fig. 335).

Eosinophilic Granuloma

DEFINITION. A benign, non-neoplastic, solitary, lytic lesion producing various radiographic patterns and probably arising from the reticuloendothelial system.

CLINICAL DATA. Lesions are noted when local symptoms of pain, swelling, and pathologic fracture appear, the latter uncommonly.

This lesion of benign evolution occurs from infancy to the sixth decade. Peak incidence, however, is between the ages of 5 and 10 years, with most cases appearing before the age of 30 years. Men are slightly more frequently afflicted than women.

Radiographically, in long bones this lesion usually appears as a mottled lytic defect in the medulla; it encroaches on the cortex, and if of sufficient size, may destroy it and induce periosteal new bone formation (fig. 353) to confuse it with Ewing's tumor or osteomyelitis. However, in the skull and mandible, these latter lesions are more sharply defined, and produce a "punched-out" type defect.

Laboratory data are normal.

PATHOGENESIS. Unknown pathogenesis has led to classification of eosinophilic granuloma of bone by some as a member of the nonlipid reticuloendothelial proliferative disorders (Letterer-Siwe disease and Hand-Schüller-Christian disease). Reasons for this grouping apparently are arbitrary, for we have not found data suggesting such a relationship in our 28 cases; nor are we convinced by the material presented by proponents of this theory. Otani's concepts, to us, are the most acceptable to date.

SITES OF TUMOR. Most frequent sites of involvement by the lesion are frontal and parietal bones, mandible, humerus, ribs, and proximal metaphysis of the femur; we have also seen cases in which the only bones involved were maxilla, clavicle, scapula, sternum, ilium, fibula, and tibia.

GROSS. Tissue removed by curettage is soft, and pink to yellow, or may be focally hemorrhagic. The few intact lesions, excised from the skull and seen by us, had similar gross features.

MICROSCOPIC. Most predominant cellular constituent of the lesion is a moderately sized reticulum cell; this contains a round or oval vesicular nucleus, a small centrally placed amphophilic nucleolus, and a varying amount of slightly granular eosinophilic cytoplasm. Multinucleated giant cells, probably derived from these reticulum cells, are present in varying numbers and are occasionally phagocytic (figs. 352, 354, 355). In the background, eosinophilic and neutrophilic leukocytes, lymphocytes, and plasma cells are seen. Their frequency is usually in the order listed, although some lesions have areas in

which eosinophilic leukocytes are scant. Foci of necrosis and hemorrhage also are seen.

A few sudanophilic cells may be found; these are usually related to areas of necrosis and are not the foam cells of Hand-Schüller-Christian disease. In the latter disease, biopsy of a bone lesion is not often submitted, but clinical and radiographic findings are usually sufficiently distinctive for a correct diagnosis to be made. Disseminated lesions usually are seen only at post-mortem examination.

TREATMENT. Varying forms of therapy, such as biopsy, curettage, and homeopathic doses of roentgen ray, have yielded equally satisfactory results, with gradual and complete resolution of the lesion (figs. 350, 351).

Giant Cell Reaction

DEFINITION. A rare, benign, non-neoplastic, single lesion involving small bones of the hands.

PATHOGENESIS. Even though the pathogenesis of this lesion is not known, we do not believe it is related to giant cell tumor of tendon sheath origin; neither does objective evidence of its relationship to trauma exist. The lesion is discussed here only because it is one of the group of lesions which may be confused with malignant tumors.

MICROSCOPIC. Although the biopsies and curetted material seen by us have been nondiagnostic grossly, microscopically this material is composed of giant cells with prominent proliferation of osteoid (figs. 358, 359); it is this pattern which may be confused with that of malignant tumors.

TREATMENT. Of the two lesions we have seen, one was in a terminal phalanx and was resected; the other, which was in a middle phalanx, was curetted and replaced by bone chips. Evidence of the lesion may persist for six months after treatment, or extensions of such lesions through the cortex and into soft tissue are even possible (figs. 356, 357).

Giant Cell Tumor—Tendon Sheath Origin

NATURAL HISTORY. The majority of so-called giant cell tumors of tendon sheath origin are benign; only in rare instances do they undergo apparent malignant transformation. In a review of literature pertinent to a transition, Lichtenstein (1955) uncovered only one acceptable case and a second possible but somewhat dubious case. In the latter case reported by Kobak and Perlow, a mass was present in the peritendinous portion of the triceps muscle; this was interpreted as a giant cell tumor. During its course of one and one-half years, it metastasized to the lymph nodes, lungs, and other viscera. Review of photomicrographs of this case suggests, however, that the first biopsy was histologically malignant; some doubt exists, therefore, whether this lesion originated as a benign tumor. A more acceptable case reported by Decker and Owen

concerns a lesion involving tendons of the tibialis posticus and flexor hallucis longus in a 32-year-old woman. The lesion was known to have been present for 14 years. Roentgenogram, on patient's first hospital admission, revealed no bony involvement, but subsequent films showed progressive changes in local bone. During this time, there also had been four operations, including final amputation; six months prior to amputation, however, destructive lesions had been demonstrated in the 6th and 7th ribs, and a left hilar lung mass was also present. In the amputated specimen, tumor was found in the 1st and 2nd cuneiform bones. It had eroded through the tarsal bones to involve the navicular and cuboidal bones.

CLINICAL DATA. Clinical and pathologic aspects of giant cell tumor of tendon sheath origin are well known. Not universally realized, however, is the fact that these lesions may cause defects in adjacent bone, even though uncommonly. For this reason, they become of clinical significance in considering differentiation from erosive or cystic radiographic defects of bones, particularly of hands or feet (figs. 360–362).

In a review of 43 giant cell tumors of tendon sheath origin, Fletcher and Horn were able to demonstrate bony changes in 8 of these; 6 of these exhibited local erosion of adjacent bone, and 2 exhibited quite extensive destruction.

Litwer also reported two cases with erosion and cystic change in bones of the little finger. In one of these patients, biopsy was misinterpreted as a malignant tumor, and amputation was performed. Diagnosis from the amputated specimen was made as pigmented nodular tenosynovitis. Radiographically, the second patient had cystic areas in the base of the middle phalanx of the little finger. A large mass, also diagnosed as pigmented nodular tenosynovitis, was incompletely removed.

Personal experience has included cases of giant cell tumor of tendon sheath origin with erosion of adjacent bones in fingers and feet.

TREATMENT. Conservative surgical excision usually suffices as adequate treatment, since only in the rarest of circumstances does this lesion undergo malignant transformation. If these lesions are not completely removed, they may recur locally. Recurrence rate has been recorded as ranging between 12 and 16 percent.

References

Ackerman, L. V. Extra-osseous localized non-neoplastic bone and cartilage formation (so-called myositis ossificans). Clinical and pathological confusion with malignant neoplasms. J. Bone & Joint Surg., 40–A:279–298, 1958.

Bennett, G. A. Reactive and neoplastic changes in synovial tissues. (Richard Hermann Jaffé memorial lecture). Proc. Inst. Med. Chicago, 18:26–37, 1950.

Brashear, H. R. Pigmented villonodular synovitis. South. M.J., 49:679–684, 1956.

Breimer, C. W., and Freiberger, R. H. Bone lesions associated with villonodular synovitis. Am. J. Roentgenol., 79:618–629, 1958.

INVASIVE TUMORS

(Figures 271–273 are from the same case*)

Figure 271. Roentgenogram of a ring finger of a patient with a glomus tumor of the distal phalanx. Smooth erosin of the bone is observed. A. F. I. P. Acc. No. 218757–264.

Figure 272. Photomicrograph of the tumor removed from the distal phalanx corresponds in contour with the defect seen in the bone. Hematoxylin and eosin stain. X 20. W.U. 57–6086; A. F. I. P. Acc. No. 218757–265.

Figure 273. Higher power view of a section of this tumor illustrates its histologic characteristics. Hematoxylin and eosin stain. X 250. W.U. 57–6085; A. F. I. P. Acc. No. 218757–266.

---

*Courtesy of Dr. J. L. Posch and Dr. M. W. Wilson, Detroit, Mich.

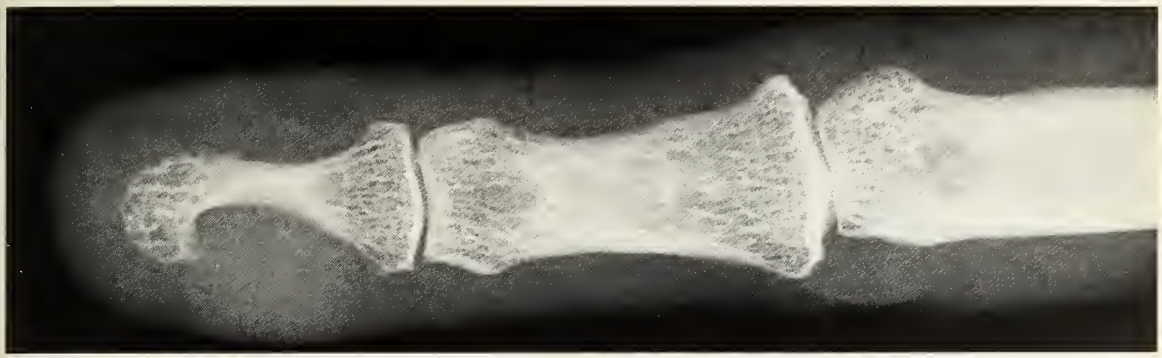

Fig. 271

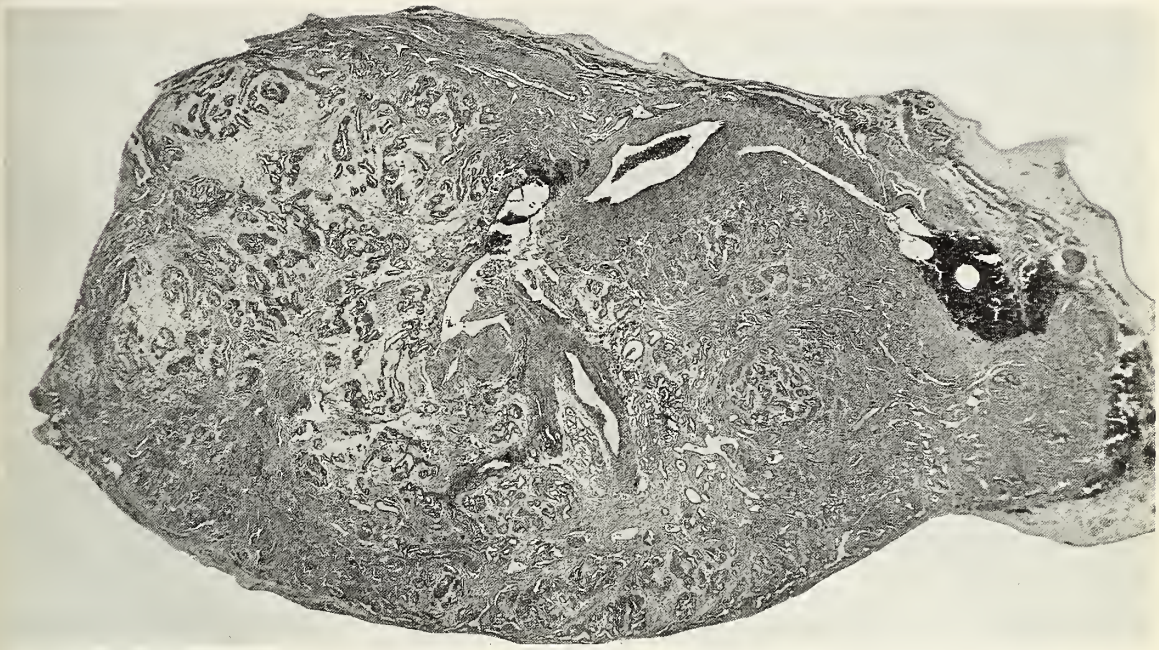

Fig. 272

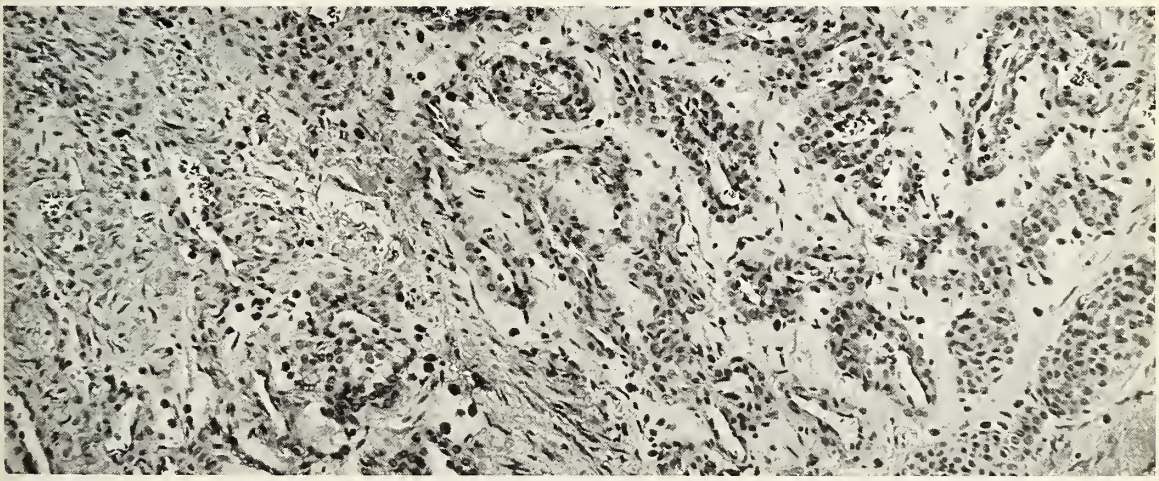

Fig. 273

INVASIVE TUMORS

Figure 274. The roentgenogram illustrates smooth erosion of the cortex of the diaphysis of a fibula and tibia. This occurred secondarily to a liposarcoma arising in soft tissues of the calf of the leg of a 53-year-old man. The area had been enlarging gradually over a period of two years. Diagnosis was confirmed by biopsy. W.U. 58–1567; A. F. I. P. Acc. No. 218757–267.

Figure 275. Sagittal section of a large epidermoid carcinoma involving the soft tissues and distal portion of an amputated femur. Note extensive destruction of portions of the femur and hemorrhagic necrosis in the tumor.

This patient had sustained injury to the left leg 32 years prior to amputation. During those years he had had an osteomyelitis with a chronically draining sinus in the area. Biopsy of the sinus tract had revealed an epidermoid carcinoma infiltrating bone. W.U. 53–35; A. F. I. P. Acc. No. 218757–268.

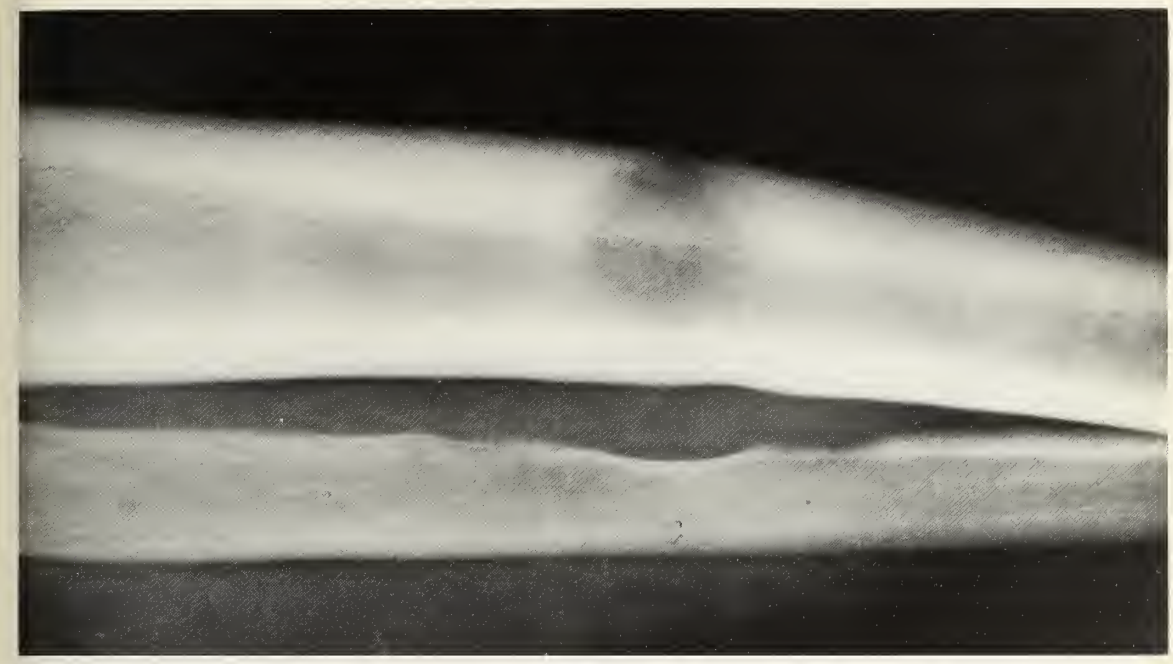

Fig. 274

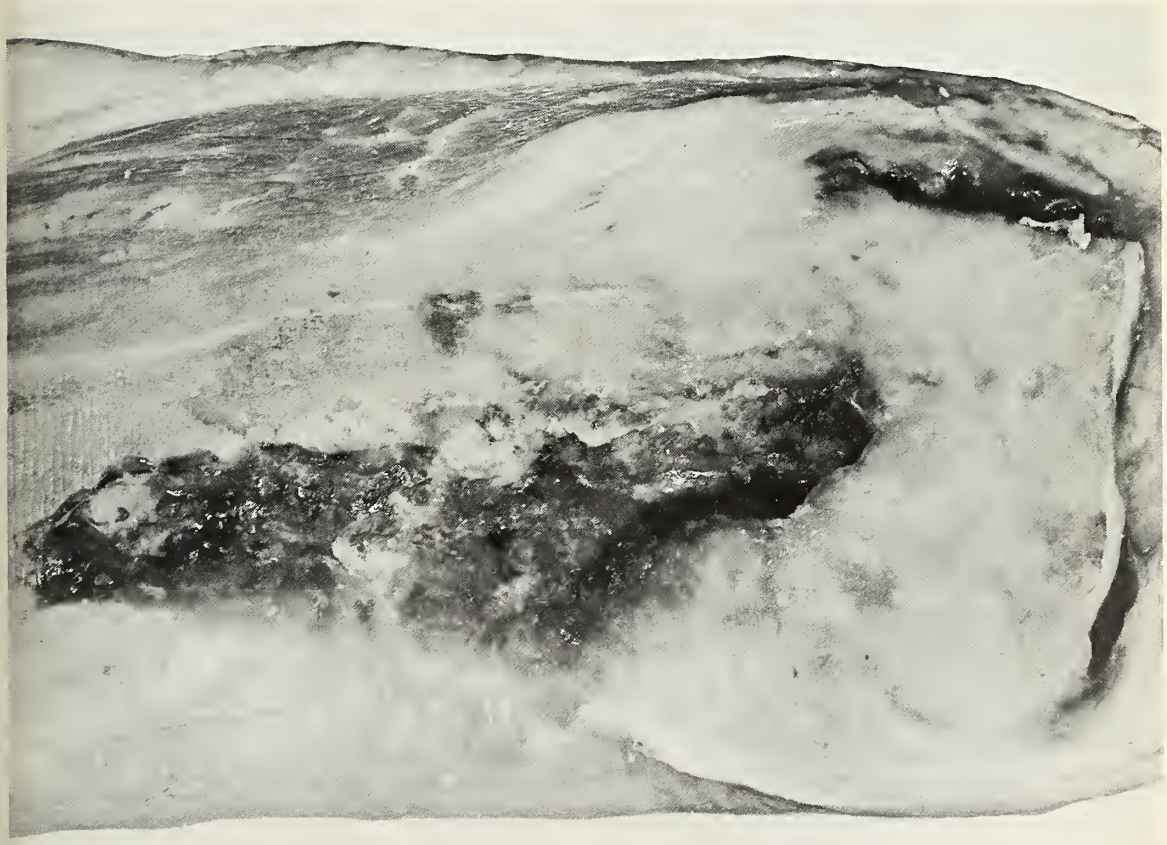

Fig. 275

METASTATIC TUMORS

Figure 276. Roentgenogram illustrating extensive destruction of the distal portion of a tibia and fibula and a portion of the os calcis. This lesion represented a metastatic carcinoma with the primary in the breast. W.U. 58–1571; A. F. I. P. Acc. No. 218757–269.

Figure 277. Classic pattern of carcinoma metastatic from the prostate is shown in the roentgenogram. Extreme sclerotic changes in the pelvic bone, femoral head, sacrum, and vertebrae are evident. W.U. 58–1572; A. F. I. P. Acc. No. 218757–270.

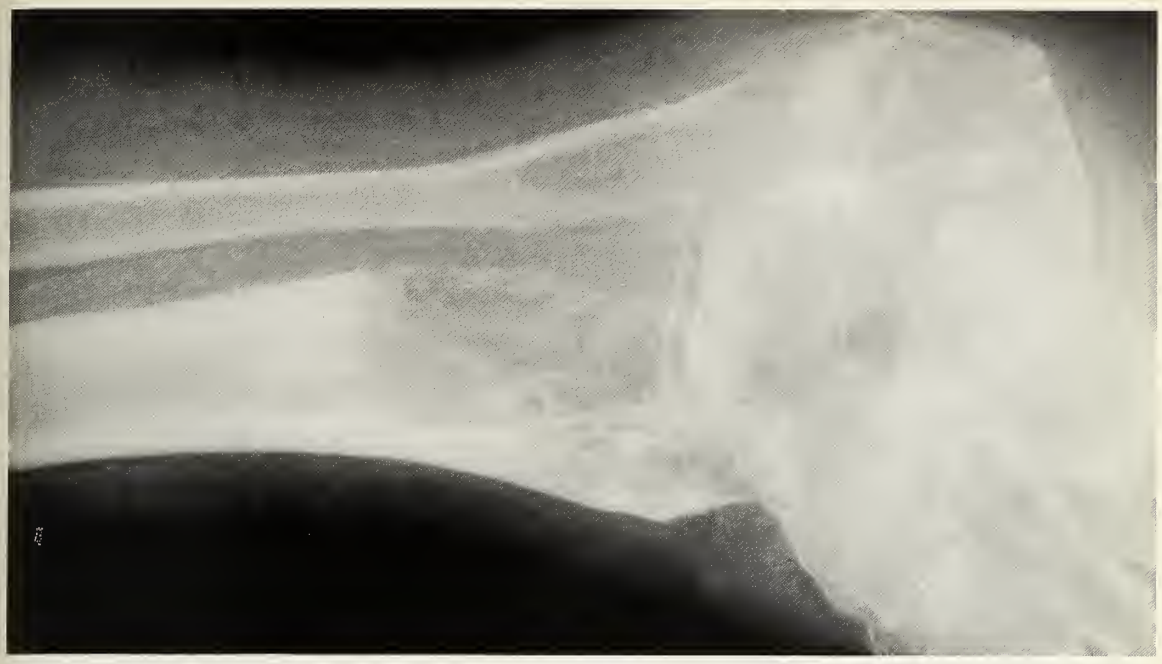

Fig. 276

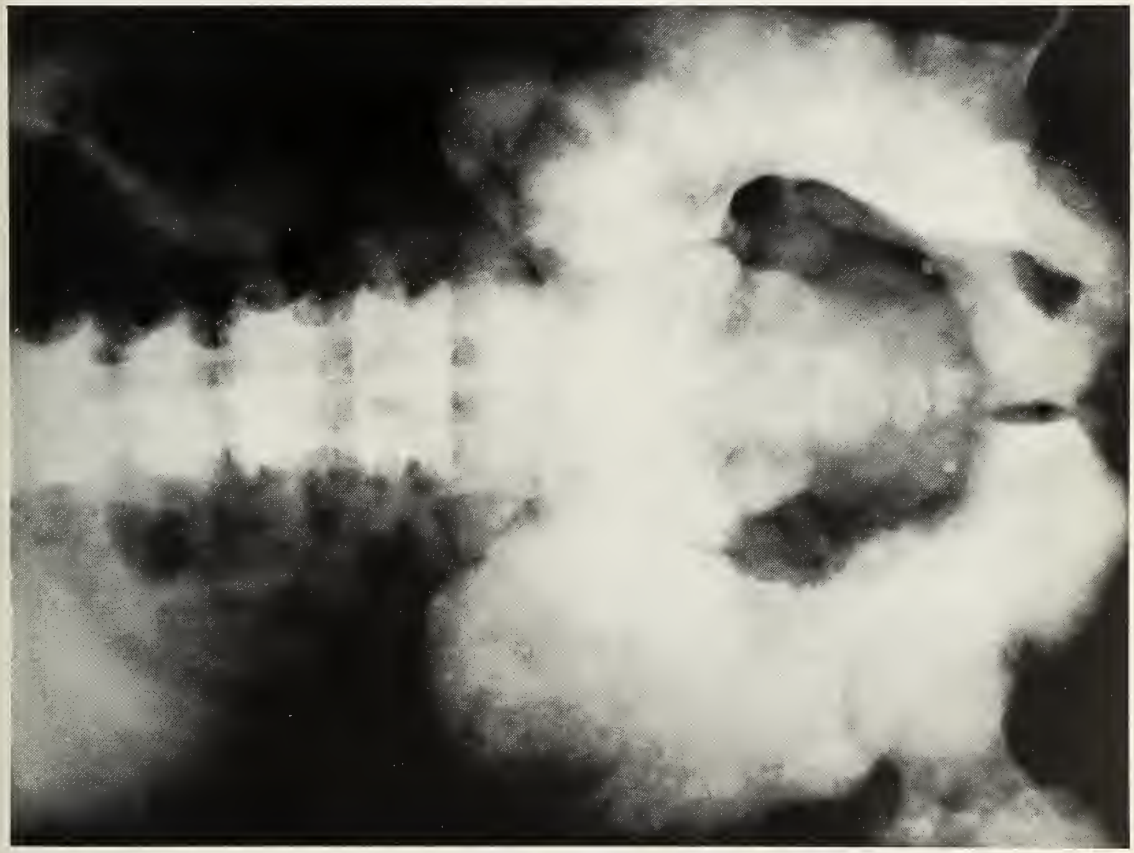

Fig. 277

METASTATIC TUMORS

Figure 278. This roentgenogram represents involvement of vertebrae by Hodgkin's disease and presents an isolated osteoblastic lesion. Of the lymphomas, Hodgkin's disease is most likely to cause osteoblastic metastases. W.U. 58–1563; A. F. I. P. Acc. No. 218757–277.

Figure 279. Area of rarefaction in the medullary portion of the distal end of a tibia. In the roentgenogram, note the erosion and partial obliteration of cortex and simulated subperiosteal bone formation. This lesion was secondary to an epidermoid carcinoma of the uterine cervix. The patient, a 49-year-old Negro woman, had been treated for carcinoma of the cervix one year prior to discovery of the tibial lesion. W.U. 54–79; A. F. I. P. Acc. No. 218757–271.

Figure 280. Hemisection of a carcinoma metastatic from the thyroid to the left humerus of a 72-year-old woman. By roentgenographic examination, a destructive lesion of the humerus is known to have been present for two years. Clinically, pulsation was perceptible over the mass. Subsequent to amputation, a thyroid carcinoma was removed. It was histologically similar to that in the humerus. W.U. 58–5488; A. F. I. P. Acc. No. 218757–368.

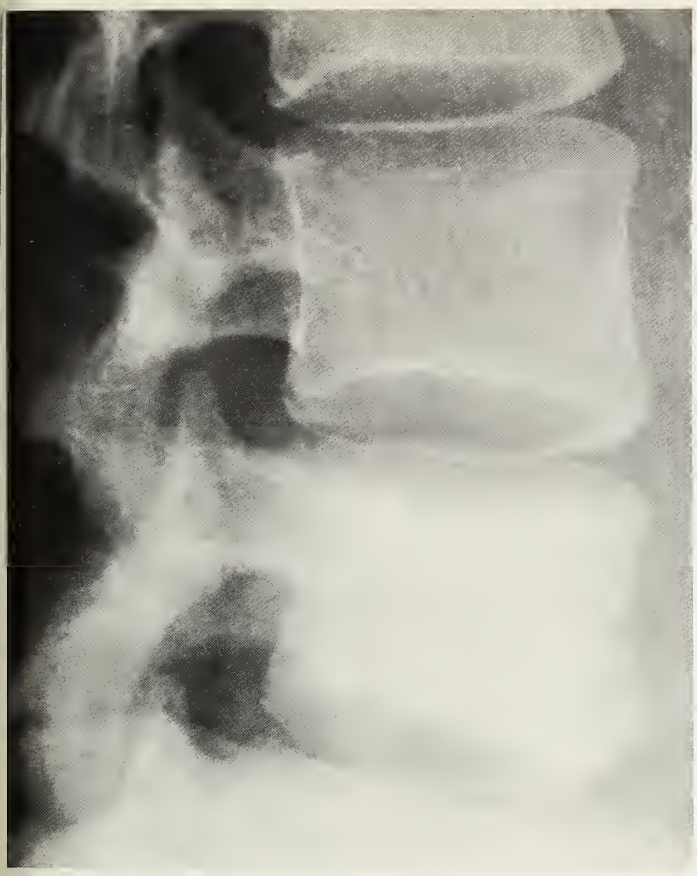

Fig. 278

Fig. 279

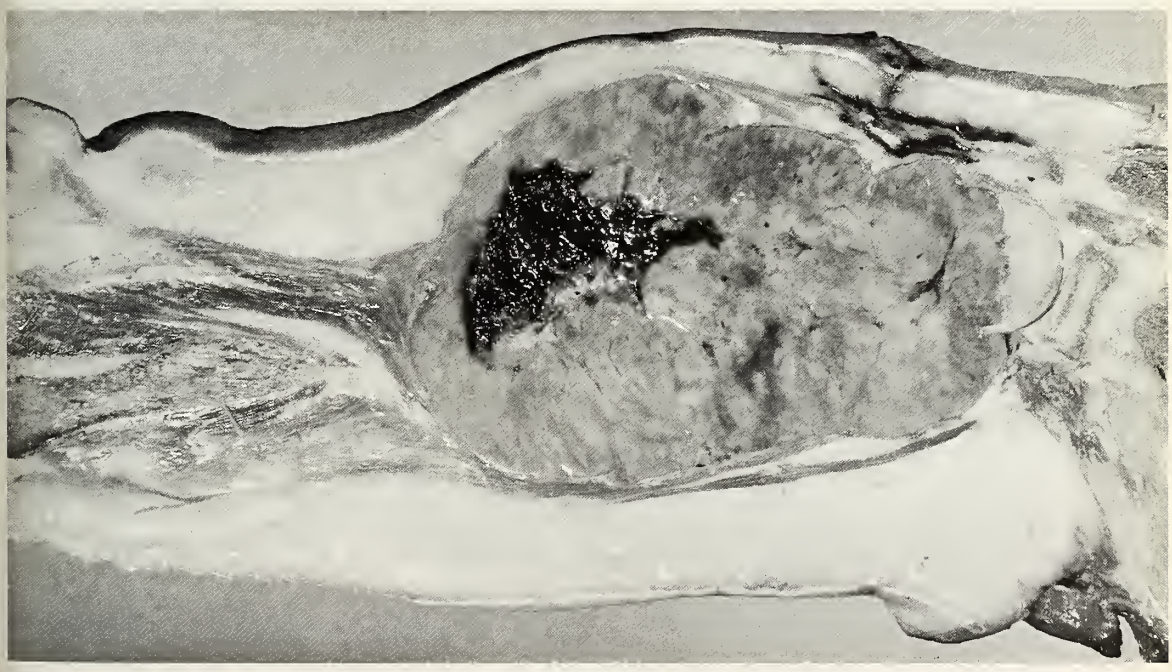

Fig. 280

METASTATIC TUMORS

(Figures 281 and 282 are from the same case. Figures 283 and 284 are from the same case*)

Figure 281. Femur exhibiting subperiosteal bone formation and homogeneous-appearing medulla of the bone secondary to a ganglioneuroblastoma. That discrete destructive lesions are not seen in this roentgenogram would suggest diffuse permeation of the medullary cavity by metastatic tumor. W.U. 58–693; A. F. I. P. Acc. No. 218757–273.

Figure 282. Photomicrograph of the primary tumor that gave rise to these metastases. The patient was a 3-year-old boy who had had a 1-year history of fever, joint pain, and weakness. Roentgenographic examination of the abdomen had previously revealed a large partly calcified mass superior to the right kidney. Skeletal survey revealed metastatic tumor in many bones. Hematoxylin and eosin stain. X 530. A. F. I. P. Acc. No. 218757–68.

Figure 283. This lesion represents a metastatic so-called lympho-epithelioma from the nasopharynx of a 5-year-old child. Note that the tumor has caused bone production as well as a central area of bone destruction. These roentgenographic findings are compatible with a diagnosis of eosinophilic granuloma, Ewing's sarcoma, or even osteoblastoma. A. F. I. P. Acc. No. 218757–274.

Figure 284. Photomicrograph of a representative field of the biopsy from this lesion. Hematoxylin and eosin stain. X 395. A. F. I. P. Acc. No. 218757–54.

---

*Courtesy of Dr. D. C. Dahlin, Rochester, Minn.

Fig. 281

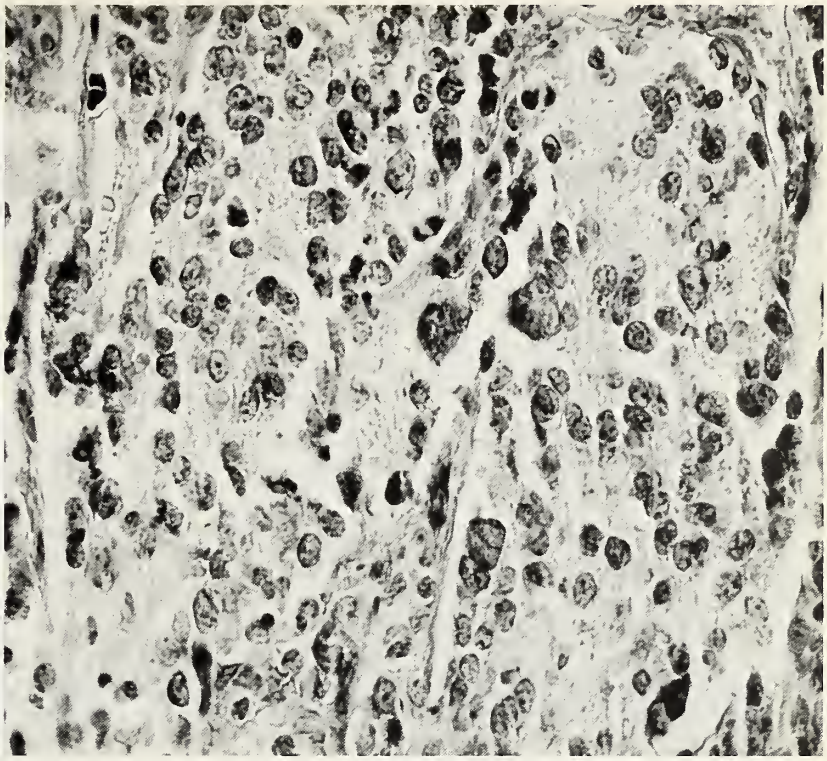

Fig. 282

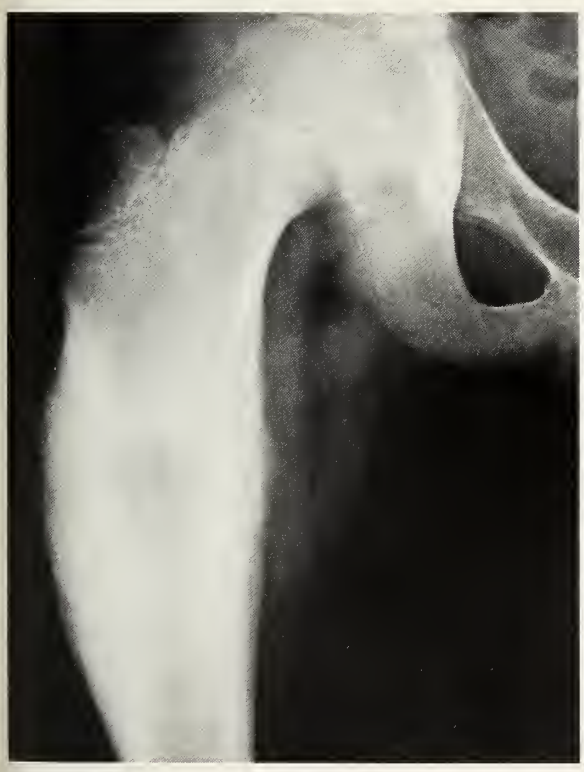

Fig. 283

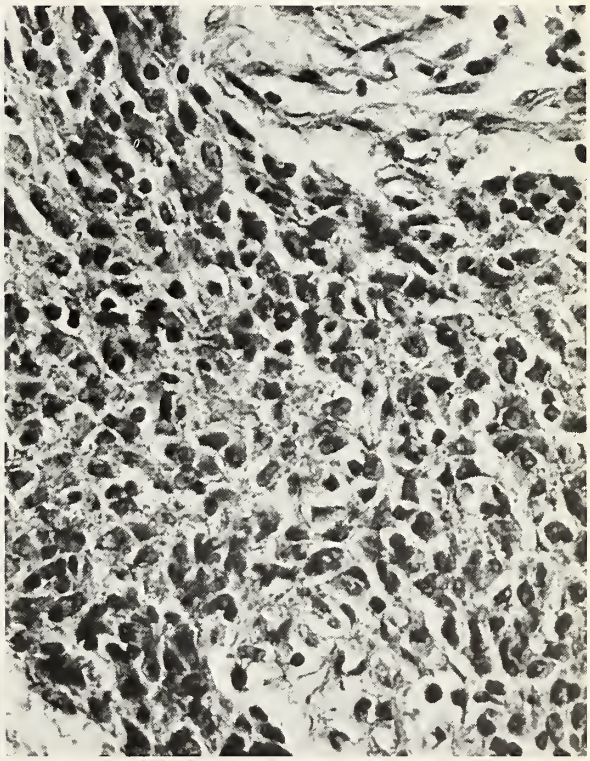

Fig. 284

METASTATIC TUMORS

(Figures 285 and 286 are from the same case)

Figure 285. Roentgenographically, there are many features of an aneurysmal bone cyst, but the original interpretation was giant cell tumor. The lesion proved to be metastatic carcinoma with the primary in the thyroid. W.U. 57–4396; A. F. I. P. Acc. No. 218757–275.

Figure 286. Photomicrograph of a representative field from the biopsy of this lesion shows a follicular carcinoma metastatic from thyroid. The patient was a 41-year-old woman who had complained of low back pain and right hip pain for 10 years. Hematoxylin and eosin stain. X 660. B.H. 53–2805; A. F. I. P. Acc. No. 218757–276.

Fig. 285

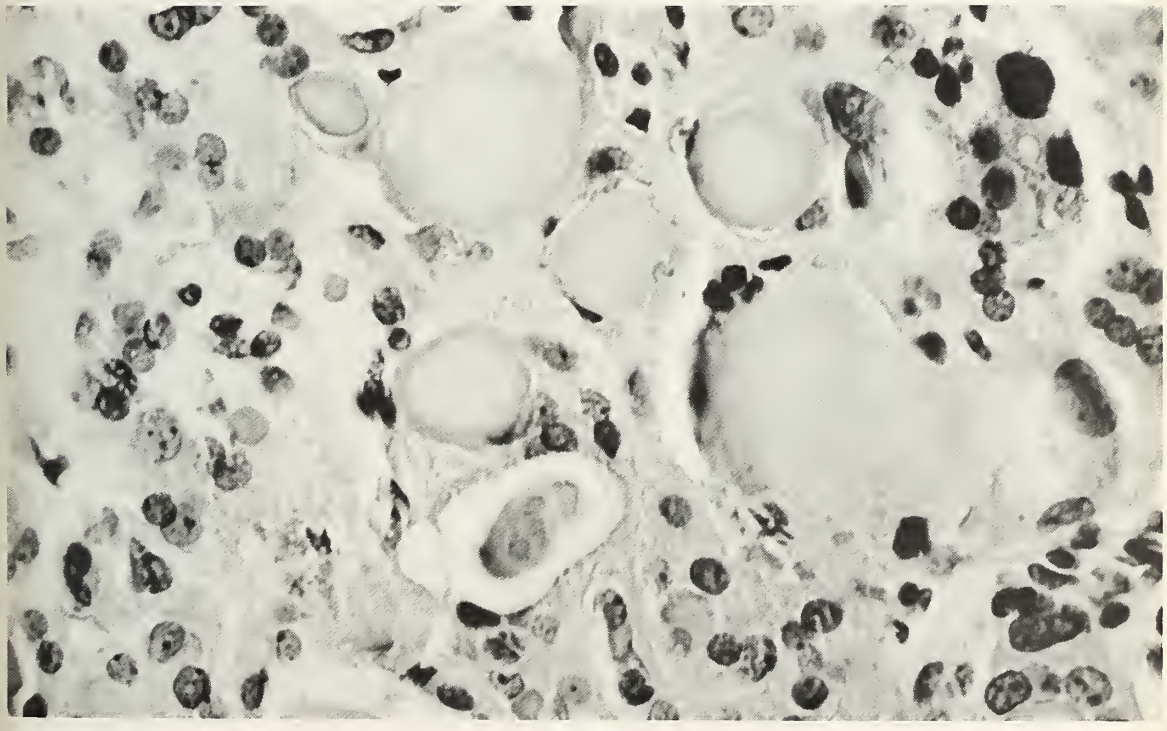

Fig. 286

SOLITARY UNICAMERAL BONE CYST

(Figures 287 and 288 are from the same case)

Figure 287. Solitary unicameral bone cyst in the proximal portion of the humerus of a 7-year-old girl. There previously had been two fractures of bone through this cyst. The roentgenogram shows close proximity of the cyst to the epiphysis and expansion of the bone in the area of the latest fracture. W.U. 58–198; A. F. I. P. Acc. No. 218757–278.

Figure 288. Roentgenogram of the untreated fracture four months later. The outstanding feature is a change in the relationship of the cyst and the epiphysis. W.U. 58–199; A. F. I. P. Acc. No. 218757–279.

Figure 289. This photograph illustrates a "roof" of a unicameral bone cyst. The attenuated cortex and an irregular peninsula of bone extending into the cyst cavity are seen. W.U. 55–4661; A. F. I. P. Acc. No. 218757–280.

Figure 290. In the photomicrograph, note the thin fibrous lining of a solitary unicameral bone cyst. Adjacent cortical bone is not remarkable. Hematoxylin and eosin stain. X 65. B.H. 54–1176; A. F. I. P. Acc. No. 218757–281.

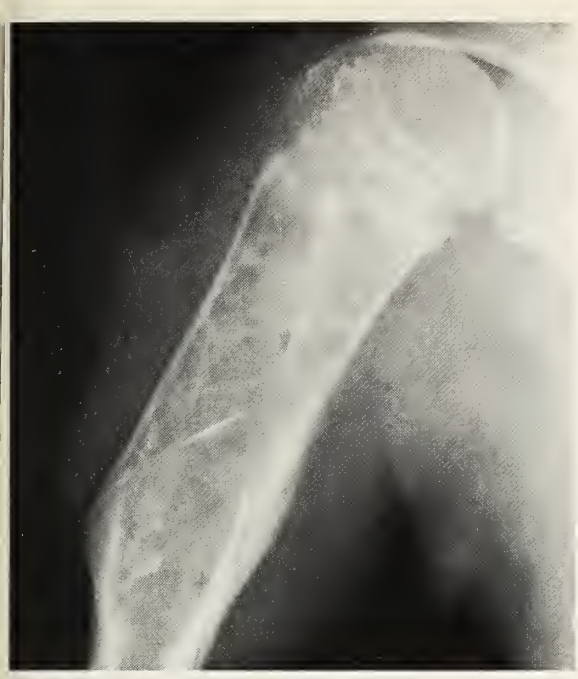

Fig. 287

Fig. 288



Fig. 289

Fig. 290

SOLITARY UNICAMERAL BONE CYST

(Figures 293 and 294 are from the same case)

Figure 291. This cyst lining shows osteoid formation with fibrous tissue, a finding which may lead to misinterpretation as an aneurysmal bone cyst. Inflammatory cells and red blood cells are also seen in the photomicrograph. Hematoxylin and eosin stain. X 100. B.H. 57–2609; A. F. I. P. Acc. No. 218757–282.

Figure 292. Photomicrograph demonstrating histologic variations seen in the wall of a unicameral bone cyst. The surface lining is composed of granulation tissue beneath which is noted a homogeneous hyaline material. In some areas this material has characteristics of osteoid, a type of change commonly seen in unicameral bone cyst. Occasional multinucleated giant cells also may be seen. Hematoxylin and eosin stain. X 85. B.H. 68394; A. F. I. P. Acc. No. 218757–283.

Figure 293. A unicameral bone cyst of a femur of a 9-year-old boy had been treated by curettage and insertion of bone chips 18 months previously. Symptoms recurred, and this roentgenogram demonstrates the recurrent bone cyst. W.U. 57–5481; A. F. I. P. Acc. No. 218757–284.

Figure 294. Histologic section of the material from the most recent curettage shows the thin fibrous lining membrane of the cyst and remnants of bone chips around which there is appositional bone formation. The bone chips are those placed at the time of the first curettage. Hematoxylin and eosin stain. X 85. W.U. 57–6692; A. F. I. P. Acc. No. 218757–285.

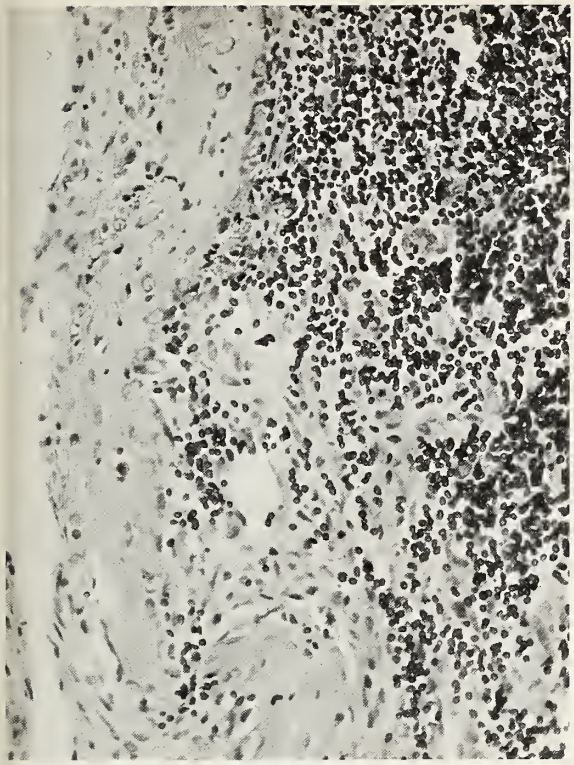

Fig. 291

Fig. 292

Fig. 293

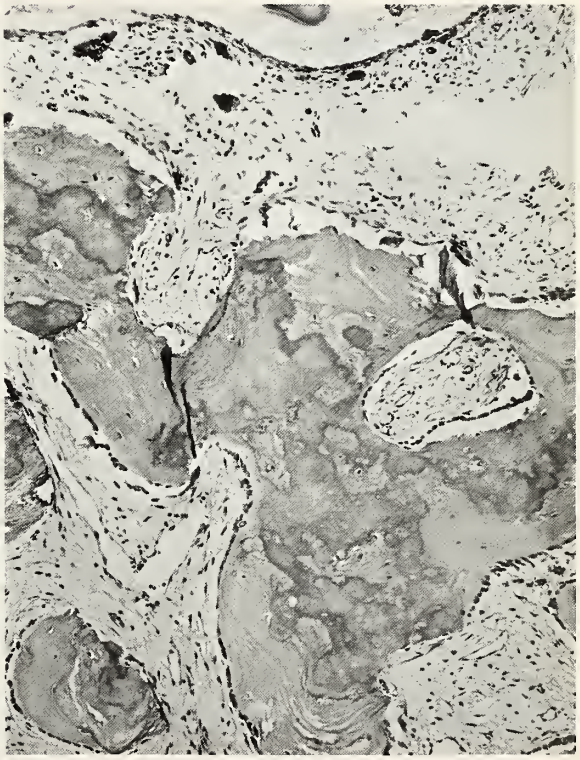

Fig. 294

ANEURYSMAL BONE CYST

(Figures 295 and 296 are from the same case)

Figure 295. Clinical photograph of an aneurysmal bone cyst of the right knee of a 33-year-old man. Note edema and enlargement of the knee in the region of the cyst. W.U. 46–2580; A. F. I. P. Acc. No. 218757–286.

Figure 296. Hemisection of the amputated specimen revealed the typically expanded aneurysmal bone cyst with hemorrhagic and cystic surfaces. The cystic area corresponds to the "soap bubble" effect seen on roentgenograms. Amputation had been performed when clinical and roentgenographic diagnosis suggested a malignant tumor. W.U. 47–46; A. F. I. P. Acc. No. 218757–287.

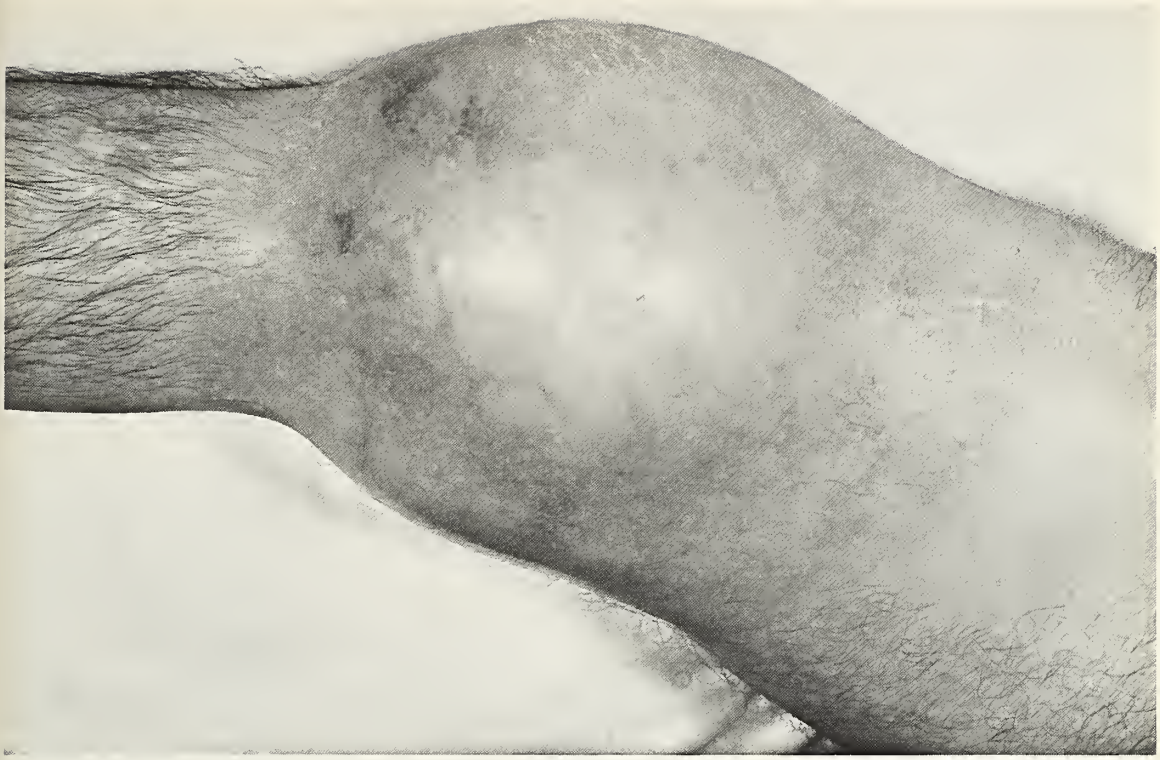

Fig. 295

Fig. 296

ANEURYSMAL BONE CYST

Figure 297. Sagittal section through a specimen amputated from a 10-year-old girl who had complained of pain in the left thigh for three months. Clinical diagnosis of "probably malignant tumor" was made, but biopsy was interpreted as "benign lesion, probably bone cyst." The pathologic diagnosis was doubted and amputation was performed. The specimen demonstrates the typically eccentric location of an aneurysmal bone cyst with destruction of the proximal portion of the femur. Numerous cystic spaces, some of which are blood filled, can be noted. (This is figure 8 in Hadders, H. N., and Oterdoom, H. J. The identification of aneurysmal bone cyst with haemangioma of the skeleton. J. Path. & Bact., 71:193–200, 1956.) A. F. I. P. Acc. No. 218757–288.

Figure 298. These three roentgenograms show progression (Dec. 19, 1959 [left], Jan. 2 [center] and Feb. 22, 1960 [right]) of an aneurysmal bone cyst of a humerus of a 15-year-old girl. Biopsies of the lesion were characteristic. (Courtesy of Dr. R. C. Ahlvin and Dr. L. J. Fox, St. Louis, Mo.) A. F. I. P. Acc. No. 218757–396.

Figure 299. From a photomicrographic field such as this, misinterpretation of the lesion as fibrosarcoma could be made. This section was taken from a solid portion of an aneurysmal bone cyst curetted from the spinous process of a vertebra of a 14-year-old boy. Preoperative diagnosis of giant cell tumor or hemangioma had been made. Hematoxylin and eosin stain. X 150. (From the Armed Forces Institute of Pathology.) A. F. I. P. Acc. No. 504178.



Fig. 297

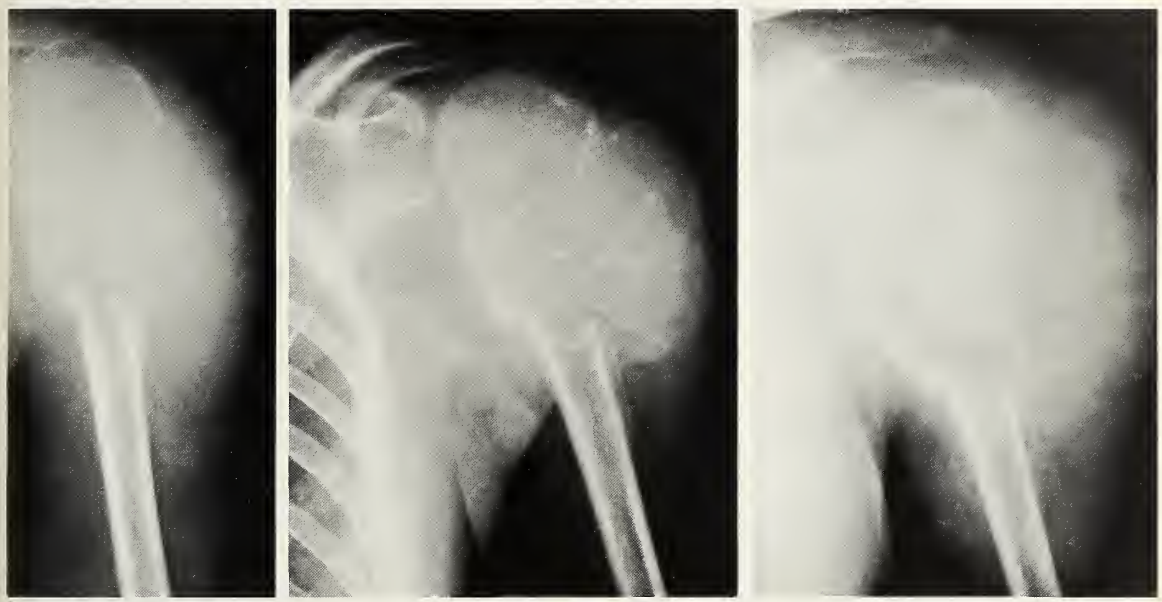

Fig. 298

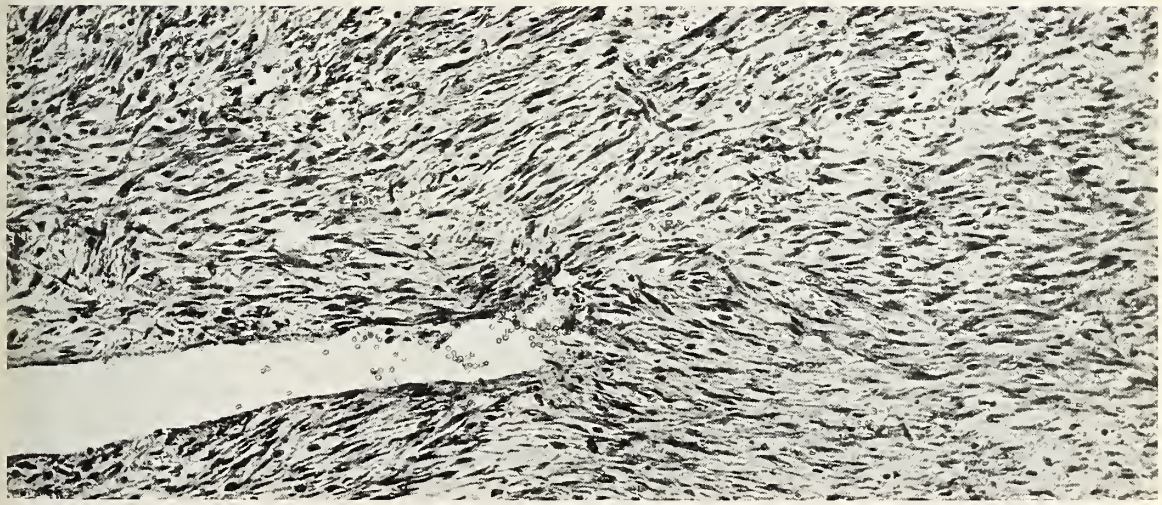

Fig. 299

ANEURYSMAL BONE CYST

(Figures 300–302 are from the same case*)

Figure 300. Roentgenogram of an aneurysmal bone cyst of a rib of a 55-year-old man. Irregular expansion of the rib and its multiloculated appearance are noted. Margins near normal bone appear sclerotized. A. F. I. P. Acc. No. 218757–290.

Figure 301. This photomicrograph shows an area of numerous multinucleated giant cells and background fibrous stroma that could be misinterpreted as giant cell tumor of bone. Periosteal bone formation and surrounding soft tissues are also seen (above). Hematoxylin and eosin stain. X 126. A. F. I. P. Acc. No. 218757–293.

Figure 302. A similar though higher power microscopic field. Hematoxylin and eosin stain. X 660. A. F. I. P. Acc. No. 218757–292.

---

*Courtesy of Dr. J. M. Burnett, St. Louis, Mo.

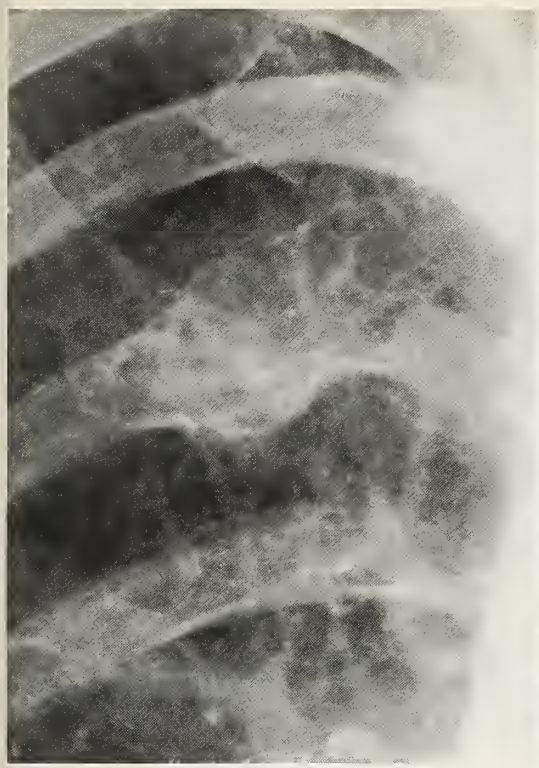

Fig. 300

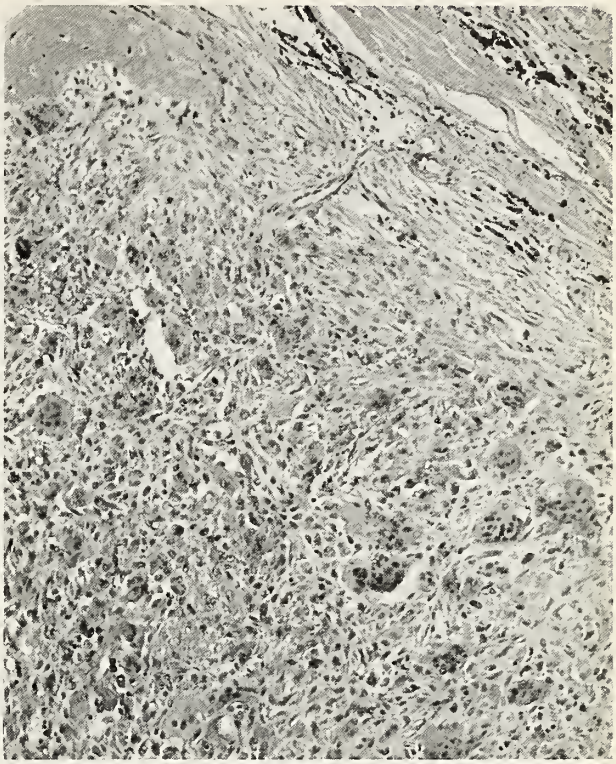

Fig. 301

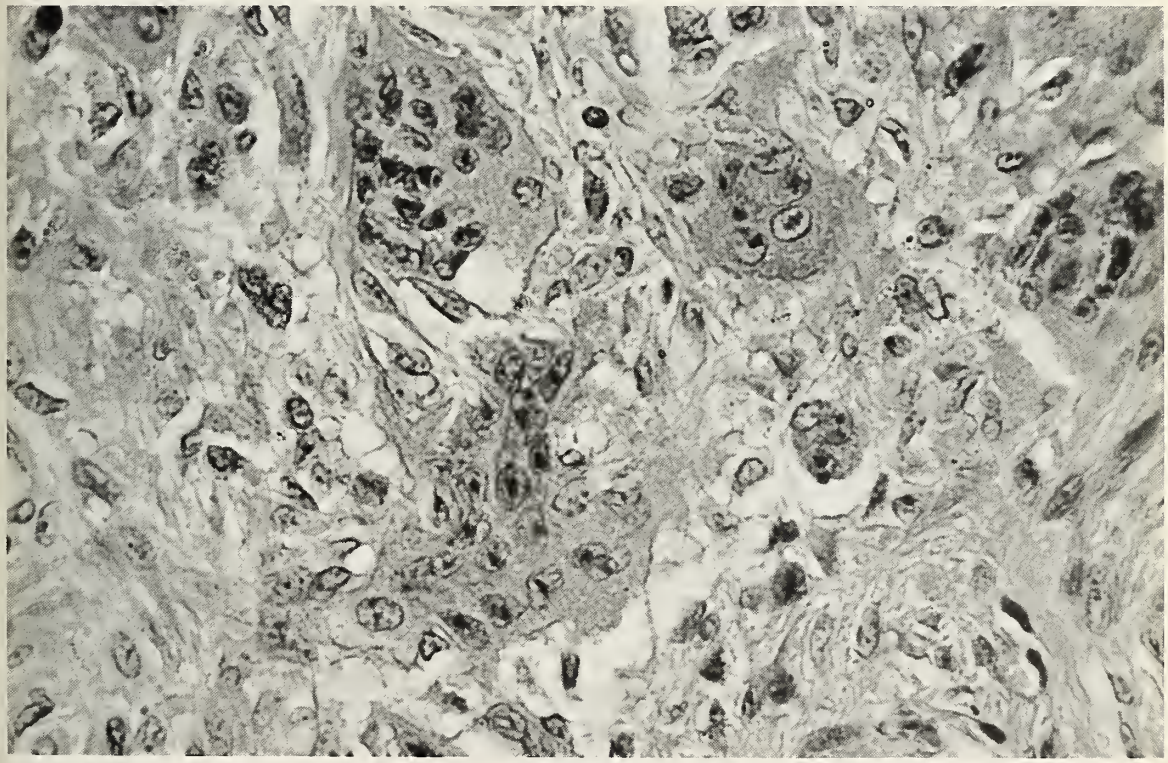

Fig. 302

Carr, C. R., Berley, F. V., and Davis, W. C. Pigmented villonodular synovitis of the hip joint. J. Bone & Joint Surg., 36–A:1007–1013, 1954.

Coley, W. B. Myositis ossificans traumatica. A report of three cases illustrating the difficulties of diagnosis from sarcoma. Ann. Surg., 57:305–337, 1913.

Collins, D. H. The Pathology of Articular and Spinal Diseases. Baltimore: Williams & Wilkins Co., 1950.

———. Haemosiderosis and haemochromatosis of synovial tissues. J. Bone & Joint Surg., 33–B: 436–441, 1951.

Decker, J. P., and Owen, B. J. An invasive giant cell tumor of tendon sheath in the foot. Bull. Ayer Clin. Lab., Pennsylvania Hosp., 4:43–53, 1954.

Fine, G., and Stout, A. P. Osteogenic sarcoma of the extraskeletal soft tissues. Cancer, 9:1027–1043, 1956.

Fisher, A. G. T. A study of loose bodies composed of cartilage or of cartilage and bone occurring in joints. With special reference to their pathology and etiology. Brit. J. Surg., 8:493–523, 1921.

Fletcher, A. G., Jr., and Horn, R. C., Jr. Giant cell tumors of tendon sheath origin. A consideration of bone involvement and report of two cases with extensive bone destruction. Ann. Surg., 133:374–385, 1951.

Freund, E. Chondromatosis of the joints. Arch. Surg., 34:670–686, 1937.

Friedman, M., and Schwartz, E. E. Irradiation therapy of pigmented villonodular synovitis. Bull. Hosp. Joint Dis., 28:19–32, 1957.

Galloway, J. D. B., Broders, A. C., and Ghormley, R. K. Xanthoma of tendon sheaths and synovial membranes. A clinical and pathologic study. Arch. Surg., 40:485–538, 1940.

Ghormley, R. K., and Romness, J. O. Pigmented villonodular synovitis (xanthomatosis) of the hip joint. Proc. Staff Meet., Mayo Clin., 29:171–180, 1954.

Greenfield, M. M., and Wallace, K. M. Pigmented villonodular synovitis. Radiology, 54:350–356, 1950.

Grewal, K. S., and Das, N. Myositis ossificans progressiva. J. Bone & Joint Surg., 35–B:244–246, 1953.

Jaffe, H. L., Lichtenstein, L., and Sutro, C. J. Pigmented villonodular synovitis, bursitis and tenosynovitis. Discussion of synovial and bursal equivalents of tenosynovial lesion commonly denoted as xanthoma, xanthogranuloma, giant cell tumor or myeloplaxoma of tendon sheath, with some consideration of tendon sheath lesion itself. Arch. Path., 31:731–765, 1941.

Jones, H. T. Loose body formation in synovial osteochondromatosis with special reference to the etiology and pathology. J. Bone & Joint Surg., 6:407–458, 1924.

Kobak, M. W., and Perlow, S. Xanthomatous giant cell tumors arising in soft tissue. Report of an instance of malignant growth. Arch. Surg., 59:909–916, 1949.

Lewis, D. Myositis ossificans. J.A.M.A., 80:1281–1287, 1923.

Lewis, R. W. Roentgen diagnosis of pigmented villonodular synovitis and synovial sarcoma of the knee joint. Preliminary report. Radiology, 49:26–38, 1947.

Leydig, S. M., and Odell, R. T. Synovial osteochondromatosis. Surg., Gynec. & Obst., 89:457–463, 1949.

Lichtenstein, L. Histiocytosis X. Integration of eosinophilic granuloma of bone. "Letterer-Siwe disease," and "Schüller-Christian disease" as related manifestations of a single nosologic entity. A.M.A. Arch. Path., 56:84–102, 1953.

———. Tumors of synovial joints, bursae, and tendon sheaths. Cancer, 8:816–830, 1955.

———, and Jaffe, H. L. Eosinophilic granuloma of bone. With report of a case. Am. J. Path., 16:595–604, 1940.

Fig. 303

ANEURYSMAL BONE CYST

Figure 303. Whole mount section from an aneurysmal bone cyst of the lateral one third of the clavicle of a 30-year-old white woman. She had had pain and noted presence of a mass of the left shoulder for one month. Hematoxylin and eosin stain. X 4. (From the Armed Forces Institute of Pathology.) A. F. I. P. Acc. No. 663719.

ANEURYSMAL BONE CYST

(Figures 305 and 306 are from the same case.* Figures 307–309 are from the same case)

Figure 304. Roentgenogram of an irregularly expanding aneurysmal bone cyst of a cervical vertebra. The delicate loculation is seen along with destruction of the transverse process. (This is figure 7b in Dahlin, D. C., Besse, B. E., Pugh, D. G., and Ghormley, R. K. Aneurysmal bone cysts. Radiology, 64:56–65, 1955.) A. F. I. P. Acc. No. 218757–291.

Figure 305. Portions of most aneurysmal bone cysts will contain spindly, osteoid, partly calcified trabeculae similar to those illustrated in this photomicrograph. Extravasated blood, scattered inflammatory cells, and vascular spaces lined by endothelium may be present. Hematoxylin and eosin stain. X 105. A. F. I. P. Acc. No. 589575–1.

Figure 306. Higher power microscopic view of this field shows osteoblastic activity with spindly bone formation. In the background may be seen inflammatory cells, red blood cells, and blood vessels. Hematoxylin and eosin stain. X 245. A. F. I. P. Acc. No. 589575–2.

Figure 307.* One of the histologic highlights of aneurysmal bone cysts demonstrated in this photomicrograph is osteoid formation in the walls of the blood sinuses. The patient was a 20-year-old man who had had swelling and soreness of the left knee. Preoperative diagnosis of "osteogenic chondrosarcoma" of the left upper tibia had been made. Hematoxylin and eosin stain. X 105. A. F. I. P. Acc. No. 687484–1.

---

*From the Armed Forces Institute of Pathology.

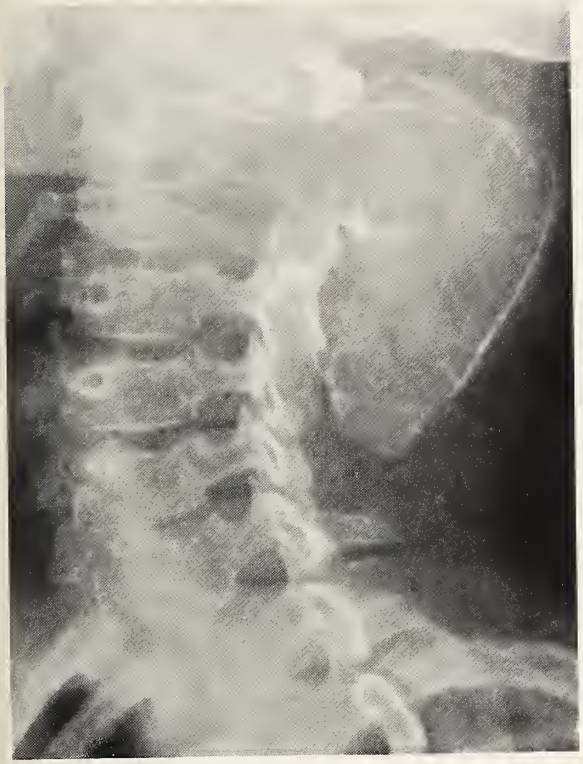

Fig. 304

Fig. 305

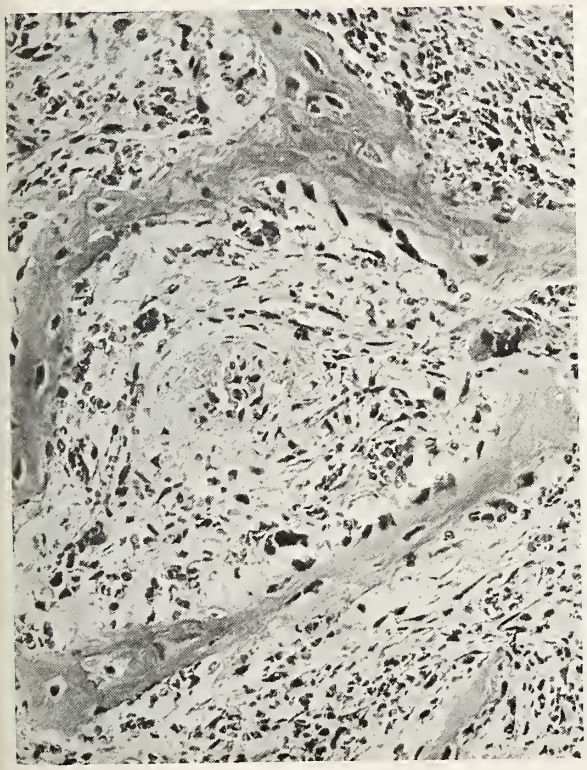

Fig. 306

Fig. 307

ANEURYSMAL BONE CYST

(Figures 307–309 are from the same case)

Figure 308.* Higher power microscopic view of sinusoidal spaces with osteoid formation within the walls. Granulation lining of the sinusoidal spaces is also evident. Hematoxylin and eosin stain. X 245. A. F. I. P. Acc. No. 687484–2.

Figure 309.* This photomicrograph further demonstrates the granulation lining of a sinusoidal space, a frequent and characteristic finding in aneurysmal bone cysts. Multinucleated giant cells are also commonly seen. Hematoxylin and eosin stain. X 165. A. F. I. P. Acc. No. 687484–3.

*From the Armed Forces Institute of Pathology.

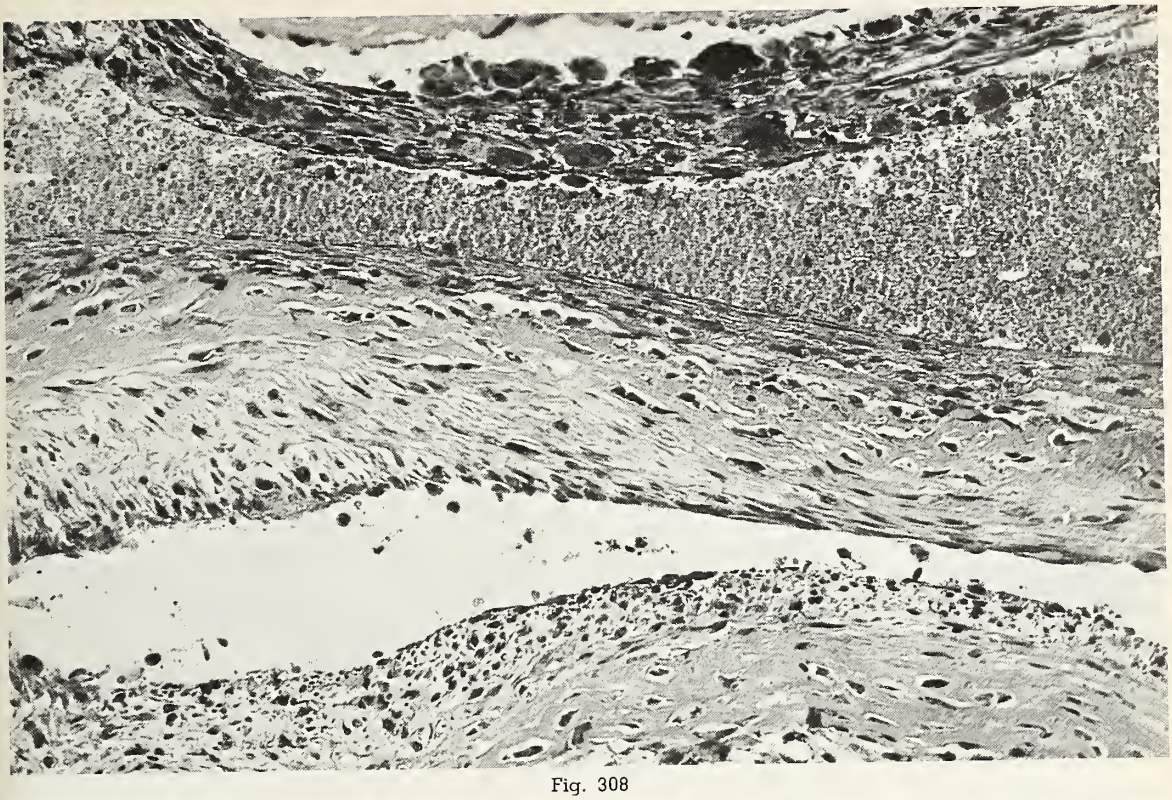

Fig. 308

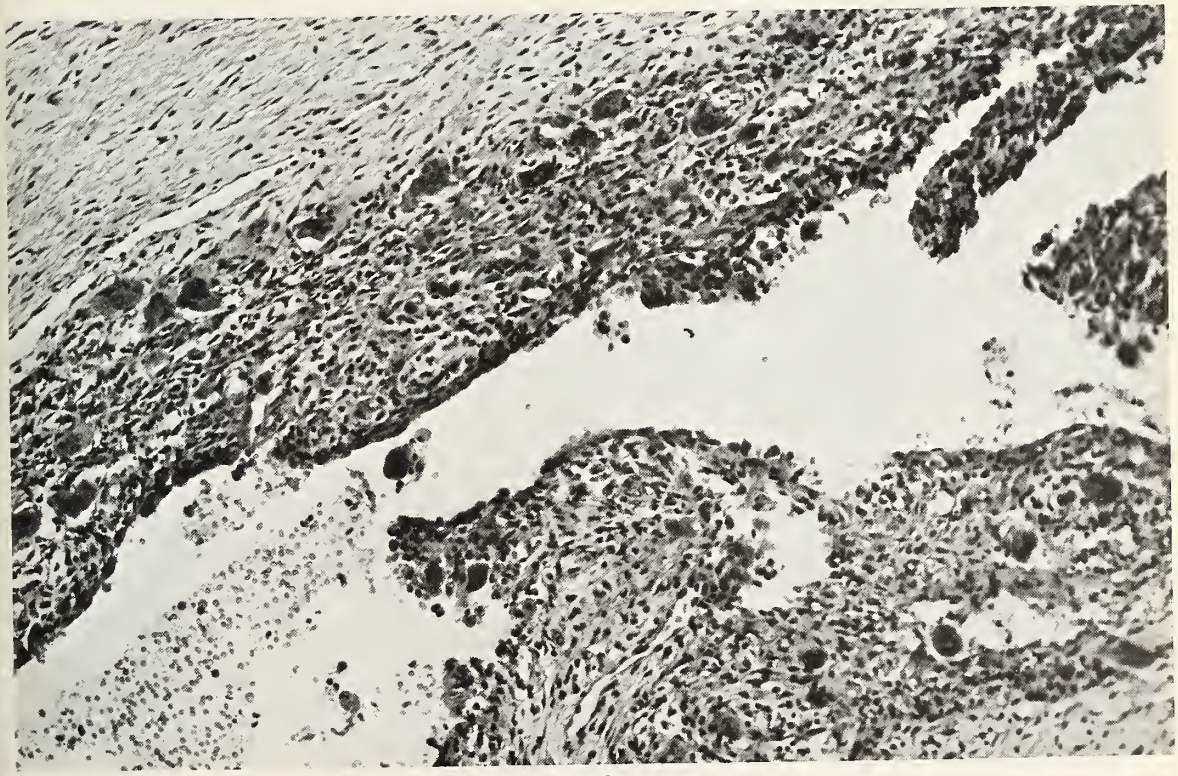

Fig. 309

FIBROUS DYSPLASIA

Figure 310. This illustration shows typical gross features of fibrous dysplasia of a rib. Cross section (below) shows uniform expansion of the bone and its replacement by a firm, granular-appearing lesion. The cortex is destroyed, but the periosteum remains intact. Adjacent unexpanded portions of the rib are also involved. The patient was a 53-year-old woman who had a symptomless tumor of the left 6th rib discovered by routine roentgenogram of the chest. W.U. 49-6073; A. F. I. P. Acc. No. 218757-294.

Figure 311. This roentgenogram demonstrates fibrous dysplasia of the midshaft of a tibia as a radiolucent and partly sclerotic lesion. Note eroded cortex, evidence of periosteal reaction, and fine fracture line. W.U. 49-2259; A. F. I. P. Acc. No. 218757-295.

Figure 312. Irregular bone formation of fibrous dysplasia is seen in this photomicrograph. The bone is poorly oriented and is partly calcified. Osteoblastic rimming is not present. The stroma is fairly cellular and vascular. Hematoxylin and eosin stain. X 140. W.U. 61-1120; A. F. I. P. Acc. No. 218757-400.

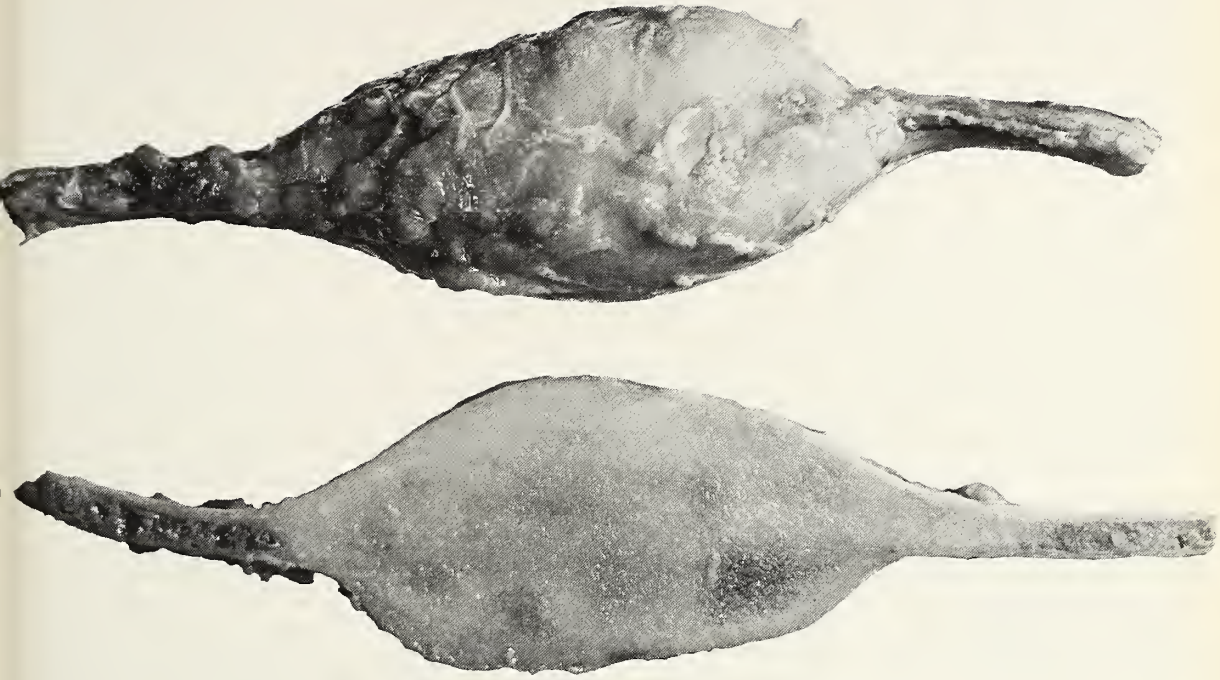

Fig. 310

Fig. 311

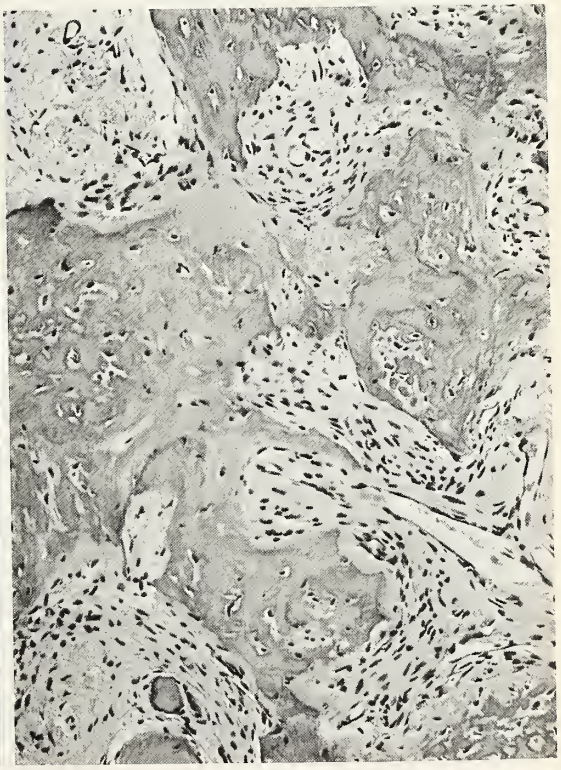

Fig. 312

FIBROUS DYSPLASIA

Figure 313. Note the focus of multinucleated giant cells and stroma of fibrous dysplasia in this photomicrograph. On biopsy examination, such an area could be misinterpreted as giant cell tumor. Hematoxylin and eosin stain. X 400. W.U. 54–3311; A. F. I. P. Acc. No. 218757–297.

Figure 314. Photomicrograph showing the pattern of reticulin fibers in the fibrous (woven) bone of fibrous dysplasia. Wilder's reticulin stain. X 140. W.U. 61–725; A. F. I. P. Acc. No. 218757–401.

Figure 315. Photomicrograph of an ossifying fibroma demonstrating a lesion that is often confused with fibrous dysplasia. This lesion occurred in the hard palate of a 3-year-old child. Osteoblastic rimming in this illustration aids in distinguishing the two lesions. Hematoxylin and eosin stain. X 130. B.H. 49996; A. F. I. P. Acc. No. 218757–299.

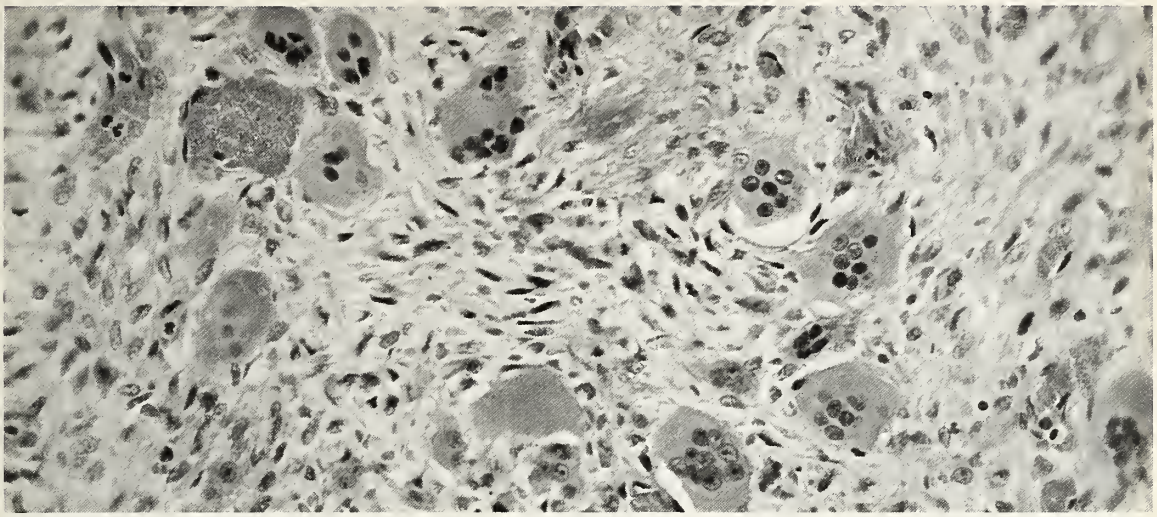

Fig. 313

Fig. 314

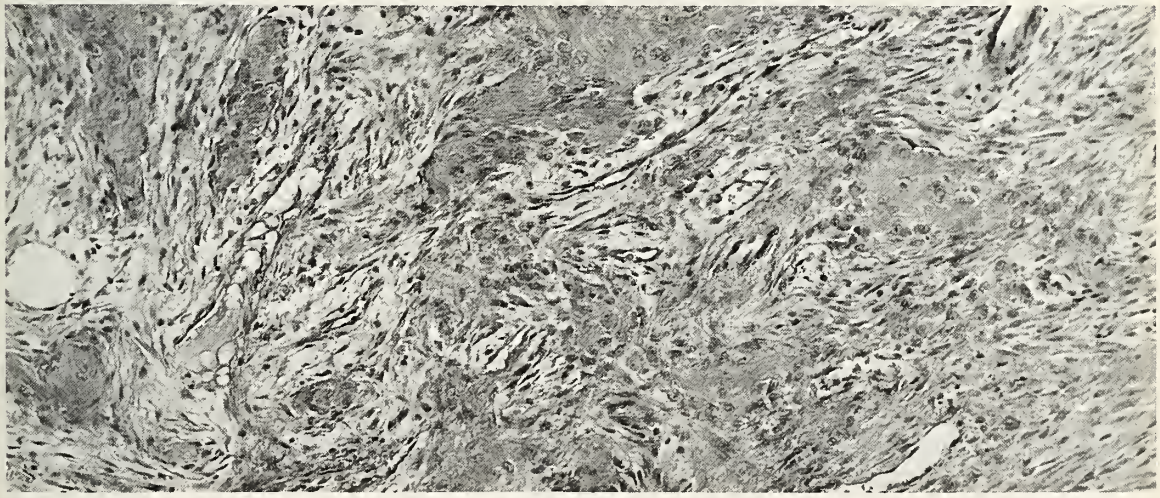

Fig. 315

METAPHYSIAL FIBROUS DEFECT

Figure 316.* Antero-posterior and lateral roentgenograms of a metaphysial fibrous defect. The eccentric tumor is oriented in the longitudinal axis and has sclerotized margins. W.U. 55–3782; A. F. I. P. Acc. No. 218757–300.

Figure 317.* Roentgenogram showing a larger metaphysial lesion, with sclerotized margins, accompanied by a fracture. W.U. 55–3858; A. F. I. P. Acc. No. 218757–301.

Figure 318.* Histologic section illustrates a typical whorling pattern of metaphysial fibrous defect, with some absorption of cortical bone. Hematoxylin and eosin stain. X 120. W.U. 55–3593; A. F. I. P. Acc. No. 218757–302.

---

*From Cunningham, J. B., and Ackerman, L. V. Metaphyseal fibrous defects. J. Bone & Joint Surg., 38–A:797–808, 1956. Figures 1–A, 3, and 9 are fascicle figures 316 (left)–318.

Fig. 316

Fig. 317

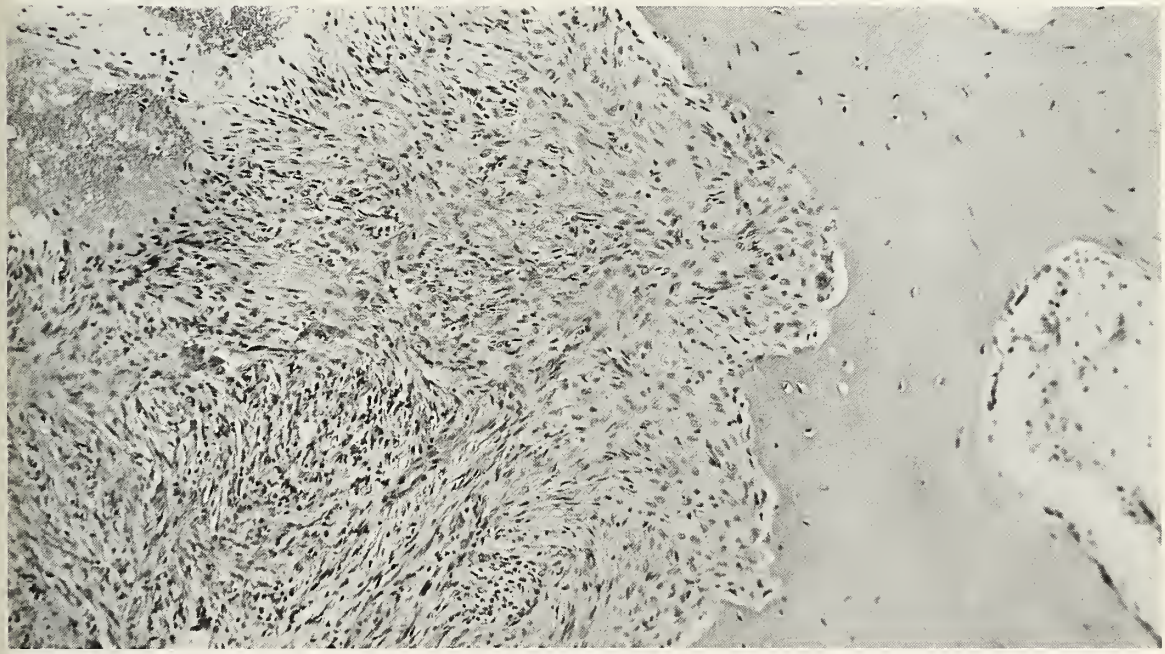

Fig. 318

METAPHYSIAL FIBROUS DEFECT

(Figures 319 and 320 are from the same case)

Figure 319. This photomicrograph again demonstrates the type of change that may be misinterpreted as fibrosarcoma, a highly cellular area made up of fibroblasts. Hematoxylin and eosin stain. X 660. B.H. 57–4038; A. F. I. P. Acc. No. 218757–303.

Figure 320. The characteristic clusters of multinucleated giant cells in sections of metaphysial fibrous defect may account for misinterpretation as giant cell tumor. Hematoxylin and eosin stain. X 615. B.H. 57–4038; A. F. I. P. Acc. No. 218757–304.

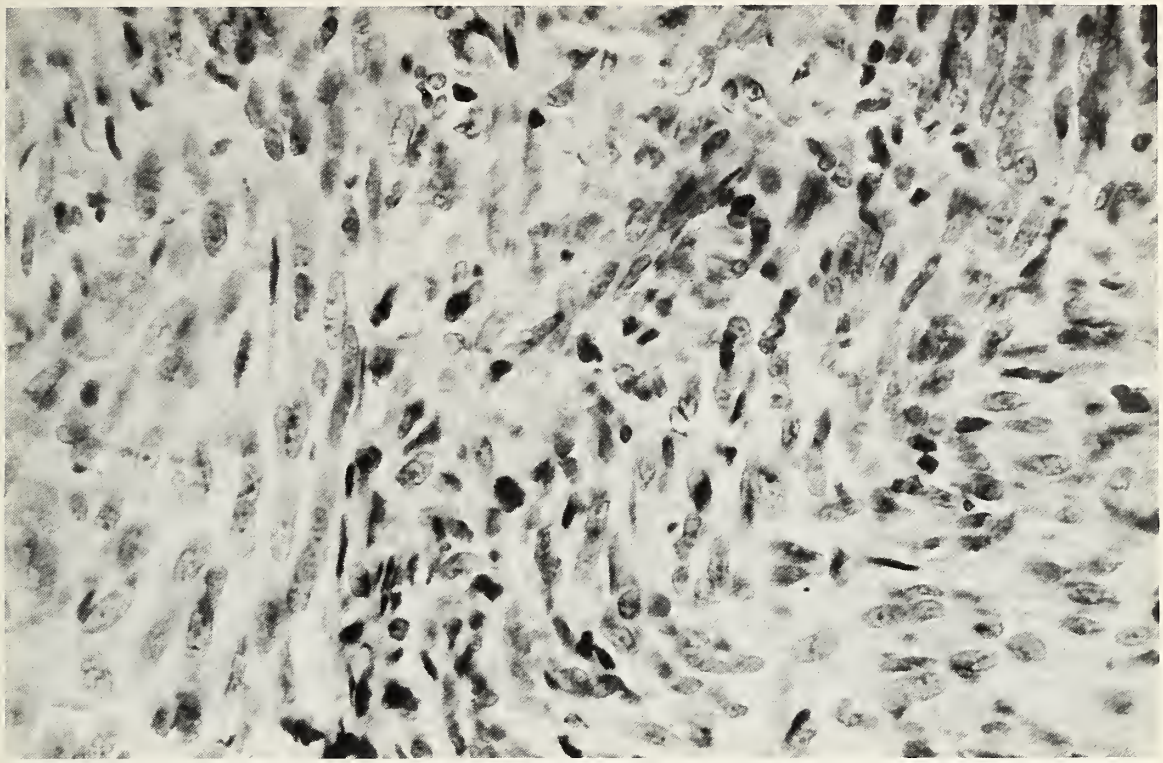

Fig. 319

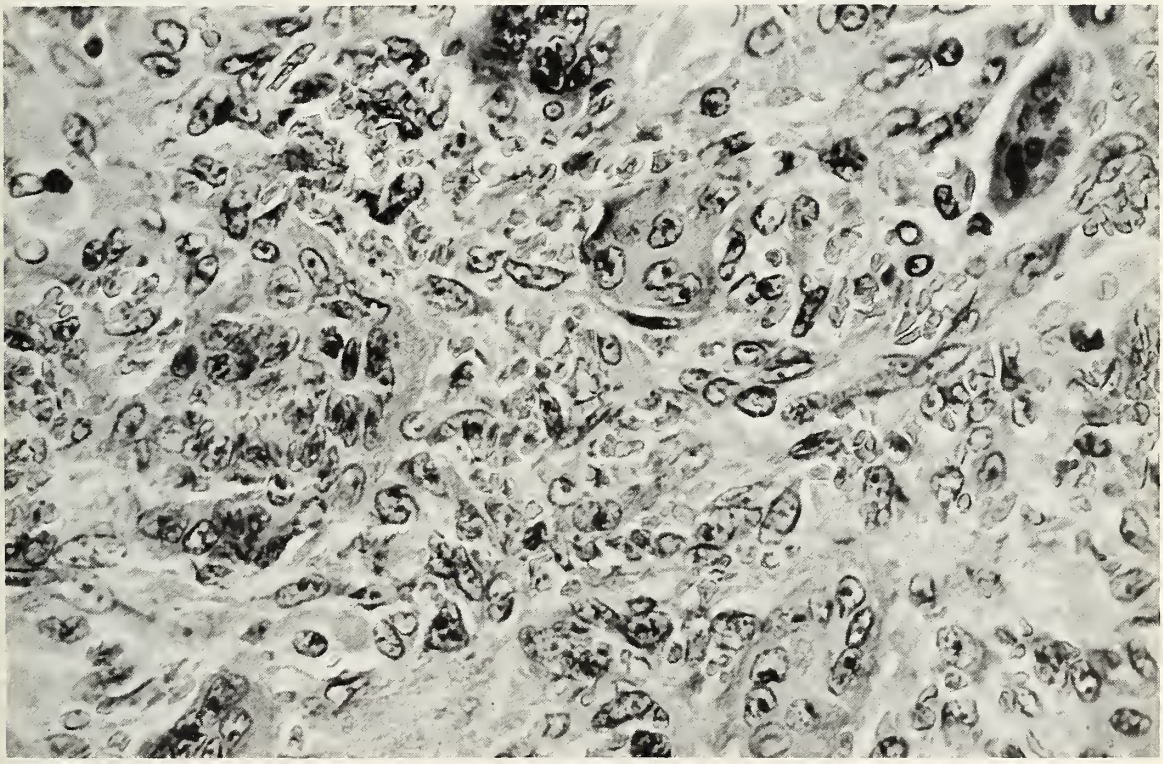

Fig. 320

PERIOSTEAL DESMOID

(Figures 321 and 322 are from the same case)

Figure 321. Roentgenogram of a sharply delimited lesion in the metaphysial area of the femur in an 8-year-old boy. W.U. 58–904; A. F. I. P. Acc. No. 218757–305.

Figure 322. Photomicrograph showing well differentiated fibrous tissue with abundant intercellular substance and no mitotic figures. At operation, periosteum extended over this lesion and made enucleation relatively simple, after diagnosis was made on frozen section. Postoperative course was uneventful. Hematoxylin and eosin stain. X 130. W.U. 58–1204A; A. F. I. P. Acc. No. 218757–306.

Fig. 321

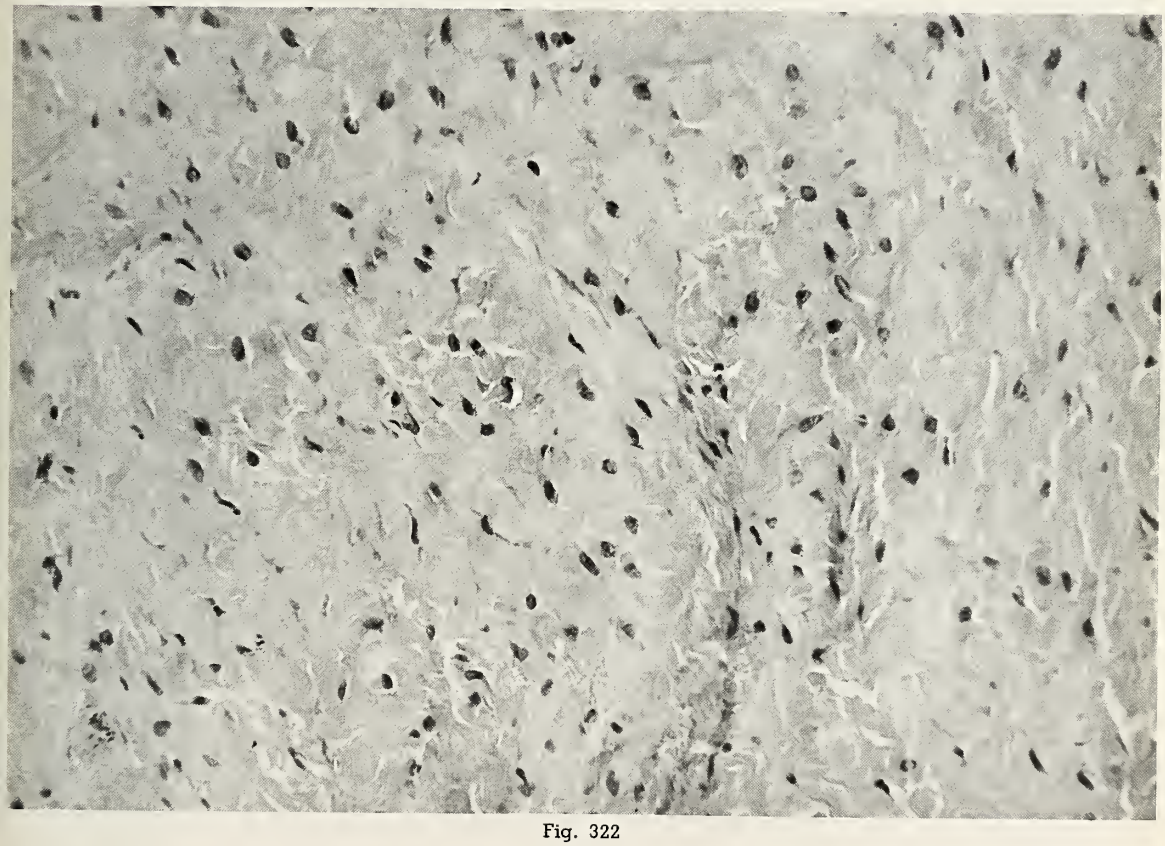

Fig. 322

PIGMENTED VILLONODULAR SYNOVITIS

(Figures 324 and 325 are from the same case*)

Figure 323. Photograph of a gross specimen of a pigmented villonodular synovitis from the knee joint of a 30-year-old woman. Synovial surfaces are diffusely involved, and discoloration of the synovium is evident. Note also fine villous projections and matted masses of villi. W.U. 50–3300; A. F. I. P. Acc. No. 218757–307.

Figure 324. Histologic section of a pigmented villonodular synovitis from the knee joint of a 34-year-old woman. Note typical stroma, synovial-covered villi, and numerous blood vessels. Hematoxylin and eosin stain. X 83. W.U. 58–4220; A. F. I. P. Acc. No. 218757–308.

Figure 325. Higher power magnification of this section. Hematoxylin and eosin stain. X 250. W.U. 58–4219; A. F. I. P. Acc. No. 218757–309.

---

*Courtesy of Dr. R. W. Ogilvie, St. Louis, Mo.

Fig. 323

Fig. 324

Fig. 325

OSTEOCHONDROMATOSIS

(Figures 326–329 are from the same case)

Figure 326. Roentgenographic demonstration of typical findings of osteochondromatosis. Speckled calcification and ossification are seen within the joint spaces, with accompanying soft tissue swelling. A. F. I. P. Acc. No. 218757–310.

Figure 327. Photograph of the gross specimen of the tumor showing numerous cartilaginous excrescences on synovial surfaces. (This is figure 804 in Ackerman, L. V. Surgical Pathology. St. Louis: C. V. Mosby Co., 1953.) W.U. 48–3983; A. F. I. P. Acc. No. 218757–311.

Figure 328. Histologic section outlines multiple cartilaginous nodules in the synovium. Some nodules are covered by synovial membrane (upper). Dark areas at the periphery of the cartilaginous nodules represent bone formation. Hematoxylin and eosin stain. X 63. A. F. I. P. Acc . No. 218757–58.

Figure 329. Higher power microscopic section of a cartilaginous nodule. Nuclear atypism is evident and may be misinterpreted as malignant neoplasm. Hematoxylin and eosin stain. X 210. A. F. I. P. Acc. No. 218757–59.

Fig. 326

Fig. 327

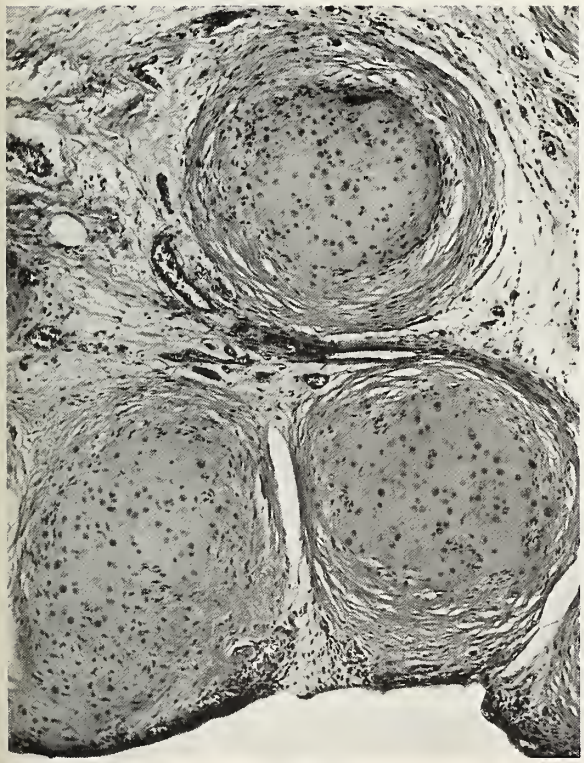

Fig. 328

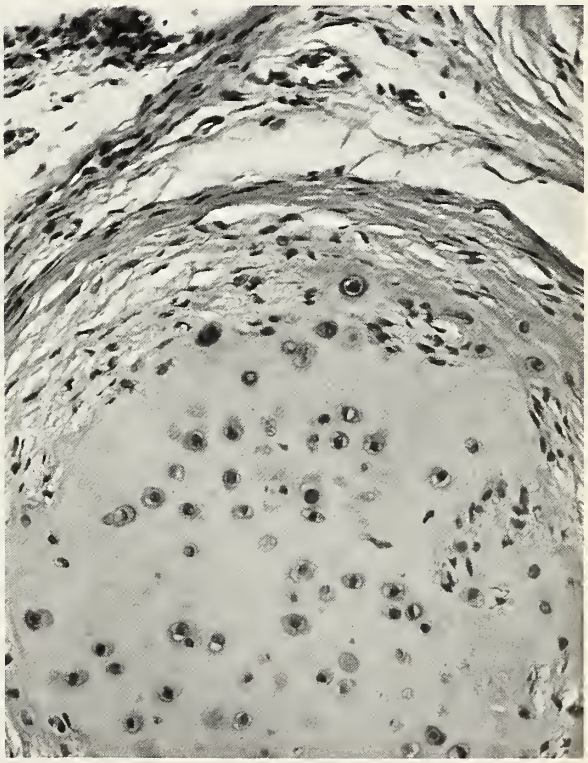

Fig. 329

OSTEOCHONDROMATOSIS

(Figures 330 and 331 are from the same case*)

Figure 330. Photomicrograph showing mature cartilaginous nodules of osteochondromatosis from the knee joint of a 62-year-old physician. The patient has been followed for five years after operation; there has been recurrence in the past year.

Although these lesions may show extreme variation in microscopic pattern, none has been noted by us to have become malignant. In a recent case, however, biopsy of the synovium from a knee joint showed malignant-appearing cartilage cells. Although synovial chondromatosis was suspected initially, chondrosarcoma of bone was found later to have secondarily involved the knee joint and synovium, which in our experience is a rare occurrence. Hematoxylin and eosin stain. X 112. A. F. I. P. Acc. No. 218757–312.

Figure 331. The insert shows atypical nuclei, that may be seen in figure 330, which could be misinterpreted as those of malignant cartilaginous tumor. Hematoxylin and eosin stain. X 660. B.H. 56–8319; A. F. I. P. Acc. No. 218757–387.

---

*Courtesy of Dr. R. P. Shanewise, Spokane, Wash.

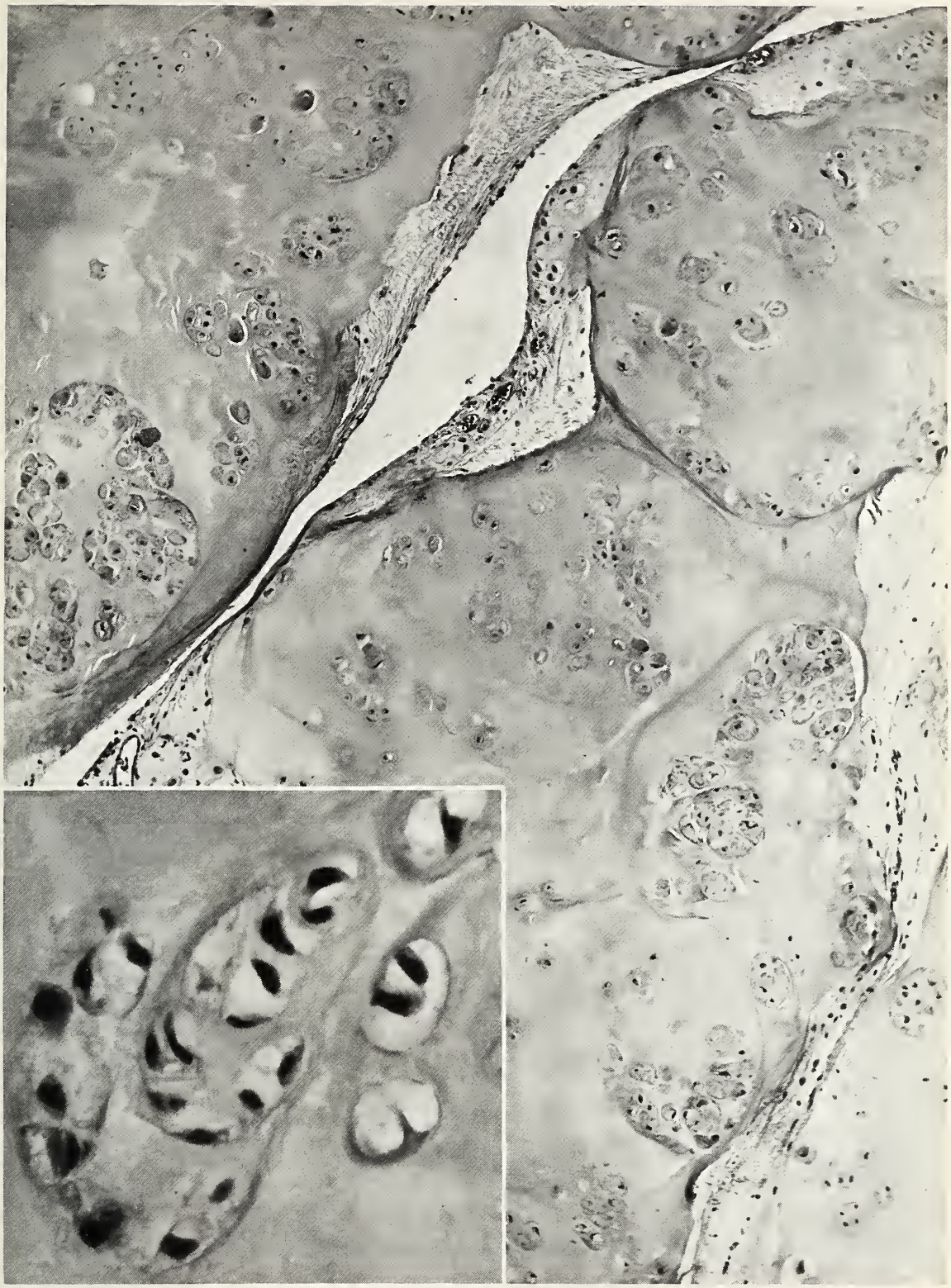

Fig. 331

Fig. 330

MYOSITIS OSSIFICANS

(Figures 332 and 333 are from the same case. Figures 334 and 335 are from the same case)

Figure 332. Roentgenogram, made the fifth week after diagnosis of myositis ossificans in a child, shows characteristic "dotted-veil" effect. W.U. 56–50; A. F. I. P. Acc. No. 218757–313.

Figure 333. Roentgenogram two years later demonstrated disappearance of the soft tissue lesion and replacement by periosteal thickening. The cortex does not appear remarkable. W.U. 57–325; A. F. I. P. Acc. No. 218757–314.

Figure 334. Gross specimen of myositis ossificans removed from the buttock of a 24-year-old man. Its well circumscribed characteristics are illustrated in the photograph. Biopsy was incorrectly interpreted as rhabdomyosarcoma. The hemorrhagic area represents the biopsy site. W.U. 56–6193; A. F. I. P. Acc. No. 218757–319.

Figure 335. Roentgenogram of the gross specimen shows a thin rim of calcification and bone formation. W.U. 56–6190; A. F. I. P. Acc. No. 218757–320.

Fig. 332

Fig. 333

Fig. 334

Fig. 335

MYOSITIS OSSIFICANS

(Figures 336–339 are from the same case*)

Figure 336. Roentgenogram of a thigh of a 24-year-old man who had had pain in the area for a short time. Dotted lines outline an almost imperceptible rim of calcification about the mass. W.U. 58–3580; A. F. I. P. Acc. No. 218757–315.

Figure 337. Two months after the mass had been removed, irregular periosteal and soft tissue bone formation were noted. W.U. 58–3581; A. F. I. P. Acc. No. 218757–316.

Figure 338. Four months later there was regression in size of the periosteal and soft tissue masses. W.U. 58–3582; A. F. I. P. Acc. No. 218757–317.

Figure 339. Six months later further regression of the mass and increased sclerosis could be noted. W.U. 58–3583; A. F. I. P. Acc. No. 218757–318.

---

*Courtesy of Dr. Earl Vandegrift and Dr. R. S. Totten, Pittsburgh, Pa.

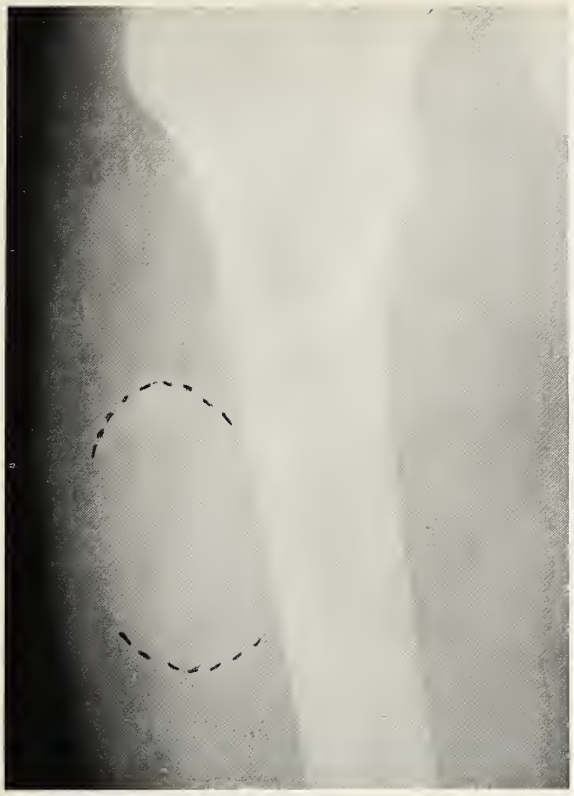

Fig. 336

Fig. 337

Fig. 338

Fig. 339

MYOSITIS OSSIFICANS

(Figures 341–344 are from the same case)

Figure 340. Photomicrograph demonstrating encapsulation. Note progression of pattern from a cellular zone (left) to a zone showing fairly well oriented bone (right). W.U. 57–1317; A. F. I. P. Acc. No. 218757–322.

Figure 341. Photomicrograph representing zone 1 illustrates proliferative fibrous tissue with bizarre nuclei. These findings may be misinterpreted as a malignant lesion. Hematoxylin and eosin stain. X 430. W.U. 55–6881A; A. F. I. P. Acc. No. 218757–325.



PERIPHERAL ZONE

Zone 1 Zone 2 Zone 3

DIRECTION OF MATURATION →

Fig. 340

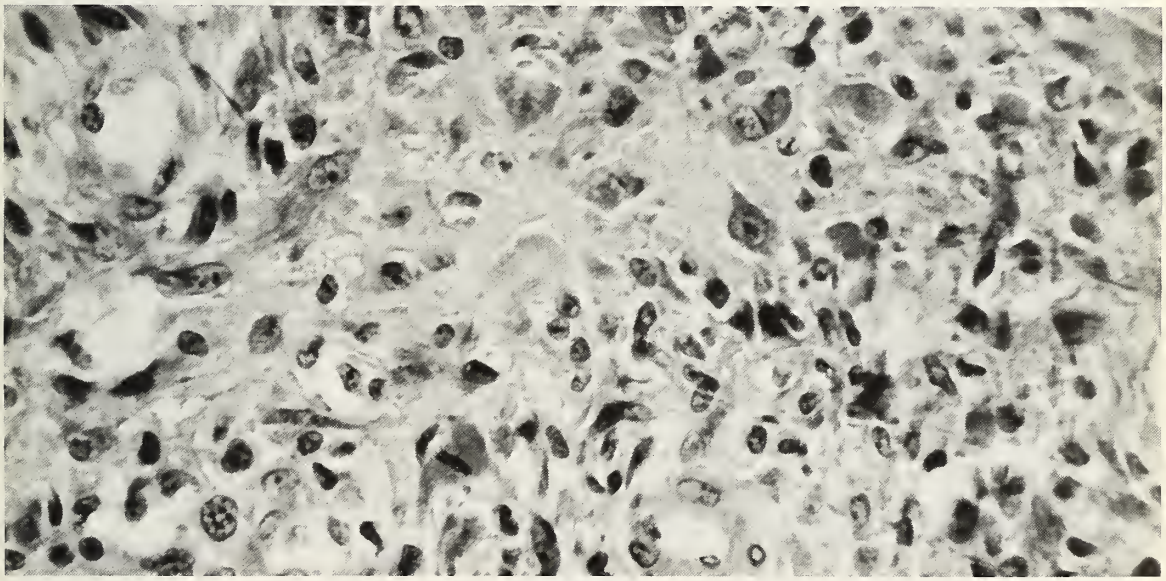

Fig. 341

MYOSITIS OSSIFICANS

(Figures 341–344 are from the same case)

Figure 342. Photomicrograph which corresponds to zone 2 illustrates osteoid formation with background of vascular fibrous stroma. Hematoxylin and eosin stain. X 120. W.U. 55–6880A; A. F. I. P. Acc. No. 218757–324.

Figure 343. Photomicrograph corresponding to zone 3 illustrates the mature, fairly well oriented peripheral bone. Hematoxylin and eosin stain. X 120. W.U. 55–6879A; A. F. I. P. Acc. No. 218757–323.

Figure 344. Photomicrograph showing the periphery and cellular portion of myositis ossificans. Atypical skeletal muscle fibers and bizarre nuclei or proliferating connective tissue often lead to misinterpretation of the biopsy as malignant. Hematoxylin and eosin stain. X 235. W.U. 57–421A; A. F. I. P. Acc. No. 218757–321.

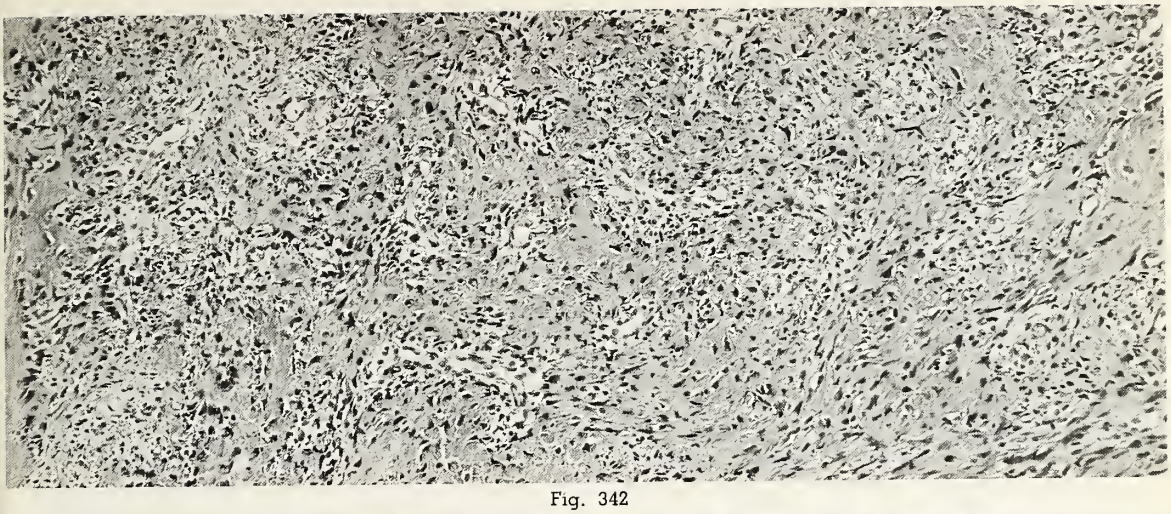

Fig. 342

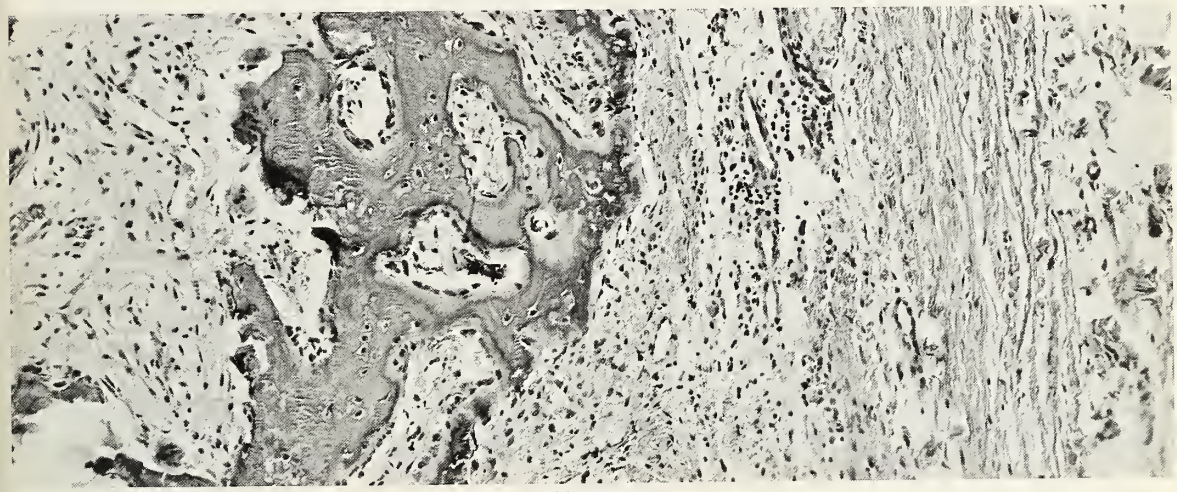

Fig. 343

Fig. 344

MYOSITIS OSSIFICANS

(Figures 345 and 346 are from the same case.* Figures 348 and 349 are from the same case)

Figure 345. This soft tissue mass of one months' duration had been removed from around a knee joint of a 10-year-old girl and was diagnosed as myositis ossificans. Photomicrograph shows osteoid formation progressing in an orderly pattern toward mature, calcified bone. Osteoblasts are plentiful but do not show characteristics of malignancy. Hematoxylin and eosin stain. X 150. A. F. I. P. Acc. No. 218757–26.

Figure 346. Photomicrograph illustrating cellular osteoid and vascular fibrous stroma. The patient was living and well at least five years after local excision of this mass. Hematoxylin and eosin stain. X 150. A. F. I. P. Acc. No. 218757–25.

Figure 347. Photomicrograph illustrates cartilage formation and well oriented mature bone at the periphery of myositis ossificans. Hematoxylin and eosin stain. X 98. A. F. I. P. Acc. No. 218757–326.

Figure 348. Photomicrograph which shows cellular osteoid formation in myositis ossificans from the abdominal wall of a 15-year-old girl. Hematoxylin and eosin stain. X 165. (Courtesy of Dr. M. W. Rudicel, Kokomo, Ind.) A. F. I. P. Acc. No. 218757–11.

---

*Courtesy of Dr. H. D. Palmer, Denver, Colo.

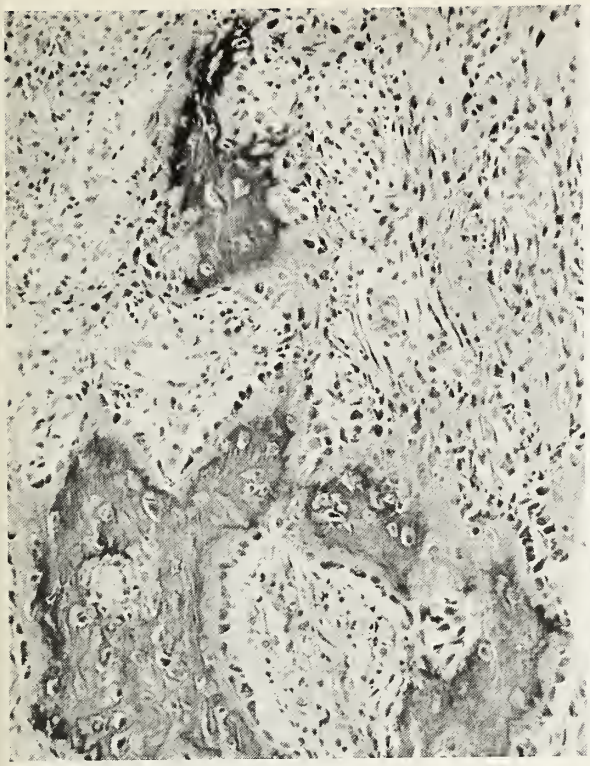

Fig. 345

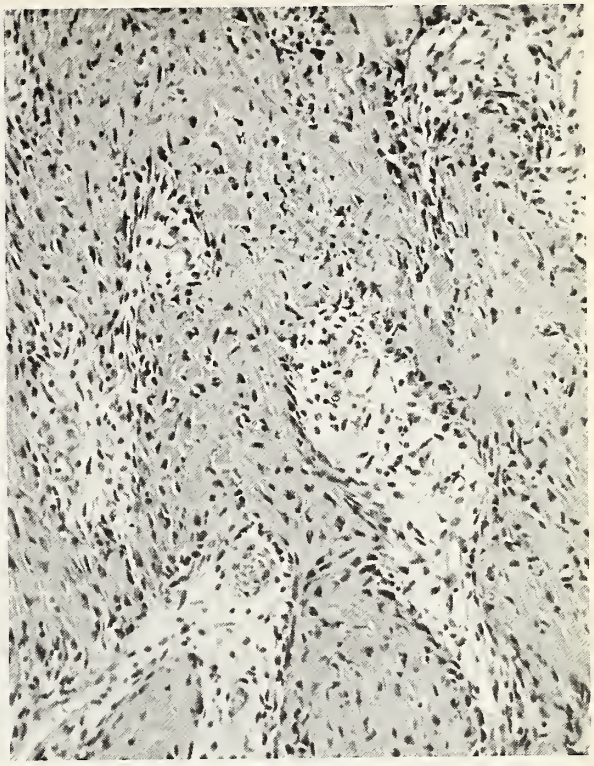

Fig. 346

Fig. 347

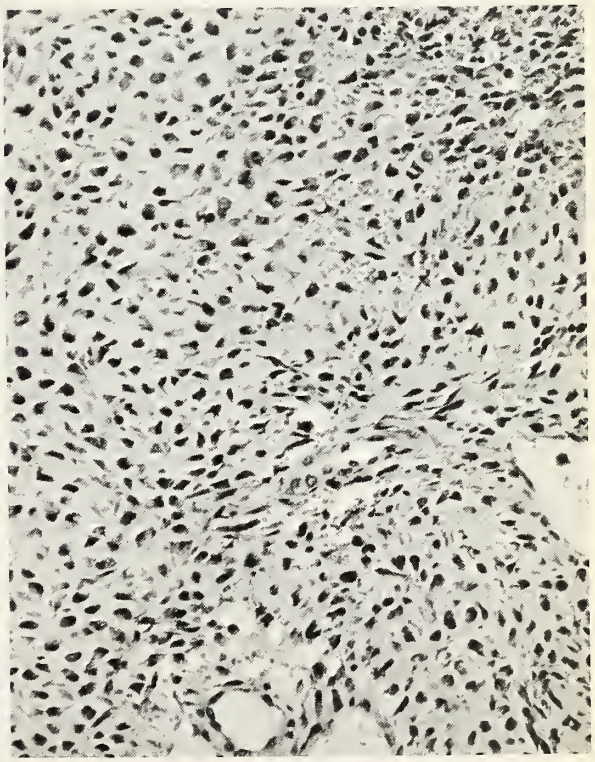

Fig. 348

Litwer, H. Pigmented nodular tenosynovitis of the hand with erosion of bone. Radiology, 69: 247–250, 1957.

McGavran, M. H., and Spady, H. A. Eosinophilic granuloma of bone. A study of twenty-eight cases. J. Bone & Joint Surg., 42–A:979–992, 1960.

McMaster, P. E. Pigmented villonodular synovitis with invasion of bone. Report of six cases. J. Bone & Joint Surg., 42–A:1170–1183, 1960.

Mussey, R. D., Jr., and Henderson, M. S. Osteochondromatosis. J. Bone & Joint Surg., 31–A:619–627, 1949.

Otani, S. A discussion of eosinophilic granuloma of bone, Letterer-Siwe disease and Schüller-Christian disease. J. Mt. Sinai Hosp., 24:1079–1092, 1957.

———, and Ehrlich, J. C. Solitary granuloma of bone. Simulating primary neoplasm. Am. J. Path., 16:479–490, 1940.

Shafer, S. J., and Larmon, W. A. Pigmented villonodular synovitis. A report of seven cases. Surg., Gynec. & Obst., 92:574–580, 1951.

Spencer, H., and Whimster, I. W. The development of giant-celled tendon-sheath tumours and related conditions (chronic villonodular synovitis and cutaneous histiocytoma). J. Path. & Bact., 62:411–418, 1950.

Wildi, A. Ein Beitrag zur Patho-und Histogenese der Myositis ossificans. Frankf. Zschr. Path., 38:231–245, 1929.

Wilmoth, C. L. Osteochondromatosis. J. Bone & Joint Surg., 23:367–374, 1941.

Young, J. M., and Hudacek, A. G. Experimental production of pigmented villonodular synovitis in dogs. Am. J. Path., 30:799–812, 1954.

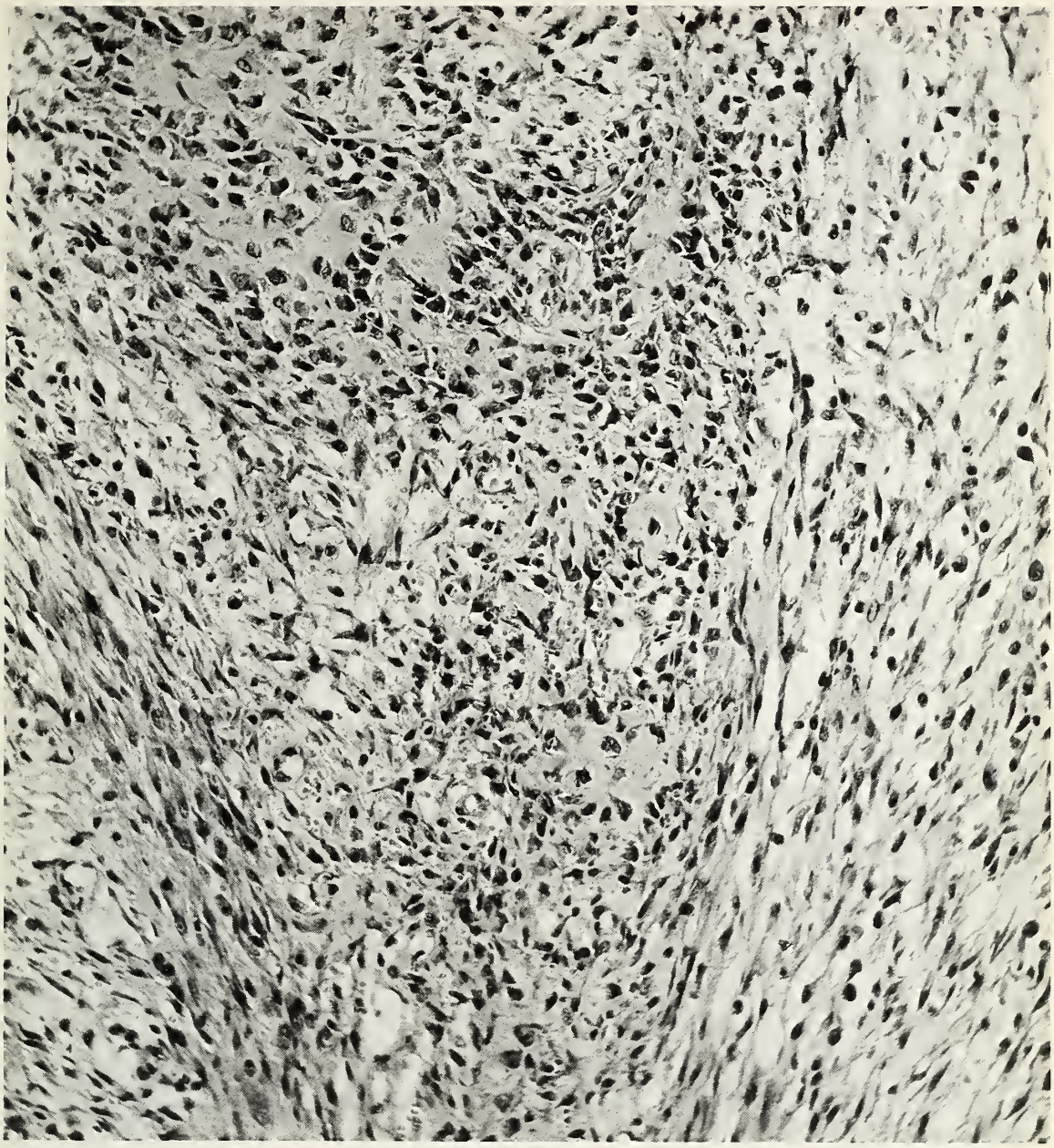

Fig. 349

MYOSITIS OSSIFICANS

(Figures 348 and 349 are from the same case)

Figure 349. Photomicrograph showing the cellular inner zone of this myositis ossificans. Focal osteoid formation is also evident. The osteoid and the cellularity of stroma lead to difficulties in interpretation of these lesions.

This patient was well at least 15 months after local excision of the mass from the abdominal wall. Hematoxylin and eosin stain. X 210. (Courtesy of Dr. M. W. Rudicel, Kokomo, Ind.) A. F. I. P. Acc. No. 218757–12.

EOSINOPHILIC GRANULOMA

(Figures 350–352 are from the same case)

Figure 350. Roentgenogram illustrating destructive nature of an eosinophilic granuloma of a femur. Note both medullary and cortical destruction and slight periosteal bone formation. Following biopsy the patient received radiation therapy. Ten years later (age 18) the patient was well and without symptoms. W.U. 48–6045; A. F. I. P. Acc. No. 218757–328.

Figure 351. This roentgenogram, taken 10 years after therapy, demonstrates an essentially normal femur with excellent remodeling of the bone. It is noted that periosteal reaction has disappeared. W.U. 58–5095; A. F. I. P. Acc. No. 218757–369.

Figure 352. Histologic section of eosinophilic granuloma shows relationship to bone and bone destruction. Hematoxylin and eosin stain. X 200. B.H. 63239; A. F. I. P. Acc. No. 218757–331.

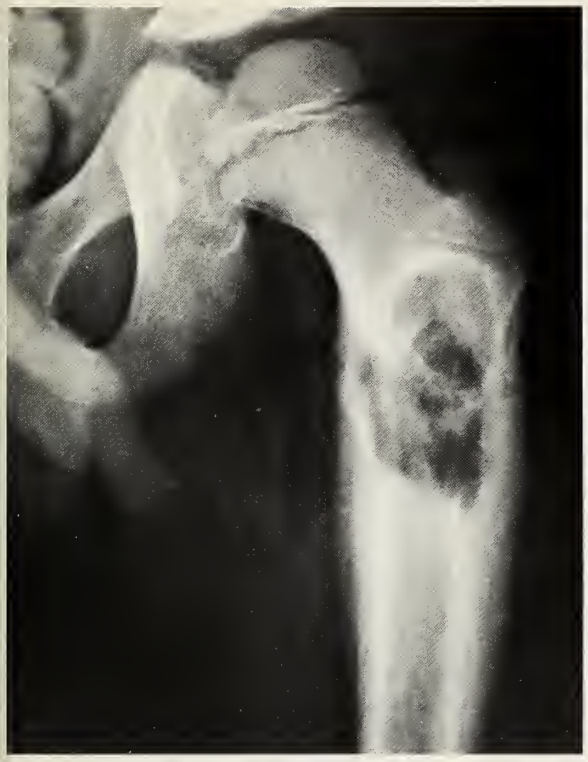

Fig. 350

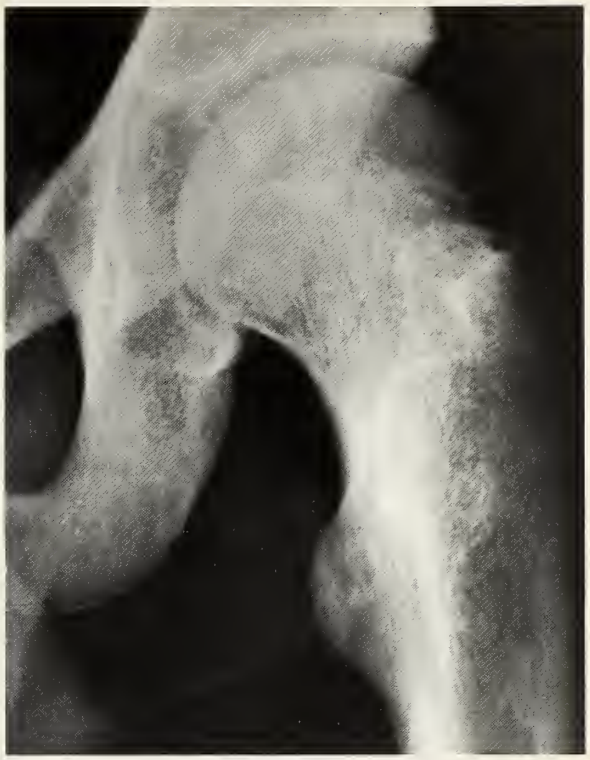

Fig. 351

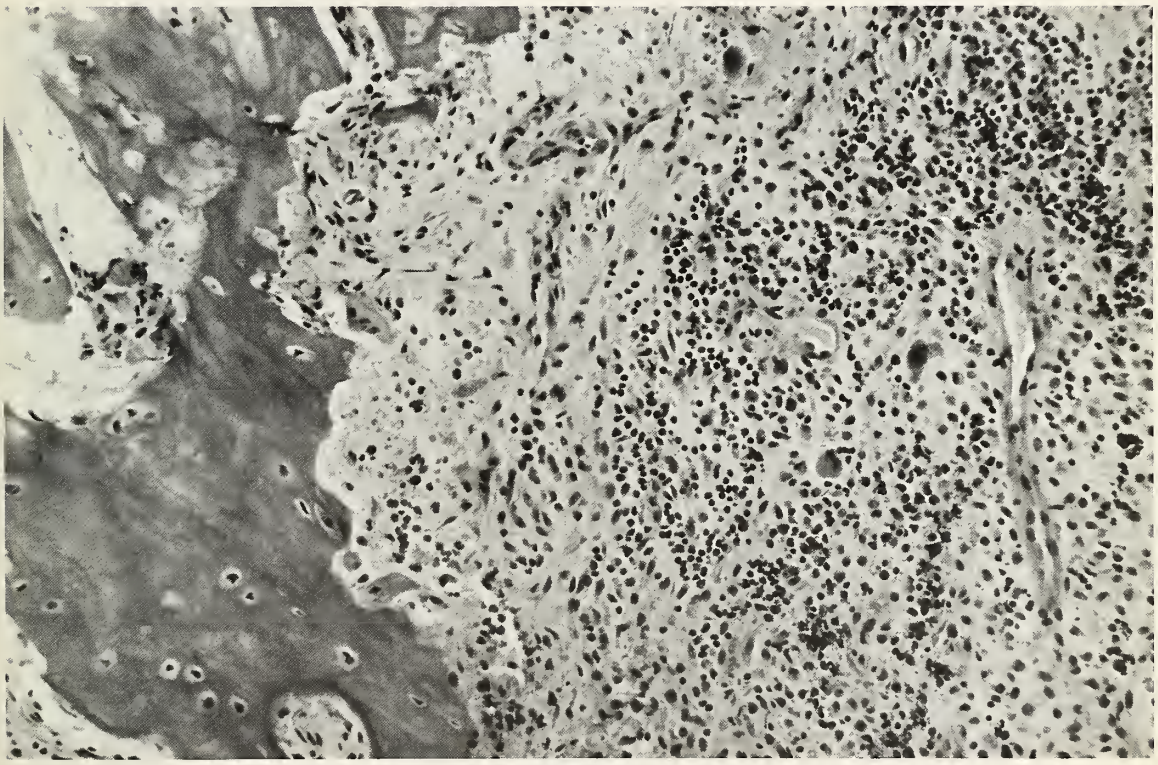

Fig. 352

EOSINOPHILIC GRANULOMA

Figure 353. Roentgenogram of eosinophilic granuloma showing a destructive process involving medulla and cortex of the shaft of a femur. Periosteal bone formation is present.

The patient was a 15-year-old boy who had had insidious onset of pain in the left thigh for three weeks. There had been no associated fever. Clinically the lesion was interpreted as an osteomyelitis or a Ewing's sarcoma. W.U. 50–5372; A. F. I. P. Acc. No. 218757–329.

Figure 354. Photomicrograph showing the typical cellular composition of this type of tumor. Note multinucleated giant cells, background of histiocytes, and scattered eosinophils. Hematoxylin and eosin stain. X 660. A. F. I. P. Acc. No. 218757–330.

Figure 355. Histologic section of eosinophilic granuloma from a humerus of a 12-year-old boy; the section shows histiocytes, eosinophils, and several multinucleated giant cells. Pain had been present for one week; fever had been noted for one day. Clinical impression was of osteomyelitis. Hematoxylin and eosin stain. X 660. B.H. 51–3487; A. F. I. P. Acc. No. 218757–332.

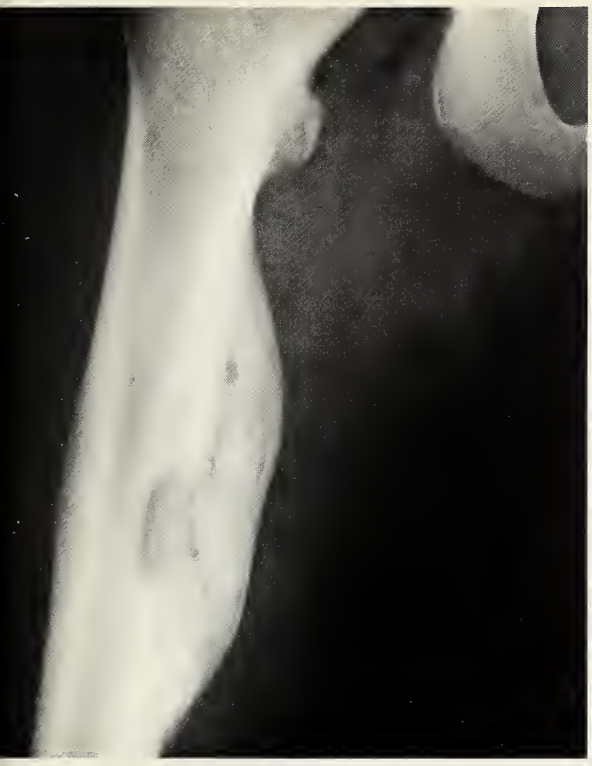

Fig. 353

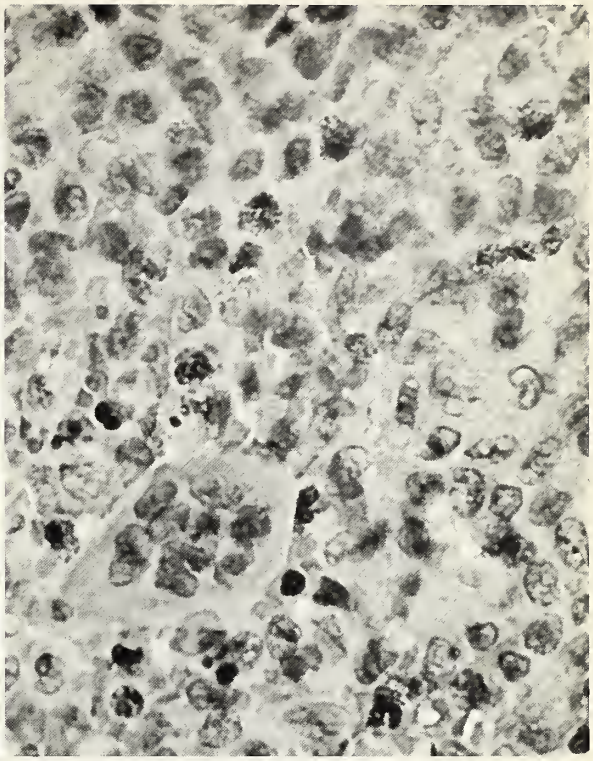

Fig. 354

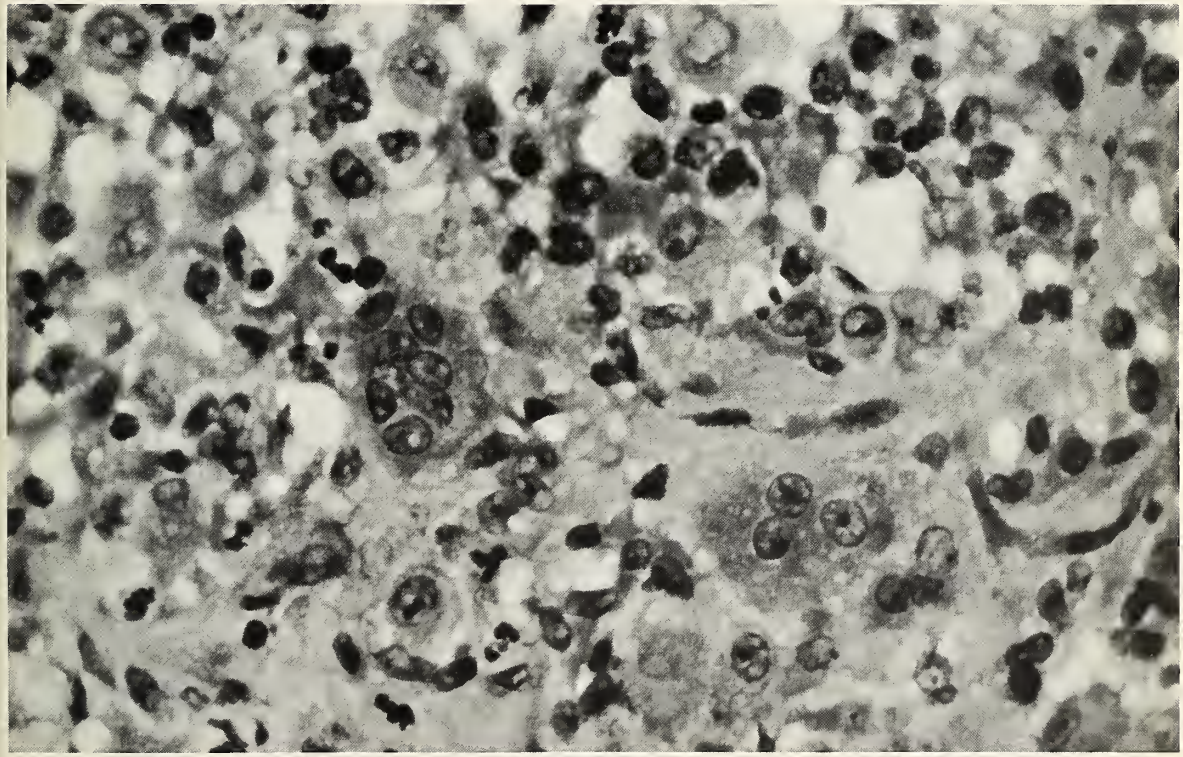

Fig. 355

GIANT CELL REACTION

(Figures 357–359 are from the same case*)

Figure 356. Roentgenogram showing cystic appearance and deformity of a middle phalanx of a 35-year-old woman. From this film, hyperparathyroidism was considered as a diagnostic possibility, but survey of other bones did not support this. Diagnosis of giant cell reaction was made from histologic study of curetted material. (Courtesy of Dr. M. B. Conrad, St. Louis, Mo.) W.U. 57–4978; A. F. I. P. Acc. No. 218757–333.

Figure 357. Roentgenogram illustrating a destructive lesion of a distal phalanx of a 10-year-old girl. The patient had been in good health, except for slight enlargement of the tip of the 5th finger. Amputation of the distal phalanx was performed. W.U. 57–6961; A. F. I. P. Acc. No. 218757–334.

Figure 358. In the histologic section, note abundant multinucleated giant cells, small vascular channels, scattered leukocytes, and the amount of fibrous stroma. The tumor, accordingly, is more fibrous than a giant cell tumor of bone. Hematoxylin and eosin stain. X 98. B.H. 57–1824; A. F. I. P. Acc. No. 218757–335.

Figure 359. This histologic section shows the abundant osteoid formation which serves to differentiate this tumor from giant cell tumor. Hematoxylin and eosin stain. X 225. B.H. 57–1824; A. F. I. P. Acc. No. 218757–336.

---

*Courtesy of Dr. C. R. Phelps, Ottumwa, Iowa.

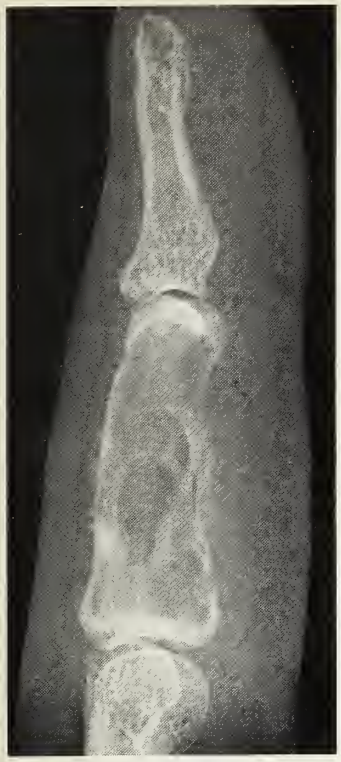

Fig. 356

Fig. 357

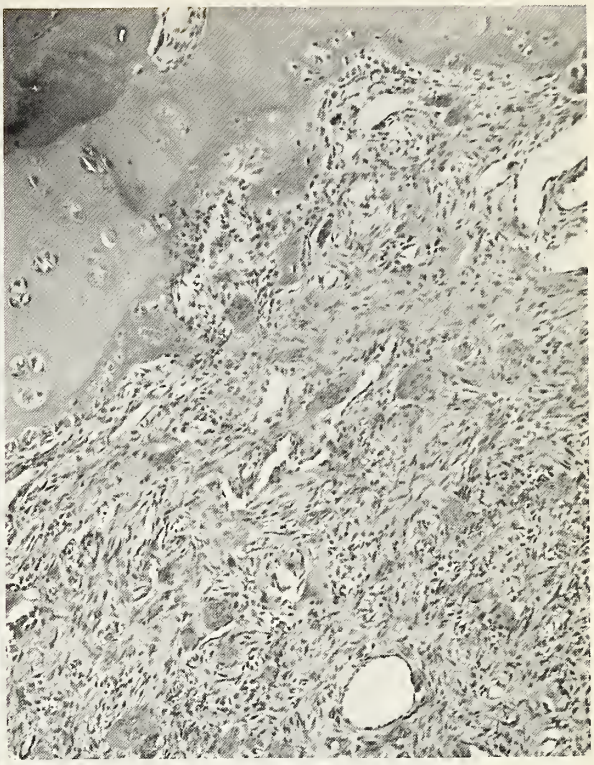

Fig. 358

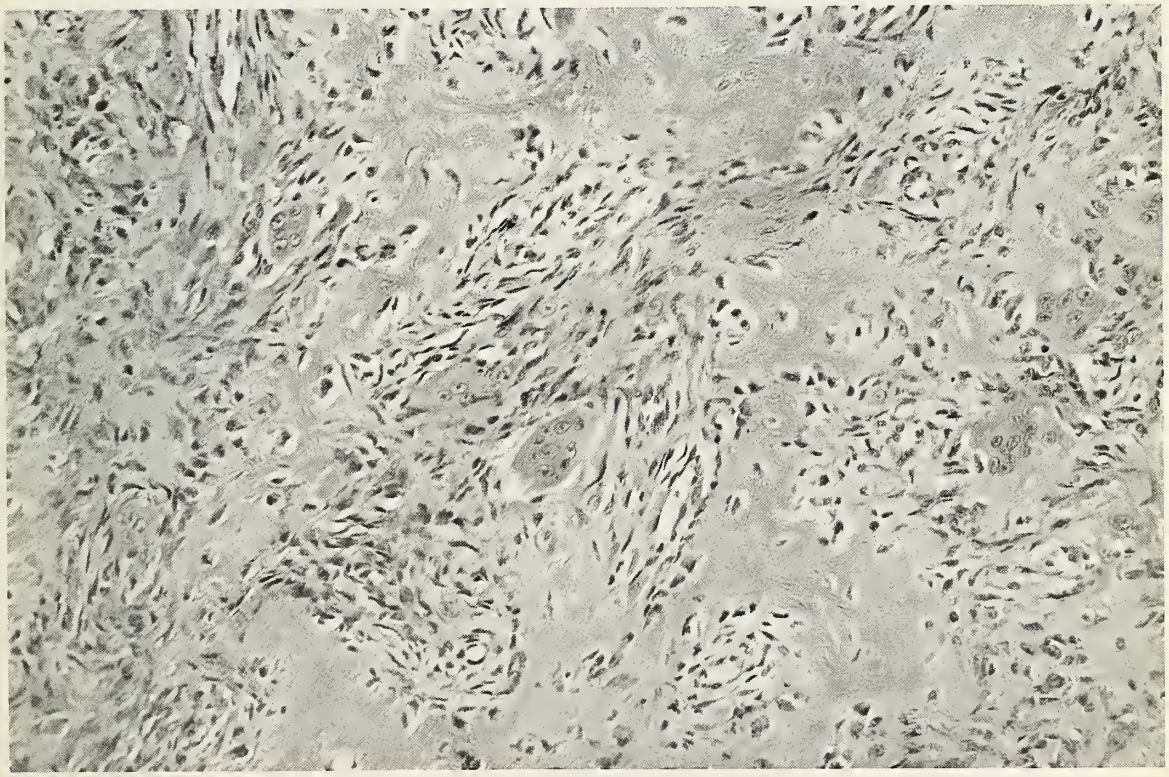

Fig. 359

GIANT CELL TUMOR—TENDON SHEATH ORIGIN

(Figures 361 and 362 are from the same case*)

Figure 360. Roentgenogram exhibiting destruction of the proximal phalanx of a great toe of a 31-year-old man. Amputated specimen histologically showed characteristics of giant cell tumor of the tendon sheath. (This is figure 4 [right] in Fletcher, A. G., Jr., and Horn, R. C., Jr. Giant cell tumors of tendon sheath origin. A consideration of bone involvement and report of two cases with extensive bone destruction. Ann. Surg., 133:374–385, 1951.) A. F. I. P. Acc. No. 218757–370.

Figure 361. Amputation specimen of a 5th toe from a 22-year-old man who had noted swelling of the part for three weeks. Tumor is shown invading the proximal phalanx, crossing the joint space, and invading the distal phalanx. Material obtained by needle biopsy was diagnosed as giant cell tumor. W.U. 58–7680; A. F. I. P. Acc. No. 218757–385.

Figure 362. This cross section of the toe demonstrates almost complete envelopment of the proximal phalanx by tumor. Histologically, this tumor was characteristic of giant cell tumor of the tendon sheath. W.U. 58–7681; A. F. I. P. Acc. No. 218757–386.

---

*Courtesy of Dr. R. F. Schaefer, St. Louis, Mo.

Army - AFIP - Washington, D. C.



Fig. 360

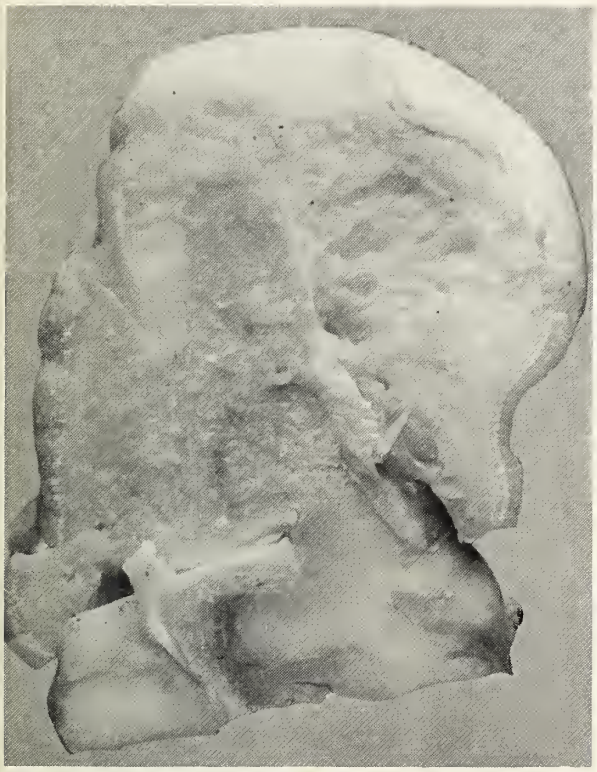

Fig. 361

Fig. 362

PROFESSIONAL NOTES AND FINDINGS

PROFESSIONAL NOTES AND FINDINGS

PROFESSIONAL NOTES AND FINDINGS

PROFESSIONAL NOTES AND FINDINGS

PROFESSIONAL NOTES AND FINDINGS

Library
National Institutes of Health
Bethesda 14, Maryland

DATE DUE

NIH LIB FEB 3 1970			
NIH LIB MAR 19 1973			
MAY 1976			
MAY 3 1976			
APR 21 1982			
GAYLOR			PRINTED IN U.S.A.

LIBRARY
NIH
Amazing Research.
Amazing Help.
http://nihlibrary.nih.gov

10 Center Drive
Bethesda, MD 20892-1150
301-496-1080

NIH LIBRARY
4 0087 7750

BOUND BY HNM

NIH LIBRARY
3 1496 00198 2274